



Assessment of Gastrointestinal Parasites of Chicken Slaughtered in Creek Road Market, Port Harcourt

Elele Kingsley¹ and Adedokun Ambali Amudatu^{2*}

¹Department of Biology, Ignatius Ajuru University of Education, Port Harcourt, Rivers State, Nigeria.

²Department of Medical Laboratory Science, Fountain University, Osogbo, Osun State, Nigeria.

Authors' contributions

This work was carried out in collaboration between both authors. Both authors read and approved the final manuscript.

Article Information

DOI: 10.9734/JAMB/2021/v21i830372

Editor(s):

(1) Dr. Pankaj Kumar, Dolphin (PG) Institute of Biomedical and Natural Sciences, India.

Reviewers:

(1) Kunwar Dhananjay Singh, Acharya Narendra Deva University of Agriculture & Technology, India.

(2) Philip Asumang, Kwame Nkrumah University of Science and Technology, Ghana.

Complete Peer review History: <https://www.sdiarticle4.com/review-history/72293>

Original Research Article

Received 06 June 2021

Accepted 12 August 2021

Published 17 August 2021

ABSTRACT

Aim: The study was conducted to determine the gastrointestinal parasites among slaughtered Chicken at Yam Zone Market, Creek Road, Port Harcourt, Rivers State, Nigeria.

Study Design: Gastrointestinal tracts of slaughtered chicken were collected weekly from a vendor. Each part of the GIT was emptied into separate vessel containing normal saline.

Place and Duration of Study: This study was carried out in a chicken market in Port Harcourt, Nigeria for a period of 4 months (January-April 2020).

Methodology: A total of 100 chickens (comprising of broilers and layers) of which samples were collected from their gastrointestinal tracts were examined using formol-ether concentration methods for the presence of gastrointestinal parasites.

Results: Eighty-four (84) parts of the gastrointestinal tracts accounted for 14.0% found to be infected with parasites. The gastrointestinal protozoan isolated is *Eimeria* spp (52.4%) while helminths species found were, *Ascaridia galli* (47.6%). There were no cestodes and trematodes identified.

Conclusion: Poultry management system needs to be improved with a viable biosecurity control strategy towards healthy production of livestock chickens for human consumption.

*Corresponding author: E-mail: amudatuadedokun@gmail.com;

Keywords: Gastrointestinal parasites; chickens; eimeria spp; ascaridia galli; port harcourt.

1. INTRODUCTION

Poultry are kept in backyards or commercial production systems in most areas of the world. Compared to a number of other livestock species, fewer social and religious taboos are related to the production, marketing and consumption of poultry products [1]. The poultry industry occupies an important position in the provision of animal protein (meat and egg) to man and generally plays a vital role in the national economy as a revenue provider [2]. Livestock sub sector contributions to Gross Domestic Product (GDP) have decreased from 5.61% in 1960 to about 2.64% in 2010 [3]. The contributions of livestock to Agriculture in 1999 and 2010 remain at 2.64% [3]. Nigerian Agricultural sector is identified with the provision of food and nutrition while poultry production is responsible for 19% of the meat supply [4]. The development of the poultry industry has also been described as the fastest means of bridging the protein deficiency gap prevailing in most of the developing countries.

Gastrointestinal parasites which invade the chickens possess morphological and physiological features such as small thread-like cylindrical bodies, hooks and a hard body cuticle which enhance their adaptation to long living and existence in chickens [5]. The concentration of parasite eggs in the chicken's environment is one factor which plays a major role in determining the severity of the infection. Heavy gastrointestinal helminthiasis is characterized by retarded growth, emaciation, decreased egg production, mucoid diarrhea, catarrh, loss of appetite, anemia, weakness, paralysis, and death. These are causes of great economic losses [6,7].

The common GIT parasites that infect poultry include helminths, cestodes, nematodes, and protozoans, with mixed infections being widespread [8]. Helminthes and protozoans are the major intestinal parasites that affect poultry farming. *Ascaridia galli*, *Heterakis gallinarum*, *Capillaria* species and *Raillietina* species are all helminthes. Coccidian is a class of Protozoa that causes a well-known disease as such as *Eimeria tenella*, *E. acervulina*, *E. necatrix*, *E. maxima* and *E. brunetti*. These GIT parasites have morphological and physiological features adapted to live longer in their hosts [9]. *Ascaridia galli* has been incriminated as the most common and most important parasite of poultry [10,8]. The cestodes of significant importance are of the two genera *Raillietina* and *Hymenolepsis* [11,8].

Risk factors that contribute to the spread of these parasites into the layer chickens include poultry transports, neighborhood infection, unhygienic practices of farms, and the introduction of infected foreign birds [12].

This study is aimed at assessing the presence of gastrointestinal parasites of commercial layers and broilers in relation to their public health importance.

2. MATERIALS AND METHODS

2.1 Study Area

The study was conducted at Chicken Market at Yam Zone, Creek Road in Port Harcourt city, Rivers State with geographical location of latitude (4°45'30.9312" N) and longitude (7°1'39.828" E). This yam zone is a popular market and the hub of different food businesses in Port Harcourt city (Fig 1).

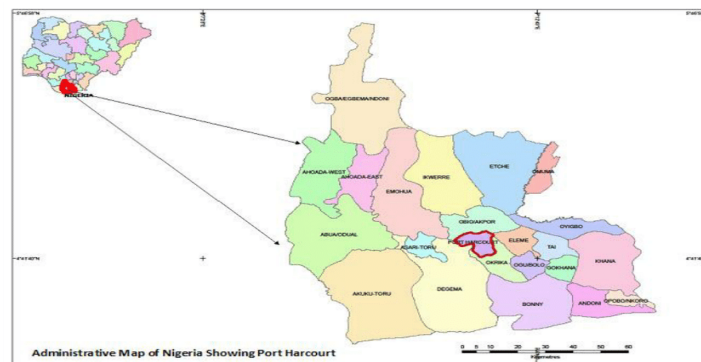


Fig 1. Sampling location of poultry birds

2.2 Study Design

This study was conducted for a period of four months (January - March 2020) to estimate the prevalence of gastrointestinal parasites in poultry. One livestock vendor was used in the Yam zone markets were visited weekly for sample collection.

2.3 Sample Collection

One hundred (100) gastrointestinal tracts of comprising 50 broilers and 50 layer birds were randomly collected from poultry dressing units in Chicken market, Yam Zone. The gastrointestinal tracts were dissected into sections containing respective organs: esophagus, crop, gizzard, small intestine, caecum and rectum and kept separately in Petri dishes containing physiological saline.

2.4 Recovery and Identification of Gastrointestinal Parasites

The alimentary canal of each chicken was opened separated into various parts namely: esophagus, crop, gizzard, small intestines, caecum and cloaca. Each part was opened and contents emptied into separate containers containing physiological saline [5] and Scrapings from the intestinal mucosa from the upper, middle and lower linings of the intestine and caecum were concentrated using the formol-ether concentration technique [13].

2.5 Data Analysis

The data derived from these procedures was entered in Microsoft Excel 2016. Descriptive and Chi square (χ^2) and T- test analysis was carried out using SPSS; version 22.0, Chicago, USA. To determine its significance, P value was set at 0.05 at 95% confidence interval.

3. RESULTS AND DISCUSSION

A total of 100 birds from chicken market were randomly collected for investigation of intestinal parasites. The slaughtered birds comprise of 50 broilers and 50 layers from Yam zone chicken market, Creek Road, Port Harcourt. The alimentary canals analyzed were esophagus, crop, gizzard, intestine, caeca and cloaca.

The gastrointestinal tract of broilers examined was 51(60.7%) infested with intestinal parasites while that of layers accounted for 33(39.3%)

(Table 1). The prevalence of intestinal parasites was found to be statistically significant ($p < 0.05$).

In comparison of broilers and layers affected by *Ascaridia galli* using T test, p-value was 0.305 which was not significant while broilers and layers affected by *Eimeria* spp was found to be significant with p-value of 0.002.

Fourteen percent (14%) of the prevalence for intestinal parasites were attained out of the 600 gastrointestinal tract examined. The caeca having the highest prevalence of 30(39.3%) and least prevalence was observed in the small intestine 8(9.5%) (Fig 2).

The gastrointestinal parasites identified were *Eimeria* spp and *Ascaridia galli*. *Eimeria* spp had prevalence of 44(52.4%) while *Ascaridia galli* had prevalence of 40(47.6%). Cestodes and trematodes were not identified (Fig 3).

Parasitic diseases are problems wherever poultry are raised, whether in large commercial operations or in small backyard flocks, and economic losses caused by parasites on poultry can be significant [6]. The survey of gastrointestinal parasites identified in this study had a prevalence of 14% of total gastrointestinal tract examined. All the broilers were found to contain GI parasites. The GI parasites implicated were *Eimeria* spp. (52.4%) and *Ascaridia galli* (47.6%). Cestodes and trematodes were not identified.

The prevalence of GI infection was found to be statistically significant ($p < 0.05$). These findings are in agreement with study by Wokem and Obiyor [14] in Port Harcourt where layers from selected areas were examined, where faecal samples were infected with *Ascaridia galli* 39(30%), *Eimeria species* 54(41.5%), High prevalences were observed by [15] and [16] in India and Nigeria where they had 81.03% and 77.0% were positive for *Eimeria* spp. In Nigeria, overall prevalence of coccidial infection of 40.1% was observed by Agishi, et al. [17] in Markudi. In their investigation on intestinal parasites of Chicken.

On the contrary, in Phillippines, Ilorin and Maiduguri, Nigeria reports of a lower prevalence of 43.2%, 32.83% and 31.8% of *Eimeria* infection in poultry were recorded [18,19,20]. Also, very lower prevalence of 3.9% and 7.7% of *Eimeria* spp has be reported by [21,22] among domestic fowl.

Table 1. Prevalence of gastrointestinal parasites along the chicken gastrointestinal tract

Intestinal parasites	Location of parasites in GI tract	No. of infested GIT of Broilers (%)	No. of infested GIT of Layers (%)	Chi-square (X ²)	P-value
Ascaridia galli	Esophagus	5(22.0)	2(11.7)	30.179	0.000
	Crop	2(8.6)	1(6.0)		
	Gizzard	4(17.4)	1(6.0)		
	Small intestine	2(8.6)	2(11.7)		
	Caecum	7(30.4)	9(52.9)		
	Cloaca	3(13.0)	2(11.7)		
	Sub-Total	23(45.1)	17(51.5)		
Eimeria spp	Esophagus	2(7.1)	2(12.5)	12.310	0.031
	Crop	2(7.1)	4(25.0)		
	Gizzard	5(17.8)	3(18.7)		
	Small intestine	3(10.7)	1(6.3)		
	Caecum	12(43.0)	5(31.2)		
	Cloaca	4(14.3)	1(6.3)		
	Sub-Total	28(54.9)	16(48.5)		
Total		51(60.7)	33(39.3)		

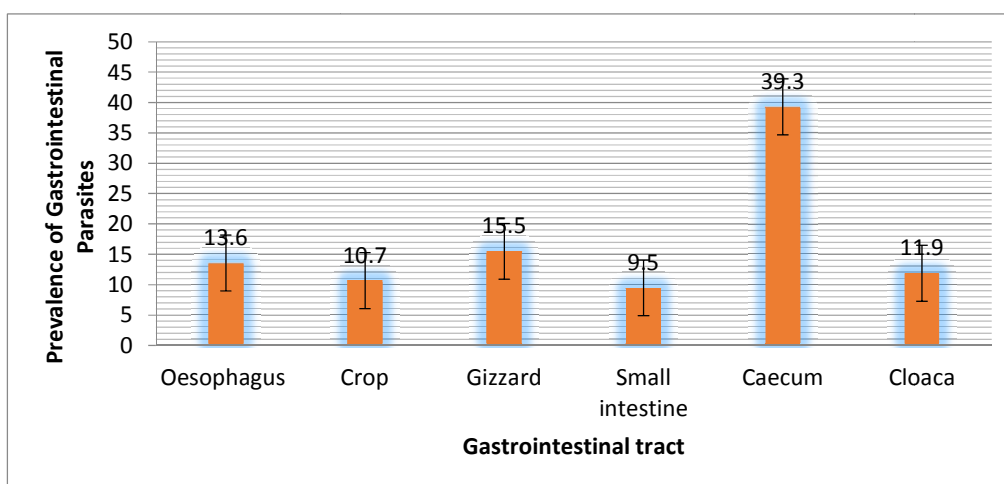


Fig 2. Prevalence of gastrointestinal parasites along the gastrointestinal tract

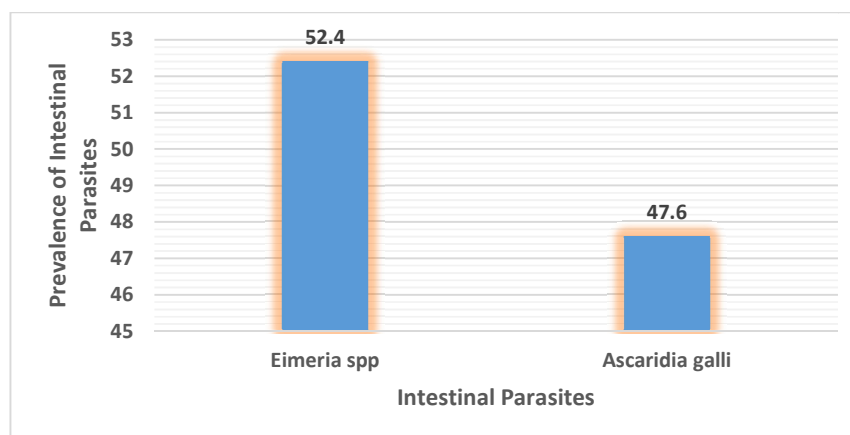


Fig 3. Intestinal parasitic prevalence among the chickens

Coccidial infection due to *Eimeria* spp is suggestive to be endemic in poultry in Nigeria [23,24]. This may be attributed to the fact that *Eimeria* species are ubiquitous anywhere poultry are reared [19].

Enteric diseases are an important concern to the poultry industry because of production losses, increased mortality, reduced welfare of birds and increased risk of contamination of poultry products for human consumption. Avian coccidiosis is an enteric parasitic disease caused by multiple species of the protozoan parasite of the genus *Eimeria*. It is one of the most common and economically most important diseases of poultry worldwide [25,26].

Moreover, poor management practices may be responsible for high parasitic prevalence perceived in study areas elsewhere in the faecal samples in the poultry house hence coccidial oocyst were always present and spread very easily especially when left humid with caked litters as stated by [27].

Ascaris galli was the only gastrointestinal helminth recorded with 47.6% prevalence rate in this study. This agrees with previous studies by [28,29,30]. In Gwagwalada, Abuja, prevalence as high as 51.60% was observed by [31]. Lower prevalence of 30.15%, 22.3% and 22.4% was recorded *A. galli* by [19,32,33]. On the contrary, *A. galli* had the highest prevalence rate in both local and exotic breed among the helminths though with very low prevalence 6.0% as reported by Ola-Fadunsin et al. [34] in March. Khan et al. 2016 reported that *A. galli* causes larger chances of death in smaller birds as they belong to the group of Nematodes which constitutes an important class of helminths parasites of poultry both in a number of species and in the level of damage, they caused [34]. The infection rates of *A. galli* depend on many factors namely, rainfall pattern, soil type, locality and the types of food given to the chickens which vary from place to place [36]. This explains the differences in variation of the prevalence observed by several authors. High infection rate may be due to the poor handling and control efforts in either the animal or in the immediate environment where infection or re-infection may come from [37].

On the prevalence of gastrointestinal parasitic infestation on the birds, broilers had more prevalent than the layers with 60.7% where *Eimeria* spp were implicated for 54.8% of

infection. The prevalence of *Eimeria* spp among the exotic breeds were found to be statistically significant ($p<0.05$). The high prevalence rate of *Eimeria* spp recorded in broilers may be associated with the fact that this chicken type is raised intensively and on a deep litter with a high level of water spillage in the litter in most cases [19].

4. CONCLUSION

Eimeria spp and *A. galli* are the most common identified gastrointestinal parasitic infections affecting poultry birds in this study. Proper biosecurity intervention methods need to be provided for the reduction of intestinal parasites in poultry farming.

COMPETING INTERESTS

Authors have declared that no competing interests exist.

REFERENCES

1. Permin A, Hansen JW. Epidemiology, Diagnosis and Control of Poultry Parasites. FAO Animal Production and Health Division. Food and Agriculture Organization of the United Nations Rome. 1998;4(4).
2. Obiora FC. A guide to poultry Production in the Tropics, 1st Edn. Acena Publishers, Enugu; 1992.
3. Central Bank of Nigeria. Central Bank of Nigeria. Annual Report Statement of Account Statistical Bulletin; 2010.
4. Sheep and Goats Transformation Action Plan (SAGTAP). Implementation Plan for Livestock Transformation Action Plan. Federal Ministry of Agriculture and Rural Development, Abuja, Nigeria. 2012;20.
5. Abdullah SM, Barman A, Ali, MY, Islam MS, and U. K. Mohanta, Morphological identification and prevalence of gastrointestinal helminths in backyard chicken from selected areas of Bangladesh. Res Agric Livest Fish. 2021;8(1):145-155.
6. Fatihu MY, Ogbogu VC, Njoku CO, Saror DI. Comparative studies of gastrointestinal helminths of poultry in Zaria, Nigeria. Rev Elev Med Vet Pays Trop. 1991;44(2):175-7.
7. Vijayakumaran Nair K, Nadakal AM. Haematological changes in domestic fowl experimentally infected with the cestode

- Raillietina tetragona* (Molin, 1858). Vet Parasitol. 1981;8(1):49-58.
8. Luka SA, Ndams IS. Short communication report: Gastrointestinal parasites of domestic chicken *Gallus-gallus domesticus* linnaeus 1758 in Samaru, Zaria Nigeria. Science World J. 2007;2(1):27-9.
 9. Belete A., Addis M, Ayele, M. Review on major gastrointestinal parasites that affect chickens. J Biol Agric Healthcare. 2016;6(11):11-21.
 10. Hodasi JKM. Comparative studies on the helminth fauna of Native and introduced domestic fowls in Ghana. J Helminthol. 1969;43:35-52.
 11. Oniye SJ, Audu PA, Adebote DA, Kwaghe BB, Ajanusi OJ, Nfor MB. Survey of Helminth Parasites of Laughing Dove (*Streptopelia senegalensis*) in Zaria, Nigeria. African J Nat Sci. 2001;4:65-6.
 12. Thomas M, Bouma A, Ekker H, Fonken A, Stegeman J, Nielen M. Risk factors for the introduction of high pathogenicity avian influenza virus into poultry farms during the epidemic in the Netherlands in 2003. Prev Vet Med. 2005;69(1-2):1-11.
 13. Cheesbrough M. Parasitological tests: District laboratory practice for tropical countries, Part 1, 2nd Edition. 2009; 191-200.
 14. Wokem GN, Obiyor E. Assessment of Intestinal Parasites of Commercial Layers in Selected Local Government Areas of Rivers State, Nigeria and Their Public Health Implications. Curr Trends Biomedical Eng & Biosci. 2018;11(5): 555822. DOI: 10.19080/CTBEB.2018.11.555822
 15. Kumar S, Garg R, Ram H, Maurya PS, Banerjee PS. Gastrointestinal parasitic infections in chickens of upper Gangetic plains of India with special reference to poultry coccidiosis. J Parasit Dis. 2013;39(1):22-6.
 16. Ojmelukwe AE, Agu GO, Abah AE. Molecular identification of poultry *Eimeria* species at live bird markets in River State, Nigeria. IOSR J Agric Vet Sci. 2018;11(2):45-51.
 17. Agishi GI, Luga I, Rabo JS. Prevalence of coccidiosis and *Eimeria* species in layers and broilers at slaughter houses in Makurdi, Benue state. Int J Engr Sci. 2016;5(2): 08-11.
 18. Ybañez RHD, Resuelo KJG, Kintanar APM, Ybañez AP. Detection of gastrointestinal parasites in small-scale poultry layer farms in Leyte, Philippines, Vet World. 2018;11(11):1587-91.
 19. Ola-Fadunsin SD, Ganiyu IA, Rabiun M, Hussain K, Sanda IM, Musa SA, Uwabujo PI, Furo NA. Gastrointestinal parasites of different avian species in Ilorin, North Central Nigeria. J Adv Vet Anim Res. 2019;6(1):108-16.
 20. Lawal JR, Jajere SM, Ibrahim UI, Geidam YA, Gulani IA, Musa G, Ibekwe BU. Prevalence of coccidiosis among village and exotic breed of chickens in Maiduguri, Nigeria. Vet World, 2016;9(6):653-9.
 21. Ohari CC, Okwum C. Helminth parasites of domestic fowls in Ikwuano, Abia state, Nigeria. J Nat Sci Res. 2013;3(11):1-6.
 22. Afolabi OJ, Simon-Oke IA, Olankanmi AO. Intestinal parasites of domestic chicken (*Gallus gallus domesticus*) in Akure, Nigeria. J Biomed Health. 2016; 1(4):1-4.
 23. Dauda J, Lawal JR, Bello AM, Mustapha M, Ndahi JJ, Biu AA. Survey on prevalence of gastrointestinal nematodes and associated risk factors in domestic turkeys (*Meleagris gallopavo*) slaughtered in poultry markets in Bukuru – Jos, Plateau State, Nigeria. Int J Innov Agric Biol Res. 2016;4(4):27-36.
 24. Mijinyawa A, Junaid HI. Gastrointestinal helminth parasites of domestic pigeons *Columba livia domestica* in Funtua Local Government Area, Katsina State, Nigeria. J Nat Sci Res. 2017;7(23):62-5.
 25. Olarenwaju CA, Agbor RY. prevalence of coccidiosis among poultry birds slaughtered at Gwagwalada main market, Abuja, FCT, Nigeria. Int J Engr Sci. 2014;3(1):41-5.
 26. Shirley MW, Smith AL, Tomley FM. The biology of avian *Eimeria* with an emphasis on their control by vaccination. Adv Parasitol. 2005;60:285-330.
 27. Bachaya HA, Raza MA, Khan MN, Iqbal Z, Abbas RZ, Murtaza S, Badar N. Predominance and detection of different *Eimeria* species causing coccidiosis in layer chickens. J Anim Plant Sci. 2012;22(3):597-600.
 28. Agbolade OM, Arosoye AS, Akajiugo EC, Akinyemi HA, Owolowo AM, Ariba O, Jonathan KA. Gastrointestinal parasites of domestic fowls from Ijebu North, Southwestern Nigeria. Basic Res J Agric Sci Rev. 2014;3(7):60-64.
 29. Shukla S. and Mishra P. 2013. Gastrointestinal helminthes parasites of

- local chicken samples from tribal areas of Madhya Pradesh. *Int J Life Sci.* 2013;1(4):284-7.
30. Katoch R, Yadav A, Godara R, Khajuria JK, Borkataki S, Sodhi SS. Prevalence and impact of gastrointestinal helminthes on body weight gain in backyard chickens in subtropical and humid zone of Jammu, India. *J Parasit Dis.* 2012;36(1):49-52.
31. Matur BM, Dawam NN, Malann YD. Gastrointestinal Helminth Parasites of Local and Exotic Chickens Slaughtered in Gwagwalada, Abuja (FCT), Nigeria. *N Y Sci J.* 2010;3(5).
32. Idika IK, Obi CF, Ezeh IO, Iheagwam CN, Njoku IN, Nwosu CO. Gastrointestinal helminth parasites of local chickens from selected communities in Nsukka region of south eastern Nigeria. *J Parasit Dis.* 2016;40(4):1376-1380. DOI 10.1007/s12639-015-0694-9.
33. Negbenebor HE, Ali M. Prevalence of Gastro-Intestinal Parasites of Local Chickens (*Gallus gallus domestica*) in Kano, Nigeria. *Ann Microbiol Infect Dis.* 2018;1(4):45-49. ISSN 2637-5346.
34. Ola-Fadunsin SD, Uwabujo PI, Sanda IM, Ganiyu IA, Hussain K, Rabiu M, Elelu N, Alayande MO. Gastrointestinal helminths of intensively managed poultry in Kwara Central, Kwara State, Nigeria: Its diversity, prevalence, intensity, and risk factors. *Vet World.* 2019;12(3):389-96.
35. Khan L, Qureshi AW, Shah MN, Feroz K, Mansoor A, Draz O, Fahad S. Prevalence and Identification of Nematodes in Chickens from District Charsadda, KPK, Pakistan. *J Biodivers Environ Sci.* 2016;9(1):274-82.
36. Rahman AW, Salim H, Ghause MS. Helminthic parasites of scavenging chickens (*Gallus domesticus*) from villages in Penang Island, Malaysia. *Trop Life Sci Res.* 2009;20(1):1-6.
37. Adang KL, Asher R, Abba R. Gastro-intestinal helminths of domestic chickens *Gallus gallus domestica* and ducks *Anas platyrhynchos* slaughtered at Gombe main market, Gombe State, Nigeria. *Asian J Poult Sci.* 2014;8:32-40.

© 2021 Elele and Adedokun; This is an Open Access article distributed under the terms of the Creative Commons Attribution License (<http://creativecommons.org/licenses/by/4.0>), which permits unrestricted use, distribution, and reproduction in any medium, provided the original work is properly cited.

Peer-review history:

The peer review history for this paper can be accessed here:
<https://www.sdiarticle4.com/review-history/72293>