

Correlation of Multiparametric MRI-estimated Vesical Imaging Reporting and Data System (VI-RADS) Score with Muscle Invasion and Tumor Grade on TURBT in Patients with Urothelial Bladder Cancer: A Prospective Cross-sectional Study

Siddharth Sathaye ^{a*}, Sasanka Kumar Barua ^a, Puskal Kumar Bagchi ^a,
Mandeep Phukan ^a, Debanga Sarma ^a, Pranjit Phukan ^a
and Sachinkumar Patel ^a

^a Department of Urology, Second Floor, Super Speciality Block-1, Gauhati Medical College and Hospital, Bhangagarh, Guwahati, Assam – 781032, India.

Authors' contributions

This work was carried out in collaboration among all authors. All authors read and approved the final manuscript.

Article Information

Open Peer Review History:

This journal follows the Advanced Open Peer Review policy. Identity of the Reviewers, Editor(s) and additional Reviewers, peer review comments, different versions of the manuscript, comments of the editors, etc are available here: <https://www.sdiarticle5.com/review-history/89798>

Original Research Article

Received 17 May 2022
Accepted 25 July 2022
Published 28 July 2022

ABSTRACT

Introduction and Objective: Differentiation between non-muscle-invasive bladder cancer (NMIBC) and muscle-invasive BC (MIBC) is one of the main challenges in BC management. Tumor grade is another parameter guiding treatment. Transurethral resection of bladder tumor (TURBT) bears an inherent risk of understaging, especially if the sample does not contain detrusor muscle. Hence, an adjunctive modality for local staging such as CT or MRI is desirable. Multi-parametric MRI (mpMRI), and the Vesical Imaging Reporting and Data System (VI-RADS) score derived therefrom is one such tool for BC local staging. The objective of the present study was to prospectively evaluate the accuracy the VI-RADS score in assessing muscle-invasiveness and tumor grade on TURBT, by using histopathological examination as the reference standard.

Methods: 50 patients with bladder tumor were included in this study conducted at the Department of Urology, Gauhati Medical College and Hospital, Guwahati, Assam (India) over 13 months from November 2020 to November 2021. All patients underwent a mpMRI of the urinary bladder prior to

TURBT and a five-point VI-RADS score was obtained. The VI-RADS score was correlated with the histopathological muscle invasion and tumor grade obtained on TURBT.

Results: There was a positive correlation between the VI-RADS score and the pathological results with respect to both muscle invasion ($r = 0.401$, $p < 0.05$) and tumor grade ($r = 0.386$, $p < 0.05$). For muscle-invasion, the AUC of the VI-RADS score was 0.722, and for tumor grade, the AUC was 0.709. For a VI-RADS score of ≥ 3 , the sensitivity and specificity to predict muscle-invasiveness were 84% and 44% respectively, and for a VI-RADS score of ≥ 4 , the sensitivity and specificity to predict muscle-invasiveness were 68% and 72% respectively.

Conclusion: The reliability of VI-RADS for BC local staging and discrimination between NMIBC and MIBC has been widely reported. However, the lack of accuracy of correlation in the present study and the lack of identification of important prognostic markers for BC on MRI, such as carcinoma in-situ, lymphovascular invasion and variant histology relegates the VI-RADS score to being only an adjunct in the workup of patients with BC.

Keywords: Mpmri; turbt; transurethral resection of bladder tumor; muscle-invasive bladder cancer; vi-rads; bladder cancer.

1. INTRODUCTION

“Bladder Cancer (BC) is a common urological malignancy with a male predominance, with urothelial cancer (UC) being the most common histological variant. Its high prevalence and public health burden on account of significant morbidity, costs and mortality makes it a serious health problem. Differentiation between non-muscle-invasive BC (NMIBC) and muscle-invasive BC (MIBC) is one of the main challenges in BC management, because the management of both is different. Besides muscle-invasiveness, tumor grade is another parameter guiding treatment” [1]. Most (90%) BCs are urothelial carcinomas [2]. “A combination of clinical, histological and imaging parameters is currently used to stage BC, with transurethral resection of bladder tumor (TURBT) being the gold standard for local staging. The main applications of cross-sectional imaging such as CT and MRI are assessment of lymph nodal and distant metastases” [3]. “There are three practical goals of staging TURBT: (I) to confirm histologic type and grade, (II) to determine the presence, depth, and type of tumor invasion, and (III) to remove all visible and microscopic superficial and invasive tumors” [4]. “TURBT bears an inherent risk of understaging, especially if the sample does not contain detrusor muscle, resulting in inadequate and often delayed therapy, negatively impacting survival” [5]. Hence, “an adjunctive modality for local staging such as CT or MRI is desirable. Multi-parametric MRI, due to its safety in terms of radiation exposure, and accuracy in terms of spatial resolution and characterization of the layers of the bladder as well as locoregional anatomic structures, is one such tool for BC local

staging. However, there was a lack of standardization. A five-point scoring system called VI-RADS (Vesical Imaging Reporting and Data System) was recently presented to standardize the local staging of bladder tumor using mpMRI parameters - T2 weighted (T2WI), diffusion weighted (DWI) and dynamic contrast enhanced (DCE) image sequences” [6]. “Many prospective as well as retrospective studies have validated the score as a measure of muscle-invasiveness on TURBT. However, to the best of our knowledge, only one study [7] has assessed its usefulness if differentiating low-grade from high-grade bladder UC”.

The objective of the present study was to prospectively evaluate the accuracy of mpMRI-derived VI-RADS score in assessing muscle-invasiveness and tumor grade on TURBT, by using histopathological examination as the reference standard.

2. MATERIALS AND METHODS

2.1 Study Design

The study was designed as a prospective cross-sectional observational study.

2.1.1 Study population

The study was conducted at the Department of Urology and Renal Transplantation, Gauhati Medical College and Hospital, Guwahati, Assam (India) over 13 months from November 2020 to November 2021. A total of 50 patients were enrolled in the study (n).

2.1.2 Inclusion and Exclusion Criteria

Inclusion and exclusion criteria are outlined in Table 1.

2.2 Methods

“Patients diagnosed with urinary bladder tumor on cystoscopy/ imaging were offered mpMRI before TURBT. No cystoscopy was performed in any patient within three days before examination. An ultrasound examination was done prior to the MRI to ensure a bladder capacity of at least 300 ml. 3 Tesla MRI (Siemens 3T) was used for the examination. A multichannel phased array external surface coil was used to collect images with a high spatial resolution and signal-to-noise ratio. Following were included in the field of view: bladder, proximal urethra, and pelvic lymph nodes; prostate (male); uterus, ovaries, fallopian tubes, and vagina (female). The key image sequences, T2WI, DWI and DCE, were finally obtained in the axial, coronal plane and sagittal planes, respectively. The bladder tumors were scored on a five-point scale according to the scoring criteria” [6]. For multifocal tumors, the tumor with the highest VI-RADS score was considered. All imaging scores were completed independently by radiologists with the same qualification at our institution; any disagreement was resolved by consensus.

The patients underwent TURBT within 2 weeks of the MRI scan under spinal or general anesthesia, depending upon patient characteristics. Monopolar current was used for the procedure and glycine was used as the irrigant solution. All visible tumor was resected up to deep muscle. Suspicious areas were biopsied.

The postoperative specimens were examined pathologically by pathologists with the same qualification at our institution. All specimens from TURBT contained the muscularis of the bladder, and muscle infiltration and tumor grade were assessed pathologically.

2.3 Statistical Analysis

The data collected was tabulated and analysed by Statistical Package for Social Sciences (SPSS) software version 26 for Windows as well as Microsoft Excel 2019 with inbuilt statistical analysis tool. Receiver operating curve (ROC) was plotted and area under curve (AUC) was calculated for both muscle-invasiveness and tumor grade. Sensitivity, specificity, positive predictive value (PPV), and negative predictive value (NPV) of the VI-RADS score to predict muscle invasiveness were measured using VI-RADS cut-offs of 3 and 4. A p-value of < 0.05 was considered statistically significant.

3. RESULTS

A total of 86 patients presented to the Department of Urology with urinary bladder tumor in the said duration. 15 patients were excluded from the study because of raised serum creatinine. Six patients could not undergo MRI on account of MRI incompatibility (three had prosthetic heart valves, one had claustrophobia, two had metallic implants for femur fracture). Biopsies of 14 patients did not identify any muscle in them. Biopsy of one patient showed adenocarcinoma. Pre-operative MRI of this patient had shown VI-RADS 4 disease (Fig. 1).

Table 1. Inclusion and exclusion criteria

Inclusion criteria	Exclusion criteria
Patients that attended Urology OPD as well as the casualty with hematuria, which subsequently got diagnosed as bladder tumor on cystoscopy	Patients with compromised renal function Patients with claustrophobia
Patients with USG/ CT scan revealing bladder tumor, which got confirmed on cystoscopy	Patients who had undergone TURBT or any other bladder surgery within the last 3 months Patients with metallic implants
Patients who have received no treatment or only diagnostic TURBT > 3 months earlier	Patients with pacemakers, MR-incompatible prosthetic heart valves MRI contrast allergy Patients with non-urothelial bladder tumors Patients whose TURBT specimens did not have muscle in them

CT = computed tomography, MRI = magnetic resonance imaging, OPD = outdoor patient department, TURBT = transurethral resection of bladder tumor, USG = ultrasonography

Hence, 50 patients were finally enrolled in the study. Of these, 41 (82%) were male and nine (18%) were female. The mean age was 58.34 ± 10.74 years. 47 of the 50 patients (96%) presented with hematuria as the presenting complaint. Two (4%) presented with only irritative voiding symptoms without a history of hematuria. One patient was asymptomatic and was incidentally diagnosed on routine abdominal ultrasound. 26 (52%) patients presented with clot retention that required cystoscopic clot evacuation after admission. This bears evidence for the tendency to late presentation among patients from rural Assam. Two patients had metastatic disease at presentation. Both had pulmonary metastases. 62% patients had a solitary tumor while 24% had > 3 tumors. Mean tumor size was 3.73 ± 2.11 cm. 54% of the tumors were > 3 cm. It is reiterated here that in the case of multiple tumors, the tumor with the highest VI-RADS score was considered. In the TURBT histopathology, 25 (50%) patients had non-muscle-invasive disease, and 25 (50%) had muscle-invasive disease. 23 (46%) patients had low-grade tumor, while 27 (54%) patients had high-grade tumor. 5 patients were VI-RADS 1, and 10 patients were VI-RADS 2. 11 had VI-RADS 3 disease while 15 and 9 patients had VI-RADS 4 and VI-RADS 5 disease respectively.

The mean VI-RADS score of all patients was 3.26 ± 1.26 . The mean VI-RADS scores of the non-muscle-invasive and muscle-invasive groups were 2.76 ± 1.3 and 3.76 ± 1.012 respectively ($t = -3.035$, $p < 0.05$). For low-grade tumors the mean VI-RADS score was 2.74 ± 1.25 , and it was 3.7 ± 1.1 for high-grade tumors ($t = -2.898$, $p < 0.05$). Both the differences were statistically significant. There was a positive correlation between the VI-RADS score and the pathological results with respect to both muscle invasion ($r = 0.401$, $p < 0.05$) and tumor grade ($r = 0.386$, $p < 0.05$), that is, higher the VI-RADS score, higher the chances of muscle-invasive as well as high-grade tumor. For muscle-invasiveness, the AUC of the VI-RADS score was 0.722 (95% CI 0.579, 0.865) (Fig. 2), and for tumor grade, the AUC was 0.709 (95% CI 0.567, 0.852) (Fig. 3). The optimal critical value of VI-RADS for predicting muscle-invasive tumors was 3.5, while it was 2.5 for predicting high-grade tumor. For a VI-RADS score of ≥ 3 , the sensitivity and specificity to predict muscle-invasiveness were 84% and 44% respectively, with PPV and NPV of 60% and 70.33% respectively. For a VI-RADS score of ≥ 4 , the sensitivity and specificity to predict muscle-invasiveness were 68% and 72% respectively. The PPV and NPV for this cut-off were 70.83% and 69.23% respectively.

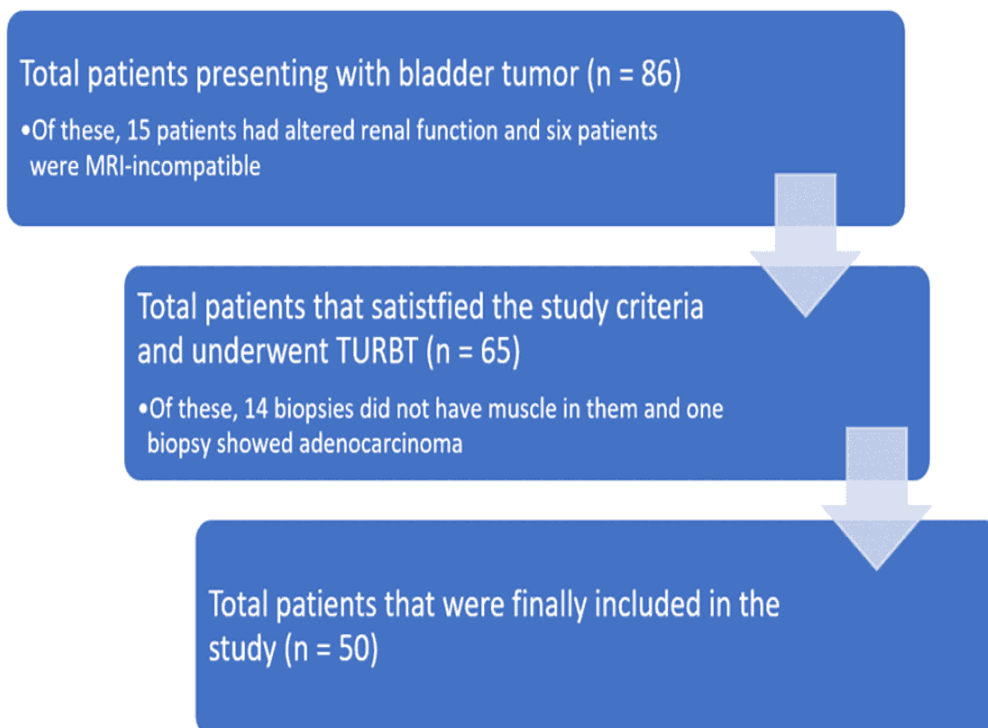


Fig. 1. Patient selection
TURBT = transurethral resection of bladder tumor

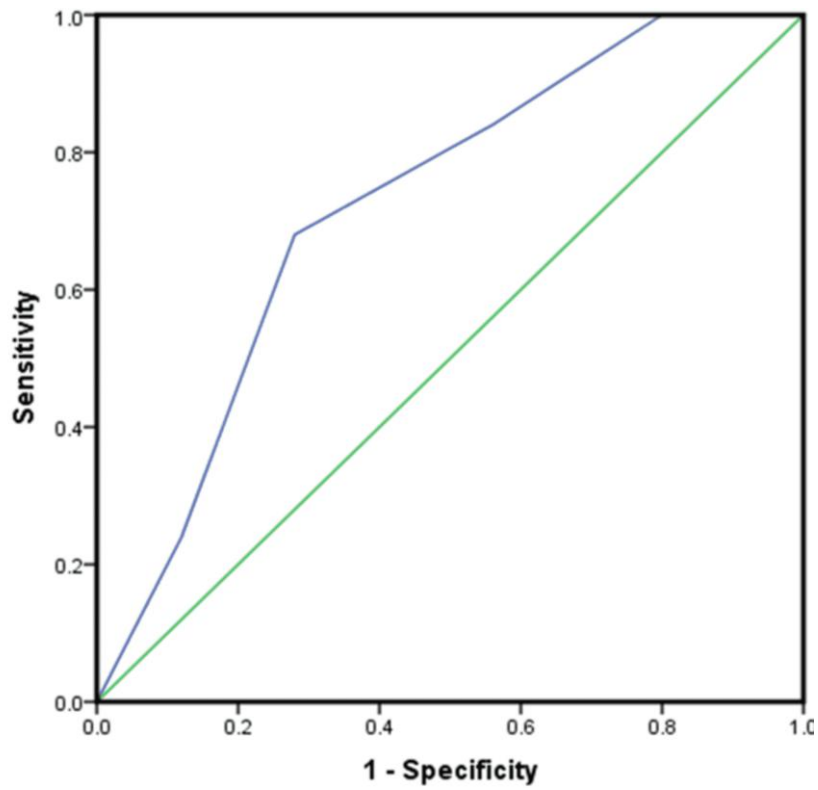


Fig. 2. ROC curve of the VI-RADS score for muscle-invasiveness
Diagonal segments are produced by ties

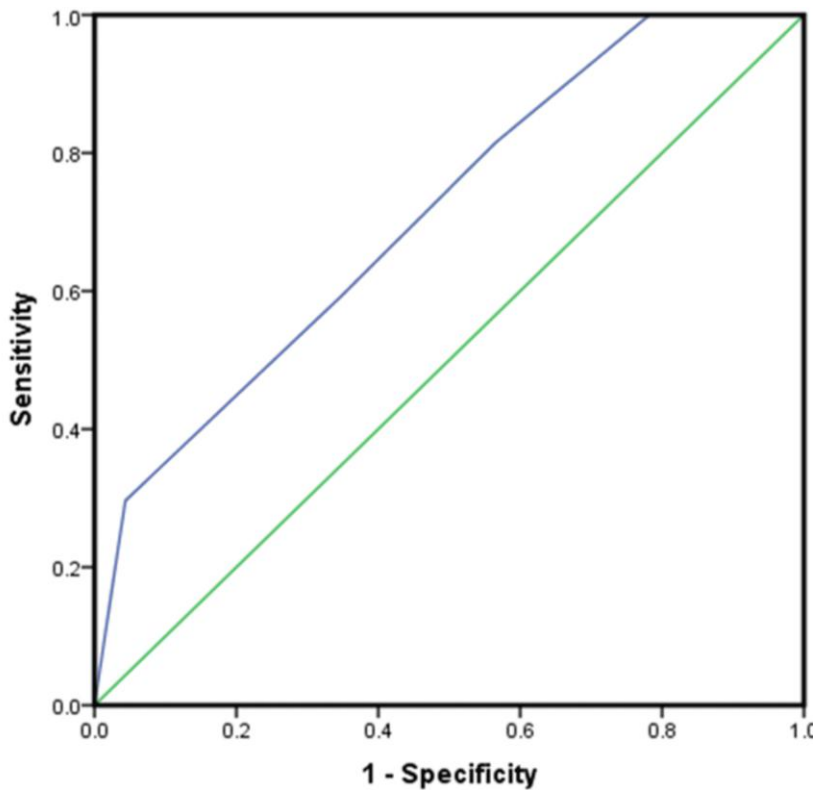


Fig. 3. ROC curve of the VI-RADS score for tumor grade
Diagonal segments are produced by ties

4. DISCUSSION

“Urinary bladder cancer is a serious health issue because of its high prevalence and significant morbidity, costs and mortality” [8]. “Clinical management differs between low- and high-grade non-muscle-invasive and muscle-invasive bladder cancers. Hence, precise clinical staging is of paramount importance in the management of patients with bladder cancer. It helps to devise the most appropriate management plan, thereby improving prognosis” [9,10]. It is, however, difficult to precisely ascertain the clinical stage, often resulting in overtreatment or under treatment.

While pathological confirmation remains the gold standard for bladder cancer diagnosis and staging [11], the accuracy of pathological results needs to be considered. TURBT bears and inherent diagnostic inaccuracy, mostly due to absence of muscle in the specimen, resulting in under-staging [12].

“MRI has shown promising results for the accurate clinical staging of bladder tumors, especially mpMRI, using T2WI, DWI and DCE protocols. However, there was a lack of a standardized reporting system of the MRI report. Hence, following the wide use of Prostate Imaging-Reporting and Data System (PI-RADS) and Breast Imaging-Reporting and Data System (BI-RADS) for prostate cancer and breast cancer respectively, a mpMRI-based VI-RADS scoring system was formulated to locally stage bladder cancers in an attempt to circumvent the pitfalls of TURBT and provide a useful adjunct” [6].

Many studies have validated the VI-RADS score for discriminating muscle-invasive from non-muscle-invasive bladder tumors (Table 2). Almost all of these studies have considered a VI-RADS cut-off of either ≥ 3 or ≥ 4 to predict muscle-invasion. Moreover, we could find only one study [7] that assessed the performance of the VI-RADS score for differentiating low-grade from high-grade bladder UC.

In the present study, while almost all patients with VI-RADS 1 tumor had non-invasive UC on TURBT HPE, there was considerable discrepancy at higher VI-RADS scores with regard to muscle-invasiveness. It is reiterated

here that the biopsy specimens of all patients had muscle in them. 40% patients with VI-RADS 2 had muscle-invasive disease, and a lesser 36.4% patients with VI-RADS 3 had muscle-invasive disease. 73.3% and 66.7% patients respectively with VI-RADS 4 and VI-RADS 5 tumors had muscle invasion on biopsy. AUC was 0.722, which was lower than other similar studies. Further, while the sensitivity of a VI-RADS score of ≥ 3 to detect muscle-invasiveness was 84%, the specificity was only 44% with an accuracy of 64%. The sensitivity of a VI-RADS score of ≥ 4 to detect muscle-invasive tumor was 68%, while the specificity was 72% with an accuracy of 70%.

As an inference, sole reliance on the VI-RADS score in the case of higher VI-RADS as a measure of muscle-invasiveness after a mere TUR biopsy might not be a prudent thing to do, and the aim should be, unless the tumor is not amenable to complete resection, removal of all visible tumor with a deep muscle biopsy, regardless of the VI-RADS score on pre-operative MRI. mpMRI with the VI-RADS score can, at best, only be used as an adjunct in the workup of patients with urinary bladder tumor. Further, mpMRI does not diagnose CIS and tumors with variant histology, which is only possible by cystoscopy (with additional use of enhanced cystoscopy) and TURBT.

Gmeiner et al [7] have shown that “mpMRI of the bladder, especially the diffusion-weighted component does provide information in addition to muscle-invasiveness, such as tumor grade, which is an important prognostic marker, and guides treatment. Hence, we investigated the diagnostic performance of VI-RADS in assessing bladder cancer grading. We got an AUC of 0.709 (95% CI 0.567, 0.852), with a sensitivity of 82% and specificity 44% of for a VI-RADS score of ≥ 3 to predict high-grade tumor”.

For what it is worth, the current state of the VI-RADS score does not consider several validated predictors of muscle invasion such as ureteral infiltration (causing hydronephrosis) or the number and location of lesions, including diverticular tumors. Moreover, using mpMRI and the VI-RADS score, there is no way to predict lymphovascular invasion, CIS or variant histology.

Table 2. Summary of prior studies on the accuracy of the VI-RADS score, including the present study

Author	Year	Design	Cases	Cut-off score	Sensitivity	Specificity	AUC
Ueno et al. [13]	2019	R	74	≥ 3	88	77	0.90
				≥ 4	76	93	
Wang H et al. [14]	2019	R	340	≥ 3	87.1	96.5	0.94
Makboul et al. [15]	2019	P	50	≥ 3	78	88	0.83
Barchetti et al. [16]	2019	R	75	> 3	82 (1)	94 (1)	0.93 (1)
					77 (2)	89 (2)	0.87 (2)
Del Giudice et al. [17]	2020	P	231	≥ 3	91.9	91.9	0.94
Ueno et al. [18]	2020	R	91	≥ 4	74.1	94.1	0.87 (pooled)
Vaz et al. [19]	2020	R	30	> 3	100	90	N/A
Kim et al. [20]	2020	R	297	≥ 3	94.6	43.9	N/A
				≥ 4	91.3	76	
Marchioni et al. [21]	2020	P	38	> 3	85.7	86.9	0.9
Hong et al. [22]	2020	R	32	> 3	90	100	0.95
Liu et al. [23]	2020	R	126	≥ 3	100	50	0.96
				≥ 4	94	92.1	
Wang Z. et al. [24]	2020	R	220	> 3	82.3	95.3	0.89
Gmeiner et al. [7]	2020	R	57	> 3	92.9 (1)	95.1 (1)	0.99 (1)
					100 (2)	92.5 (2)	0.99 (2)
Sakamoto et al. [25]	2020	R	176	≥ 3	78	70	0.86 (pooled)
				≥ 4	63	96	
Arita et al. [26]	2020	R	66	≥ 3	(82.4 – 94.1)	(83.7 – 89.8)	(0.89 – 0.94)
Ghanshyam K et al. [27]	2021	P	86	≥ 3	79.4	94.2	0.922
				≥ 4	91.2	78.8	
Huang S et al. [28]	2021	R	64	≥ 3	91 (1)	68 (1)	0.79 (1), 0.77 (2)
					91 (2)	63 (2)	
				≥ 4	86 (1)	79 (1)	
					86 (2)	84 (2)	
Erkoc M et al. [29]	2021	P	330	≥ 3	91.3	91.8	0.934
Metwally et al. [30]	2021	P	331	> 3	84.1	92.3	0.879
Ikuma et al. [31]	2022	R	129	> 4	92	87	0.89
Present study	2022	P	50	≥ 3	84	44	0.722
				≥ 4	68	72	

(1) = Reader 1, (2) = Reader 2, P = prospective, R = retrospective

5. CONCLUSIONS

Muscle-invasiveness is an important characteristic of BC, and management strategies differ based on its presence or absence. Tumor grade is another important characteristic of BC, impacting management and prognostication. The VI-RADS score was developed and studied for BC local staging and to discriminate between NMIBC and MIBC. However, the lack of accuracy of correlation in the present study and the lack of identification of important prognostic markers for BC on MRI, such as CIS, lymphovascular invasion and variant histology, in addition to the extra costs incurred, relegates mpMRI and the VI-RADS score to being only adjuncts in the diagnostic work-up of BC.

6. LIMITATIONS OF THE STUDY

It was a single institute experience with a relatively small sample size, so, it is difficult to generalize the results. A multicentric study with a larger sample size is desirable to validate our observations.

CONSENT

All authors declare that 'written informed consent was obtained from the patients (or other approved parties) for participation in this study.

ETHICAL APPROVAL

The study protocol was reviewed and approved by the Institutional Ethics Committee of Gauhati Medical College and Hospital, Guwahati (vide letter number MC/190/2007/PtII/Oct-2020/TH-2).

COMPETING INTERESTS

Authors have declared that no competing interests exist.

REFERENCES

1. Babjuk M, Burger M, Compérat E, et al.: Guidelines on Non-muscle-invasive Bladder Cancer (Ta, T1 and CIS). EAU Annual Congress Amsterdam 2022. EAU Guidelines Office, the Netherlands; 2022.
2. Kumar V, Abbas AK, Aster JC: Robbins and Cotran pathologic basis of disease, 9th ed. ISBN 978-14-55726-13-4. Elsevier/Saunders, Philadelphia, PA; 2015.
3. Kulkarni GS, Hakenberg OW, Gschwend JE, Thalmann G, Kassouf W, Kamat A, Zlotta A: An updated critical analysis of the treatment strategy for newly diagnosed high-grade T1 (previously T1G3) bladder cancer. *European Urology*. 2010;57(1):60-70. DOI:10.1016/j.eururo.2009.08.024
4. Suarez-Ibarrola R, Soria F, Abufaraj M, et al.: Surgical checklist impact on recurrence-free survival of patients with non-muscle-invasive bladder cancer undergoing transurethral resection of bladder tumour. *BJU International*. 2019; 123(4):646-50. DOI:10.1111/bju.14557
5. Divrik RT, Şahin AF, Yıldırım Ü, Altok M, Zorlu F: Impact of routine second transurethral resection on the long-term outcome of patients with newly diagnosed pT1 urothelial carcinoma with respect to recurrence, progression rate, and disease-specific survival: a prospective randomised clinical trial. *European Urology*. 2010; 58(2):185-90. DOI:10.1016/j.eururo.2010.03.007
6. Panebianco V, Narumi Y, Altun E, et al.: Multiparametric magnetic resonance imaging for bladder cancer: development of VI-RADS (Vesical Imaging-Reporting And Data System). *European Urology*. 2018;74(3):294-306. DOI:10.1016/j.eururo.2018.04.029
7. Gmeiner J, Garstka N, Helbich TH, Shariat SF, Baltzer PA: Vesical Imaging Reporting and Data System (VI-RADS): Are the individual MRI sequences equivalent in diagnostic performance of high grade NMIBC and MIBC?. *European Journal of Radiology*. 2021;142:109829. DOI:10.1016/j.ejrad.2021.109829
8. Mishra V, Balasubramaniam G: Urinary bladder cancer and its associated factors – An epidemiological overview. *Indian J Med Sci*. 2021;73(2):239-48. DOI:10.25259/IJMS_159_2020
9. Gore JL, Lai J, Setodji CM, Litwin MS, Saigal CS: Mortality increases when radical cystectomy is delayed more than 12 weeks: results from a Surveillance, Epidemiology, and End Results-Medicare analysis. *Cancer: Interdisciplinary International Journal of the American Cancer Society*. 2009;115(5):988-96. DOI:10.1002/cncr.24052
10. Shariat SF, Palapattu GS, Karakiewicz PI, et al.: Discrepancy between clinical and pathologic stage: impact on prognosis after

- radical cystectomy. *European Urology*. 2007;51(1):137-51.
DOI:10.1016/j.eururo.2006.05.021
11. Re: Marko Babjuk, Andreas Böhle, Maximilian Burger, et al.: EAU Guidelines on Non-muscle-invasive Urothelial Carcinoma of the Bladder: Update 2016. *European Urology*. 2017;71:447-61.
DOI:10.1016/j.eururo.2016.11.030
 12. Brausi M, Collette L, Kurth K, et al.: Variability in the recurrence rate at first follow-up cystoscopy after TUR in stage Ta T1 transitional cell carcinoma of the bladder: a combined analysis of seven EORTC studies. *European Urology*. 2002; 41(5):523-31.
DOI:10.1016/S0302-2838(02)00068-4
 13. Ueno Y, Takeuchi M, Tamada T, et al.: Diagnostic accuracy and interobserver agreement for the vesical imaging-reporting and data system for muscle-invasive bladder cancer: a multireader validation study. *European Urology*. 2019; 76(1):54-6.
DOI:10.1016/j.eururo.2019.03.012
 14. Wang H, Luo C, Zhang F, et al.: Multiparametric MRI for bladder cancer: validation of VI-RADS for the detection of detrusor muscle invasion. *Radiology*. 2019;291(3):668-74.
DOI:10.1148/radiol.2019182506
 15. Makboul M, Farghaly S, Abdelkawi IF: Multiparametric MRI in differentiation between muscle invasive and non-muscle invasive urinary bladder cancer with vesical imaging reporting and data system (VI-RADS) application. *The British Journal of Radiology*. 2019;92(1104):20190401.
DOI:10.1259/bjr.20190401
 16. Barchetti G, Simone G, Ceravolo I, et al.: Multiparametric MRI of the bladder: inter-observer agreement and accuracy with the Vesical Imaging-Reporting and Data System (VI-RADS) at a single reference center. *European Radiology*. 2019;29(10):5498-506.
DOI:10.1007/s00330-019-06117-8
 17. Del Giudice F, Barchetti G, De Berardinis E, et al.: Prospective assessment of vesical imaging reporting and data system (VI-RADS) and its clinical impact on the management of high-risk non-muscle-invasive bladder cancer patients candidate for repeated transurethral resection. *European Urology*. 2020;77(1):101-9.
DOI:10.1016/j.eururo.2019.09.029
 18. Ueno Y, Tamada T, Takeuchi M, et al.: VI-RADS: multiinstitutional multireader diagnostic accuracy and interobserver agreement study. *American Journal of Roentgenology*. 2021;216(5):1257-66.
DOI:10.2214/AJR.20.23604
 19. Vaz A, Zapparoli M: Diagnostic accuracy of retrospective application of the Vesical Imaging-Reporting and Data System: preliminary results. *Radiologia Brasileira*. 2019;53:21-6.
DOI:10.1590/0100-3984.2019.0063
 20. Kim SH: Validation of vesical imaging reporting and data system for assessing muscle invasion in bladder tumor. *Abdominal Radiology*. 2020;45(2):491-98.
DOI:10.1007/s00261-019-02190-1
 21. Marchioni M, Primiceri G, Pizzi AD, et al.: Could bladder multiparametric MRI be introduced in routine clinical practice? Role of the new VI-RADS score: results from a prospective study. *Clinical Genitourinary Cancer*. 2020;18(5):409-15.
DOI:10.1016/j.clgc.2020.03.002
 22. Hong SB, Lee NK, Kim S, et al.: Vesical imaging-reporting and data system for multiparametric MRI to predict the presence of muscle invasion for bladder cancer. *Journal of Magnetic Resonance Imaging*. 2020;52(4):1249-56.
DOI:10.1002/jmri.27141
 23. Liu S, Xu F, Xu T, Yan Y, Yao X, Tang G: Evaluation of Vesical Imaging-Reporting and Data System (VI-RADS) scoring system in predicting muscle invasion of bladder cancer. *Translational Andrology and Urology*. 2020;9(2):445.
DOI:10.21037/tau.2020.02.16
 24. Wang Z, Shang Y, Luan T, Duan Y, Wang J, Wang H, Hao J: Evaluation of the value of the VI-RADS scoring system in assessing muscle infiltration by bladder cancer. *Cancer Imaging*. 2020;20(1):1-8.
DOI:10.1186/s40644-020-00304-3
 25. Sakamoto K, Ito M, Ikuta S, et al.: Detection of muscle-invasive bladder cancer on biparametric MRI using Vesical Imaging-Reporting and Data System and Apparent Diffusion Coefficient values (VI-RADS/ADC). *Bladder Cancer*. 2020;6(2): 161-9.
DOI:10.3233/BLC-190267
 26. Arita Y, Shigeta K, Akita H, et al.: Clinical utility of the Vesical Imaging-Reporting and Data System for muscle-invasive bladder cancer between radiologists and urologists based on multiparametric MRI including 3D

- FSE T2-weighted acquisitions. *European Radiology*. 2021 Feb, 31(2):875-83.
DOI:10.1007/s00330-020-07153-5
27. Ghanshyam K, Nachiket V, Govind S, Shivam P, Sahay GB, Mohit S, Ashok K: Validation of vesical imaging reporting and data system score for the diagnosis of muscle invasive bladder cancer: A prospective cross-sectional study. *Asian Journal of Urology*; 2021.
DOI:10.1016/j.ajur.2021.06.001
28. Huang S, Bain J, Yiu TW, Gilbourd D, Haxhimolla HZ, Jain T, Jyoti R: Accuracy of the Vesical Imaging-Reporting and Data System (VIRADS) for pre-treatment staging of bladder cancer in an Australian cohort. *Journal of Medical Imaging and Radiation Oncology*. 2022;66(3): 370-6.
DOI:10.1111/1754-9485.13317
29. Erkoç M, Otunçtemur A, Bozkurt M, et al.: The efficacy and reliability of VI-RADS in determining candidates for repeated transurethral resection in patients with high-risk non-muscle invasive bladder cancer. *International Journal of Clinical Practice*. 2021;75(9):e14584.
DOI:10.1111/ijcp.14584
30. Metwally MI, Zeed NA, Hamed EM, et al.: The validity, reliability, and reviewer acceptance of VI-RADS in assessing muscle invasion by bladder cancer: a multicenter prospective study. *European Radiology*. 2021 Sep, 31(9):6949-61.
DOI:10.1007/s00330-021-07765-5
31. Ikuma S, Kimura G, Mikami H, et al.: Vesical Imaging-Reporting and Data System (VI-RADS). *Journal of Clinical Oncology*. 2022;40(6_suppl):453.
DOI:10.1200/JCO.2022.40.6_suppl.453

© 2022 Sathaye et al.; This is an Open Access article distributed under the terms of the Creative Commons Attribution License (<http://creativecommons.org/licenses/by/4.0>), which permits unrestricted use, distribution, and reproduction in any medium, provided the original work is properly cited.

Peer-review history:
The peer review history for this paper can be accessed here:
<https://www.sdiarticle5.com/review-history/89798>