



Crestal Sinus Lift-Sinus Crestal Approach Kit and Simultaneous Implant Placement Using Platelet Rich Fibrin as an Exclusive Graft Material

Sarayu Gopal^{a*}

^a *Department of Oral and Maxillofacial Surgery, Rajiv Gandhi University of Health Sciences, Bengaluru, Karnataka, India.*

Author's contribution

The sole author designed, analysed, interpreted and prepared the manuscript.

Article Information

Open Peer Review History:

This journal follows the Advanced Open Peer Review policy. Identity of the Reviewers, Editor(s) and additional Reviewers, peer review comments, different versions of the manuscript, comments of the editors, etc are available here: <https://www.sdiarticle5.com/review-history/89238>

Original Research Article

Received 08 May 2022
Accepted 13 July 2022
Published 19 July 2022

ABSTRACT

Background: Sinus augmentation surgery has become a well accepted preprosthetic procedure for creating sufficient bone volume for the placement of endosseous implants in the atrophic posterior maxilla. All of the indirect sinus augmentation procedures to bring about sinus lift present the possibility of Schneiderian membrane perforation, the most common intraoperative complication with these techniques, with perforation rates of 21.4% on an average reported in the literature. This complication can occur either during osteotomy, which is performed with burs, or during the elevation of the membrane. Several other post operative complications reported are due to the malleting forces - benign paroxysmal vertigo, headache, excessive bleeding and other sinus complaints. During sinus-lift, the biomaterials are used as space maintainers and bone scaffold to promote bone formation in the sub sinus area. As evidenced by literature, when graft is not used, some authors have shown that true bone gain is in fact always limited and that implant apical ends might be enmeshed in the sinus connective tissue and, thus, not osseointegrated.

Methods: To evaluate the Efficacy of Sinus Crestal Approach (SCA) kit for Indirect sinus lift surgeries and further evaluate the bone regenerative property and over all utility of Platelet rich-fibrin when used as the exclusive graft material for sinus lift cases. Fifteen healthy patients seeking replacement of missing teeth in atrophic posterior maxilla or pneumatization of sinus with all other situations ideal for placing implants were chosen. SCA kit was used for the surgical intervention. Endosseous implants of appropriate length and diameter with autologous graft material (PRF) was placed in the premolar-molar region. All patients were followed for clinical and radiological evaluation using IOPAR and digital OPG after 1 week, 3, 6 and 12 months period.

*Corresponding author: Email: sarayugpl21@gmail.com;

Results and Conclusion: SCA kit is an innovative tool to perform indirect sinus augmentation surgery in the atrophic posterior maxilla for prosthetic rehabilitation with limited complications. At the end of the study, the mean endosinus bone gain measured on the proximal sides of the implant was 1.2mm. Choukroun's PRF used as sole filling material during the sinus lift and simultaneous implantation creates space and acts as a scaffold for predictable bone formation.

Keywords: Sinus crestal approach (SCA) kit; S reamer; maxillary sinus; indirect sinus lift; platelet rich fibrin (PRF) graft material; endosinus bone gain.

1. INTRODUCTION

In the posterior maxilla, implant placement is often limited due to maxillary sinus extension, especially in the atrophic maxillae. The Dental Implants placement requires a sufficient amount of bone for the stability of implants. Implant placement in the posterior maxilla is more challenging owing to the limited quantity of bone and presence of maxillary sinus.

The implantation of endosseous implants in the atrophic posterior maxilla requires enough bone volume, and sinus augmentation surgery has become a widely approved preprosthetic treatment for achieving this goal [1,2]. The sinus augmentation technique was first presented by Tatum in 1977 and published by Boyne and James in 1980. The most commonly used technique in atrophic posterior maxilla with poor quality of bone or of subantral bone height <5mm is direct sinus augmentation through lateral window osteotomy in the maxillary sinus wall [3-6]. Although predictable, this technique is quite invasive, carries the risk of membrane perforation of 14-56% reported in literature, sinus complications, and associated procedural morbidity [7,8].

The second alternative is the Indirect technique which is a crestal approach given by SUMMERS in 1994 and as described originally involves the use of osteotomes for achieving the sinus lift through a crestal osteotomy [9-11]. Though minimally invasive and can achieve simultaneous bone condensation, it is associated with its share of disadvantages like occurrence of membrane perforation ranging from 0% to 21.4%, poor patient experience to malleting, headache, Postoperative Vertigo, etc [12]. During sinus-lift, different biomaterials are employed as bone scaffolds and space maintainers to encourage bone development in the sub-sinus region. According to the literature, when grafts are not employed, some authors have demonstrated that genuine bone growth is, in fact, always constrained and that implant apical ends may

become entangled in the connective tissue of the sinus and, as a result, not osseointegrate [13-15]. The Sinus Crestal Approach kit (SCA) is a newer and atraumatic system for indirect sinus lift procedure used nowadays [16-19]. The key component of the kit is the drill design of the S-reamer head with stoppers that enhances safety, comfort and success during sinus lift surgery [8]. The drill is designed like letter "S" to prevent tearing the sinus membrane while removing the bone beneath sinus floor. S-reamer provides high speed drilling at 800-1200rpm which removes bone effectively [20-23]. This technique is minimally invasive to bring out the sinus floor elevation in an effective, faster and simpler way.

"Choukroun's platelet rich fibrin is a second generation platelet concentrate that was introduced by Choukroun et al in France in 2001. This Bio graft material is an autologous fibrin matrix containing platelet and leukocyte growth factors which stimulates the proliferation and differentiation of osteoblasts suggesting regenerative potential of PRF" [24]. "It has shown to be an interesting substitution during sinus elevation as it can reduce healing time before functional loading of the implants, acts as a space filler preventing recoil of the sinus membrane, seal any perforations and cushions the membrane during implant placement" [25,26].

The aim of this study was to verify the effectiveness of SCA kit for crestal sinus lift procedures and the osteogenic potential of PRF used as a graft material.

2. MATERIALS AND METHODS

2.1 Source of Data

Fifteen healthy patients reporting to the department of Oral and Maxillofacial Surgery, Coorg Institute of Dental Sciences, seeking replacement of missing teeth in atrophic posterior maxilla or pneumatization of sinus with all other situations ideal for placing implants and consenting for the same were taken up for the study.

Inclusion criteria

1. Planned Implants because of edentulous posterior maxillary segment or single posterior maxillary site with absence of all local factors, preliminary investigations and pre-operative x-ray showing atrophy of maxilla in the molar / premolar area.
2. Initial bone height of $\leq 6\text{mm}$.
3. Implant primary stability will be obtained and the implants placed should be atleast 10mm long.
4. Patient willing to sign an informed consent.
5. Patients having a blood concentration of thrombocytes within the normal range.
6. Wearing a removable partial denture during the healing period is not permitted.

Exclusion criteria

1. The presence of uncontrolled diabetes, immune disease, or other contraindicating systemic conditions.
2. Radiation therapy to the head and neck region in the 12 months before the proposed therapy.
3. Chemotherapy in the 12-month period earlier the proposed therapy.
4. An active sinus infection or a history of persistent sinus infections or cases of deviated nasal septum.
5. Cases which showed the presence of septae in the sinus area in the radiographs were excluded.
6. A smoking habit of 6 cigarettes or more per day.

7. Patients on anti-platelet drugs will also be eliminated.

Surgical Procedure

For each patient, a pre-surgical study consisting of their adequate case history, blood test and radiographic examination were performed first with OPG taken in an implant mode and then with IOPAR taken with standardised setting.

All the cases were carried out by the same operating surgeon, an observing assistant and a two stage implant protocol was followed.

PRF preparation

During the start of the procedure, 20 ml of the patient's blood was collected without anticoagulant and centrifuged at 3000 rpm for 15 minutes. Among the three layers which appear in the tube, PRF clot present in the middle is separated from the red blood cell base at the bottom and acellular plasma as supernatant. These PRF clots are transformed into fibrin membranes by compression between sterile gauzes. These membranes are used as grafting material following the sinus lift.

Patient was comfortably seated and asked to rinse the mouth with chlorhexidine mouthwash. Extra orally the skin was painted with povidone iodine solution and patient draped. The posterior superior alveolar nerve block, infra orbital nerve block and greater palatine nerve block were administered with 2% lignocaine and 1:80,000 adrenaline.

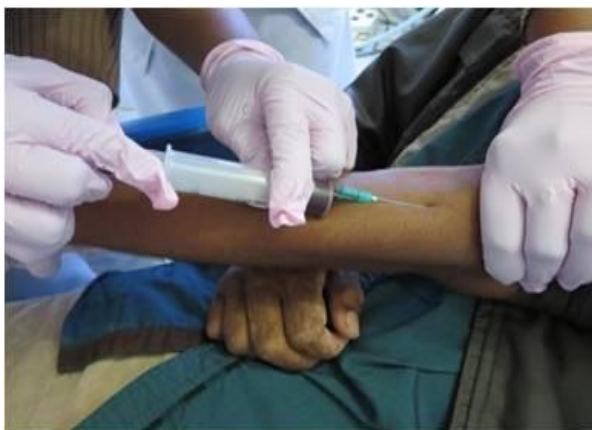

Fig. 1. Autogenous blood withdrawal



Fig. 2. Centrifugation machine

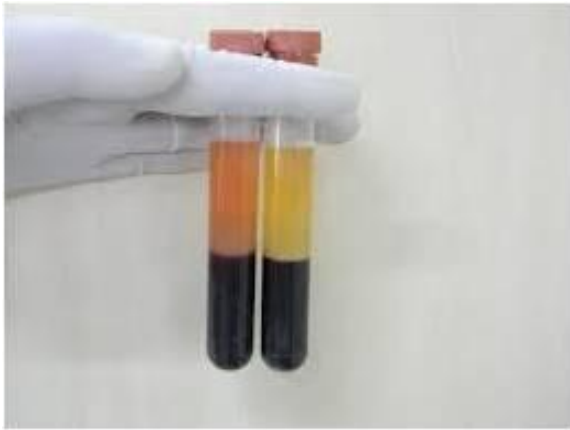

Fig. 3. PRF after centrifugation



Fig. 4. Platelet Rich Fibrin

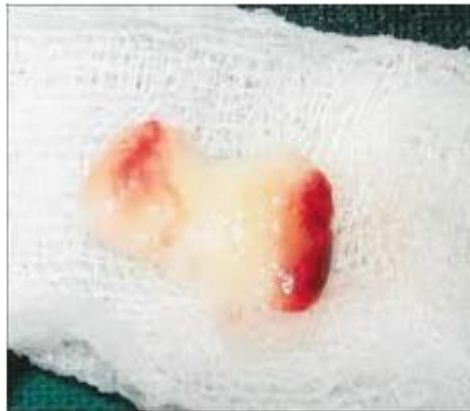

Fig. 5. PRF Membrane

A crestal incision was placed in the posterior edentulous maxilla; a buccal mucoperiosteal flap was reflected to expose the underlying bone. With using the pilot drill and the stopper from SCA kit, osteotomy was performed to a depth 1mm shorter than existing bone length. Then, in a sequential manner S-reamer drills were used with a stopper 1mm longer than existing bone and drilled until the stopper touched on the alveolar crest, where only the inferior cortical wall underneath the sinus would be perforated and bring about elevation of the sinus membrane. The confirmation of membrane integrity was done by irrigation and Valsalva maneuver. Then by inserting a depth gauge carefully the remnant bone height was measured.

Procedure was completed by placing about two to three autogenous derived PRF graft membranes into the height of the sinus lift and appropriate endosseous implants of 4.3 diameter

x 10 mm or 11.5 mm in length before the tissue was closed. The flap was then sutured with 3-0 vicryl.

Postoperative management

Routine post operative instructions were given. Patients were prescribed penicillin derivatives for five days and a combination of NSAIDS for three days and also advised to use chlorhexidine mouthwash twice daily. Patients were not allowed to use any removable prosthesis. The sutures were removed 8 to 10 days after surgery.

For all implants, abutments were placed at 25 N.cm by the end of 12th week postoperatively. Impressions were taken, and suprastructures seated within 2 weeks. This early loading protocol would test the PRF graft for inducing early bone formation and healing.

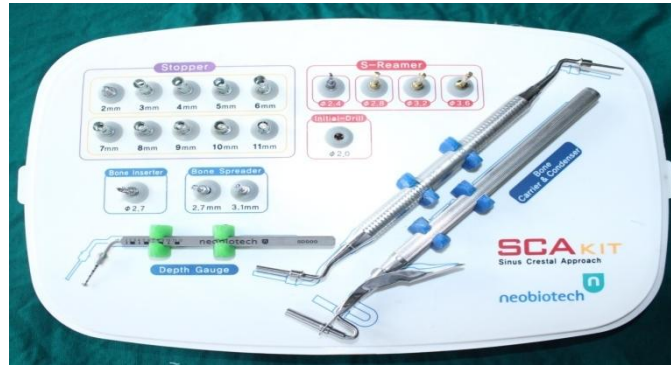
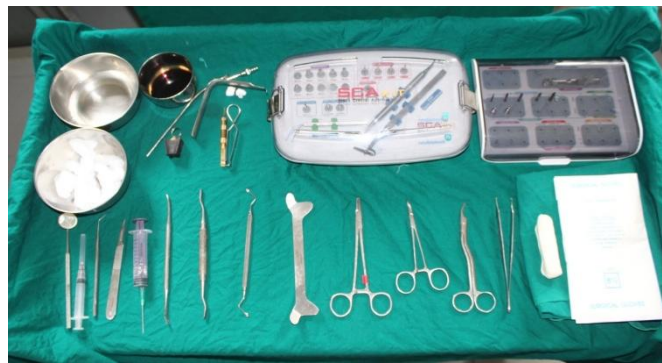
Fig. 6. SCA Kit for Indirect sinus lift.



CASE 1

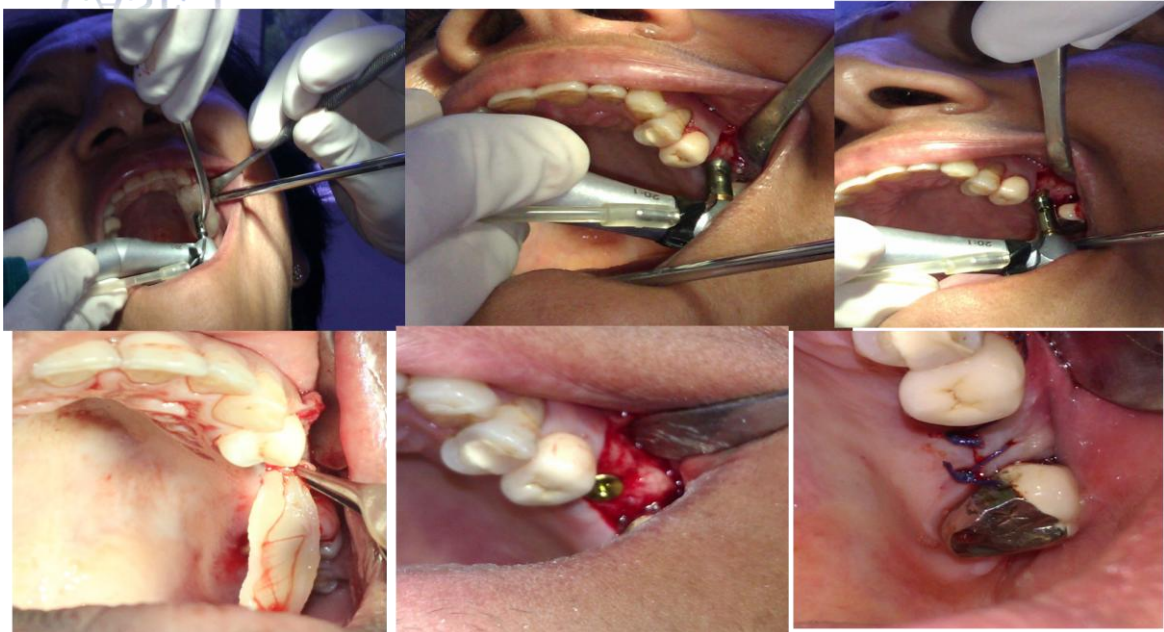


Fig. 7. Indirect sinus lift procedure with simultaneous placement of PRF as a graft Material and appropriate endosseous implants

The parameters assessed include:

A. Intraoperative:

1. Time taken for sinus lift: the time elapsed from the time of entry through the crestal bone till the lifting of the sinus floor and membrane.
2. Integrity of the Schneiderian membrane: assessed visually, with irrigation and valsalva manoeuvre.
3. Any intraoperative complications like bleeding / perforation or any limitations in the sinus lift

B. Postoperative: The following parameters were assessed:

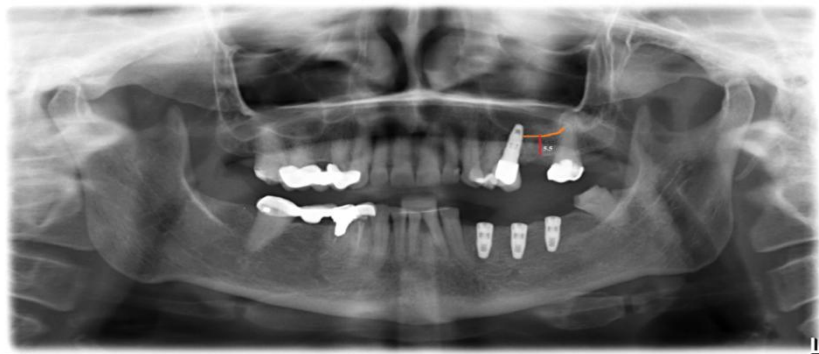
1. Pain on 3rd, 5th and 7th day using the Visual Analogue Scale (VAS). At the end of 1 week, 1 month and 3 months:
2. Sinus complaints (discomfort, nasal congestion, blocked nose).

3. Oro-antral fistula.
4. Premature exposure of implant

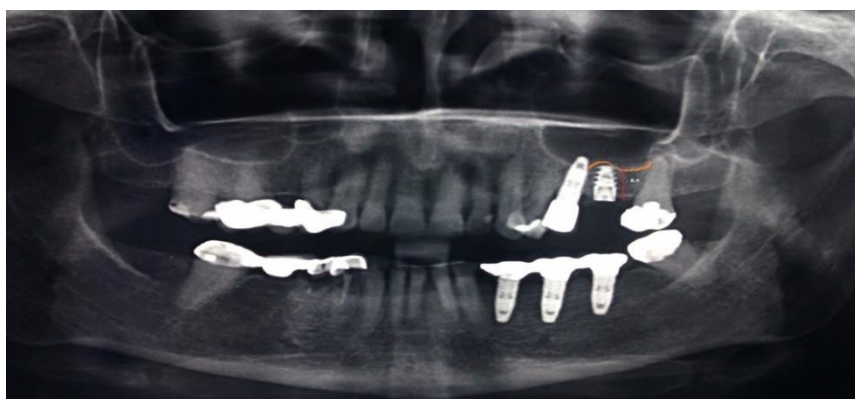
C. Bone level assessed radiographically pre-operative and post-operatively at Abutment connection, 6 months and 12 months: OPG taken in implant mode and the bone levels were measured by two independent observers, from the shoulder of the implant to the most apical end on the proximal sides and compared.

D. Final outcome of the implants placed with earlier loading protocol were evaluated at the end of the study given by Branemark, which includes:

1. Absence of clinically detectable implant mobility.
2. Absence of pain or any subjective sensation.
3. Absence of recurrent peri-implant infection.
4. Absence of continuous radiolucency around the implant.



Pre-op OPG with sinus level measured



Post-op OPG showing sinus lift and implant placed

Fig. 8. Panoramic views pre-op and post-op

3. RESULTS

Fifteen sinus lift procedures were performed in the molar and pre molar-molar region. The average time that was taken for the indirect sinus lift using SCA kit was approximately 11.6 minutes.

In the intra-operative period there were no cases of membrane perforation noted, indicating 100% membrane integrity. There were neither cases of intra-operative hemorrhage noted during the procedure nor any difficulty / limitation in achieving the sinus lift.

There was significant decrease in the pain from day 3 to day 7 post operatively as shown by the p value (< 0.001) indicating the statistical significance.

In the post operative period other parameters like blocked nose, or nasal congestion, were not reported. Neither any cases of chronic sinusitis, nor did any cases of oro antral fistula were noted indicating no sinus involvement. There were no cases of premature exposure of the implant seen during the follow up. The outcome of the sinus lift and the placed implants was evaluated periodically at 3 months, 6 months and 12 months postoperatively. At the end of 12th week, implants were exposed; clinical and radiological parameters were assessed for implant

integration and prosthetic rehabilitation done within two weeks. Twelve months postoperatively, the mean endosinus bone gain measured on the proximal sides of the implant was 1.2 mm.

Table 1. Shows the time elapsed from the time of entry through the crestal bone till the sinus lift achieved

Time taken (in mins) No of patients	Sinus lift
1	10
2	8
3	12
4	15
5	10
6	12
7	10
8	10
9	15
10	10
11	12
12	10
13	13
14	12
15	15
Mean	11.6

The average time that was taken for the indirect sinus lift using SCA kit was approximately 11.6 minutes.

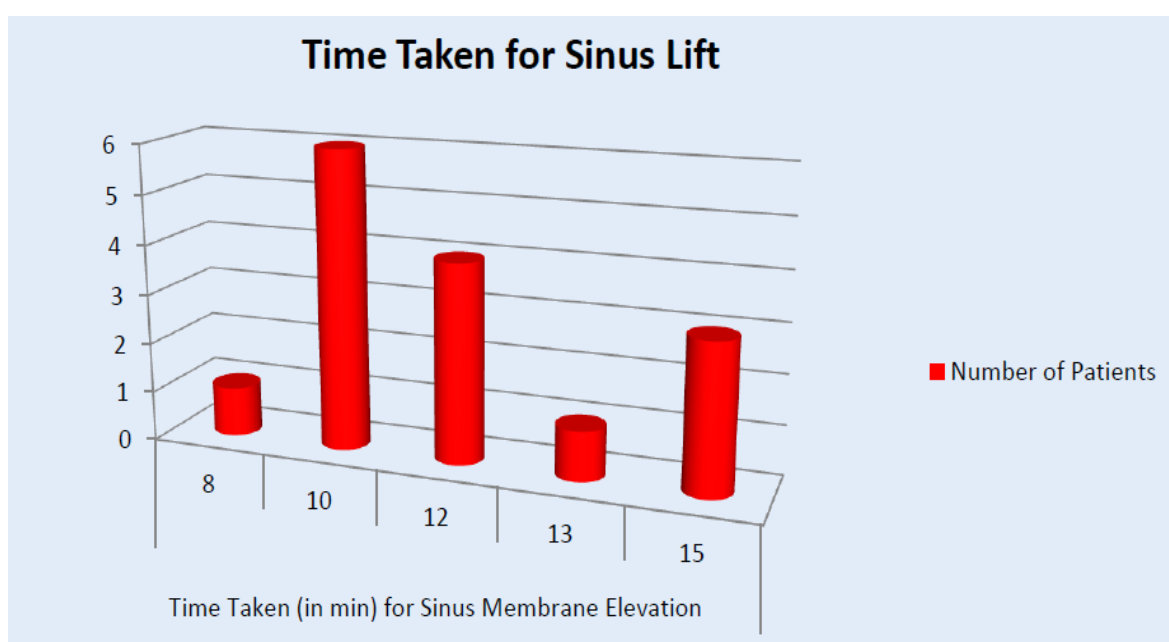


Fig. 9. Post-operative parameters

1. PAIN SCORE (VAS):

Chart 1. Pairwise comparisons

Measure: MEASURE_1				
(I) PAIN	(J) PAIN	Mean Difference (I-J)	Std. Error	Sig. ^b
1	2	1.267	.182	<0.001
	3	2.333	.211	<0.001
2	3	1.067	.118	<0.001

Based on estimated marginal means

b. Adjustment for multiple comparisons: Bonferroni

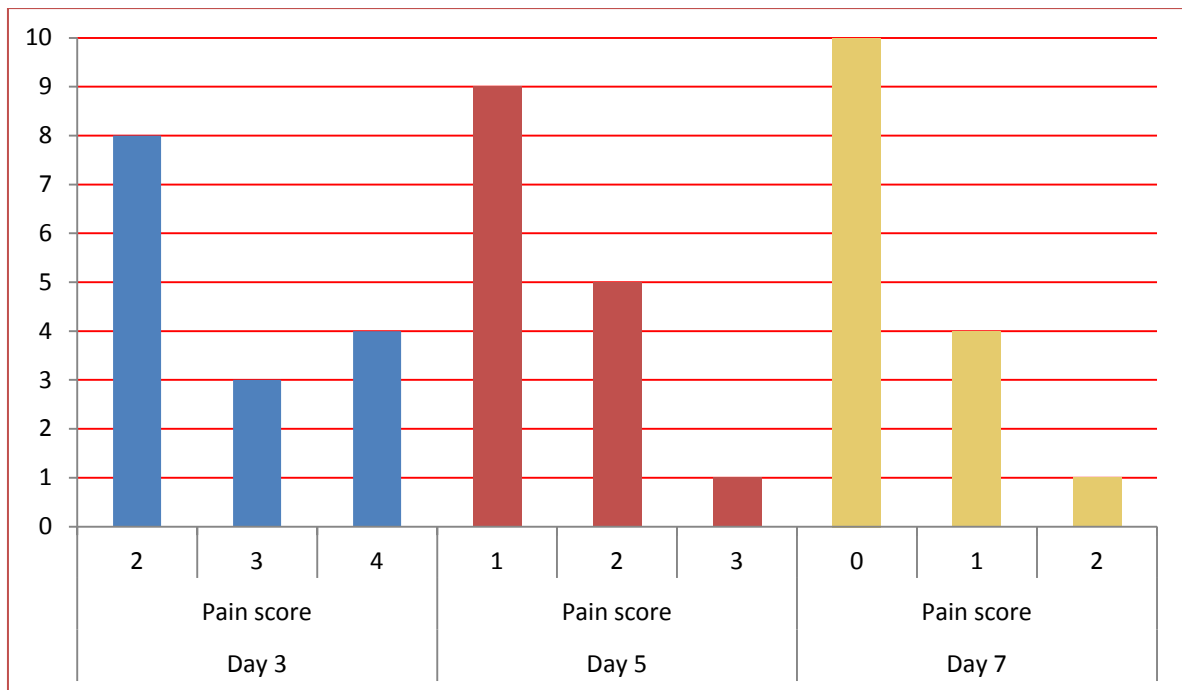


Fig. 10. Pain score

2. Comparison of bone levels assessed radiographically from shoulder of implant to the apical end of implant on proximal sides at 6 months and 12 months.

Table 2. Comparison of bone levels

	Mean	Std. Deviation	F	P value
Pre operative bone level (in m	6.673	1.275	316.7	< 0.0001
Post operative bone level aft	9.907	1.042		
Post operative bone level aft	9.907	1.042		
Newman-Keuls Multiple Comparison Test	Mean Diff.	q	Significant? P < 0.05?	Summary
Pre operative bone level (in m vs POST operative bone level aft	-3.233	30.82	Yes	***
Pre operative bone level (in m vs POST operative bone level aft	-3.233	30.82	Yes	***
Post operative bone level aft vs post operative bone level aft	0.0	0.0	No	ns

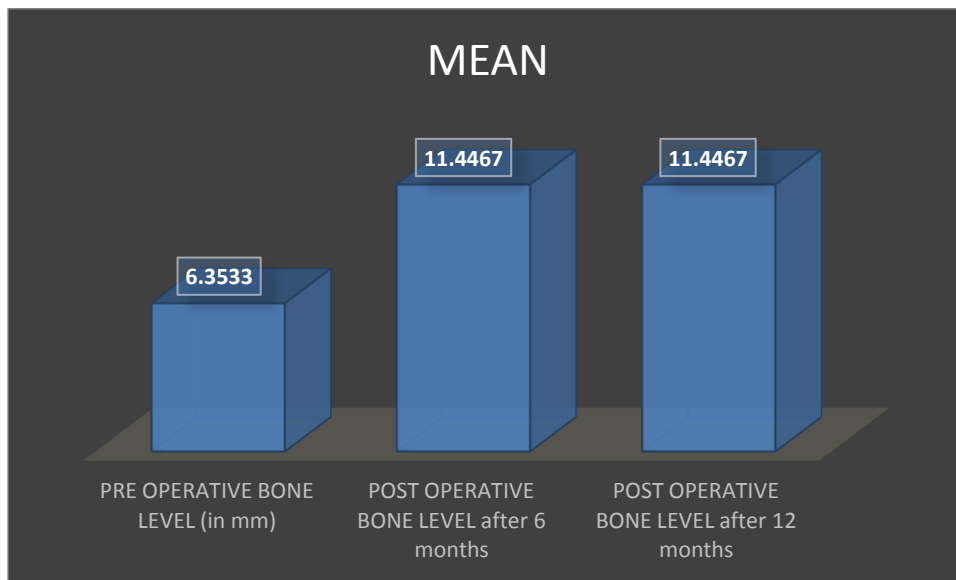


Fig. 11. Bar diagram showing bone level ratio

4. DISCUSSION

Endosseous implants are frequently used for prosthetic reconstruction in the edentulous patients. Tooth loss in the posterior maxilla results in rapid resorption of both vertical and horizontal alveolar bone due to lack of intra osseous stimulation by periodontal ligament fibres. In addition, the absence of upper molars lead to increased pneumatization of the sinus by resorption of bone within a few months resulting in decreased apico-coronal height in the posterior maxilla. Hence, sinus floor elevation is a well recognized method of overcoming this problem and allows implant installation.

There are various approaches to carry out the sinus lift, like the lateral approach or crestal approach, osteotome method being the most popular technique. The osteotome technique is preferred for sinus floor elevation rather than the direct approach, because of less tissue trauma and faster recuperation of the patient. But due to the malleting forces several post operative complications like membrane perforation, benign paroxysmal vertigo and other sinus complaints are noted.⁸ The most common intraoperative complication with these surgical approaches is perforation of Schneiderian membrane, with perforation rates of 14% to 56%.⁵ This complication can occur either during osteotomy, which is performed with burs, or during the elevation of the membrane. Regardless of the effect on outcome parameters, perforations must be repaired to complete the grafting followed by

implant placement. All these complications increase patient morbidity, including postoperative edema, sinus congestion and the cost of the procedure due to requirement of additional materials like collagen membrane, GBR to repair the perforations.

The crestal approach is preferred over the lateral approach owing to the advantages it has, which includes better vascularisation of the graft and less alveolar resorption, minimal bleeding, less postoperative discomfort and patient acceptance. Although the conventional osteotome-mediated elevation is most commonly used, various minimally invasive surgical techniques have been proposed, which are elevation with use of grafting material (BAOSFE), transcristal membrane elevation by inflating a balloon catheter or use of mini elevators or using hydraulic or gel pressure techniques. All these techniques do pose a threat to membrane perforation similar to that with osteotomes as they generate forces or tension on the membrane in an upward direction and also in a non-uniform manner.

The various methods of assessing membrane integrity are Direct visual inspection, Manual exploration, Valsalva maneuver, evaluation by fluid pressure and endoscopic technique through the sinus. In the transcristal techniques, the most widely used of these is Valsalva procedure, where membrane integrity is visually evaluated indirectly by looking out for diaphragm-like effect of detached sinus floor (air entering the sinus) as described by Tatum.

Another important topic debated is about “the filling or not filling during sinus lift? During sinus-lift, the biomaterials are used as space maintainers and bone scaffold to promote bone regeneration in the sub sinus area. The general consensus is that many biomaterials are usable in the sinus, because of the high osteogenic activity of the Schneiderian membrane. Consequently, both crestal approach with osteotome and lateral sinus-lift can easily be performed without any material, particularly for small grafting volume. Unfortunately, when no filling is used, some authors have shown that true bone gain is in fact always limited and that implant apical ends might be enmeshed in the sinus connective tissue and, thus, not osseointegrated” [27].

“When autogenous bone graft is used, it takes approximately 6 months following augmentation for the transplanted bone to be integrated and substituted by osteoconduction. Alternatively, autogenous bone transplants can be replaced by bone substitutes, allograft, xenografts or alloplastic materials to avoid donor site morbidity” [28]. “Maturation of these materials may take up to 8 months if used for sinus augmentation and the use of xenografts affects the religious sentiments of the patient and the surety of infection control does not guarantee the healing process. It would be beneficial for the patient to reduce this time interval by accelerating the process of transplanted bone or bone substitute. Use of platelet-rich plasma was a promising option that remains controversial” [28].

“Choukroun’s PRF is a simple and inexpensive technique that can be used in daily practice. It is the simplest and cheapest way to produce autologous fibrin membrane or platelet concentrate” [29]. “The systematic use of this biomaterial during sinus-lift procedure, with or without bone substitute, seems an interesting option for protection of the Schneiderian membrane as well as stabilizes bone around the implants. The use of PRF as an optimized natural blood clot seems to avoid the enmeshment of implant end in a thick sinus connective tissue. PRF as grafting material has numerous advantages like no donor site morbidity, seals small sinus perforation, acts as a GBR and protects the sinus membrane” [29].

5. CONCLUSION

SCA kit is an innovative tool to perform indirect sinus augmentation surgery in a non-invasive

method in the atrophic posterior maxilla for prosthetic rehabilitation with limited complications as noted in our study. Also, the Choukroun’s PRF used as sole filling material during the sinus lift and simultaneous implantation creates space and acts as a scaffold for predictable bone formation. In the present case series there were no cases of membrane perforation, with 100% success rate. A mean endosinus bone gain of 1.2 mm was noted at the end of 1 year and all the implants were clinically stable which was secondary outcome noted in our study.

Thus within the limitation of the present study we could conclude that the SCA kit can be used as an effective alternative treatment modality to bring about sinus augmentation surgery through the crestal approach. Also the use of the S reamer drill, key component of the kit contributed to the non-invasive membrane elevation and thus enhanced the efficiency of the instrumentation and procedure as a whole which can be repeated in a predictable manner. Choukroun’s PRF is a simple and inexpensive technique which allows the use of this biomaterial as graft in sinus lift cases that has shown to bring about natural bone formation around the implants to some extent.

CONSENT

As per international standard or university standard, patients’ written consent has been collected and preserved by the author(s).

ETHICAL APPROVAL

As per international standard or university standard written ethical approval has been collected and preserved by the author(s).

COMPETING INTERESTS

Author has declared that no competing interests exist.

REFERENCES

1. Pjetursson, et al. Transalveolar maxillary sinus floor elevation using osteotomes with or without grafting material. Part II: Radiographic tissue remodeling. *Clin.Oral Impl.Res.*20. 2009;677-683.
2. Pjetursson BE, et al. A systematic review of the success of sinus floor elevation and survival of implants inserted in combination with sinus floor elevation. *Journal of*

- Clinical Periodontology. 2008; 35(suppl): 216-240.
3. Dohan Ehrenfest, et al. *In vitro* effects of Choukroun's PRF on human gingival fibroblasts, dermal prekeratinocytes, preadipocytes and maxillofacial osteoblasts in primary cultures." Oral Surg Oral Med Oral Pathol Oral Radiol Endod. 2009;108:341-352.
 4. Simonpieri, et al. The relevance of Choukroun's platelet-rich fibrin and metronidazole during complex maxillary rehabilitations using bone allograft. Part II: Implant surgery, prosthodontics, and survival. Implant Dent. 2009;18:220-224.
 5. Diss, et al. Osteotome sinus floor elevation using Choukroun's platelet-rich fibrin as grafting material: A 1-year prospective pilot study with microthreaded implants. OOOOE. 2008;105:572-9.
 6. Sul SH, et al. Histologic changes in the maxillary sinus membrane after sinus membrane elevation and the simultaneous insertion of dental implants without the use of grafting materials. Oral Surg Oral Med Oral Pathol Oral Radiol Endod. 2008;105:e1-e5.
 7. Baldi D, et al. Sinus floor elevation using osteotomes or piezoelectric surgery. Int J Oral Maxillofac Surg. 2011;40:497-503.
 8. Zitzmann NU, Scharer P. Sinus elevation procedures in the resorbed posterior maxilla. Comparison of the crestal and lateral approaches. Oral Surg Oral Med Oral Pathol Oral Radiol Endod. 1998;85:8-17.
 9. Toffler M. Staged sinus floor elevation using crestal core elevation procedure: A review of the technique. J of Implant and Advanced Clinical Dentistry. 2010;2.
 10. Samuel Lee, et al. Crestal window sinus lift, minimally invasive, predictable, and systematic approach to sinus grafting. J Implant and Advanced Clinical Dentistry. 2009;1(1).
 11. Wallace SS, Froum SJ. Effect of maxillary sinus augmentation on the survival of endosseous dental implants. A systematic review. Ann Periodontol. 2003;8:328-343.
 12. Fugazzotto et al. Immediate placement following a modified trephine/osteotome approach: Success rates of 116 implants to 4 years in function. Int J Oral Maxillofac Implants. 2002;17: 113-20.
 13. Choukroun J, et al. Influence of platelet rich fibrin on proliferation of human preadipocytes and tympanic keratinocytes: A new opportunity in facial lipostucture and tympanoplasty. Rev Laryngol Otol Rhinol(Bord). 2007;128:27-32.
 14. Dohan DM, et al. How to find your way in the jungle of latelet concentrates?. Oral Surg Oral Med Oral Pathol Oral Radiol Endod. 2007;103:305-306.
 15. Viña-Almunia J, Peñarrocha-Diago M, Peñarrocha-Diago M. Influence of perforation of the sinus membrane on the survival rate of implants placed after direct sinus lift. Literature update. Med Oral Patol Oral Cir Bucal. 2009;14(3):E133-6.
 16. Alain Simonpieri, et al. Simultaneous Sinus-Lift and Implantation Using Microthreaded Implants and Leukocyte- and Platelet-Rich Fibrin as Sole Grafting Material: A Six-Year Experience. Implant Dent. 2011;20:2-8.
 17. Gassling V, et al. Platelet-rich fibrin membranes as scaffolds for periosteal tissue engineering. Clin Oral Implants Res. 2010;21:543-549.
 18. Nolan P J, Freeman K, Kraut RA. Correlation between schneiderian membrane perforation and sinus lift graft outcome: A retrospective evaluation of 359 augmented sinus. J Oral Maxillofac Surg; 2013.
 19. Lundgren S, et al. Bone reformation with sinus membrane elevation: A new surgical technique for maxillary sinus floor augmentation. Clin Implant Dent Relat Res. 2004;6:165-73.
 20. Penarrocha M, et al. Benign paroxysmal positional vertigo as a complication of osteotome expansion of the maxillary alveolar ridge. J Oral Maxillofac Surg. 2008;59:106-107.
 21. Kim YK, et al. A new crestal approach for sinus floor elevation: Case report. Int j Oral Maxillofac Implants. 2009;28(1):41-48.
 22. Vercellotti T, Paoli SD, Nevins M. The piezoelectric bony window osteotomy and sinus membrane elevation: Introduction of a new technique for simplification of the sinus augmentation procedure. Int J Periodontics Restorative Dent. 2001; 21:561-567.
 23. Sung-Han, et al. Effects of sinus membrane elevation on bone formation around implants placed in the maxillary sinus cavity: an experimental study. Oral Surg Oral Med Oral Pathol Oral Radiol Endod. 2008;105:684-7.

24. Reiser GM, et al. Evaluation of maxillary sinus membrane response following elevation with the crestal osteotome technique in human cadavers. *Int J Oral Maxillofac Implants*. 2001;16:833-840.
25. Zitzmann NU, Scharer P. Sinus elevation procedures in the resorbed posterior maxilla. Comparison of the crestal and lateral approaches. *Oral Surg Oral Med Oral Pathol Oral Radiol Endod*. 1998;85:8-17.
26. Ferrigno, et al. Dental implants placement in conjunction with osteotome sinus floor elevation: 12-year life-table analysis from a prospective study on 588 ITI implants. *Clin Oral Impl Res*. 2006;17:194-205
27. Kassolis JD, et al. Alveolar ridge and sinus augmentation utilizing platelet-rich plasma in combination with freeze-dried bone allograft: case series. *J Periodontol*. 2000; 71:1654-61.
28. Dohan Ehrenfest, et al. Slow release of growth factors and thrombospondin-1 in Choukroun's platelet-rich fibrin: A gold standard to achieve for all surgical platelet concentrates technologies. *Growth factors*. 2009;27:63-69.
29. Mazor, et al. Sinus floor augmentation with simultaneous implant placement using choukroun's platelet-rich fibrin as the sole grafting material: A radiologic and histologic study at 6 months. *J Periodontol*. 2009;80(12):2056-2064.

© 2022 Gopal; This is an Open Access article distributed under the terms of the Creative Commons Attribution License (<http://creativecommons.org/licenses/by/4.0>), which permits unrestricted use, distribution, and reproduction in any medium, provided the original work is properly cited.

Peer-review history:

*The peer review history for this paper can be accessed here:
<https://www.sdiarticle5.com/review-history/89238>*