



A Rare Case Report on Bernard Soulier Syndrome

**Samudrala Lahari ^{a++*}, Bhanu Pratap Singh ^{a#},
P. Rajya Laxmi ^a, B. Tharun ^a and T. Rama Rao ^{bt}**

^a Department of Pharm D, CMR College of Pharmacy, Hyderabad, India.

^b CMR College of Pharmacy, Hyderabad, India.

Authors' contributions

This work was carried out in collaboration among all authors. All authors read and approved the final manuscript.

Article Information

Open Peer Review History:

This journal follows the Advanced Open Peer Review policy. Identity of the Reviewers, Editor(s) and additional Reviewers, peer review comments, different versions of the manuscript, comments of the editors, etc are available here: <https://www.sdiarticle5.com/review-history/126769>

Case Report

Received: 14/09/2024

Accepted: 18/11/2024

Published: 27/11/2024

ABSTRACT

Our aim in this case report is to present the case of a fifteen-year-old boy diagnosed with Bounard soulier syndrome [BSS], to evaluate how the disease was managed, and to identify any shortcomings in its treatment. The patient previously diagnosed with BSS presented with epistaxis and vomiting episodes associated with blood. Immediate Complete blood picture was ordered and tranexemic acid was administered suspecting bleeding in the esophageal/gastric lining. The reports showed thrombocytopenia [27,000 109/L] with large sized platelets, after which Random donor platelets was administered along with antithrombotics and vitamin supplements. Patients with BSS often experience variable frequency of bleeding manifestations due to fluctuating platelet levels and prompt management to rise platelet levels is considered important to for better patient outcome and quality of life. Females with BSS may be more prone to heavy bleeding in their

⁺⁺ Assistant Professor;

[#] Student;

[†] Principal;

*Corresponding author: E-mail: Samudrala.lahari@gmail.com;

Cite as: Lahari, Samudrala, Bhanu Pratap Singh, P. Rajya Laxmi, B. Tharun, and T. Rama Rao. 2024. "A Rare Case Report on Bernard Soulier Syndrome". *Asian Journal of Case Reports in Medicine and Health* 7 (1):173-77. <https://journalajcrmh.com/index.php/AJCRMH/article/view/206>.

menstrual period. Patient and parent [for pediatric patients] counselling help them understand this condition requiring life time interventions and monitoring. Helping them understand about possible risk of bleeding with other meds such as anticoagulants and advising to refrain from it may help. Constant supervising, reassuring and prompt medical intervention will contribute to positive patient outcomes.

Keywords: Bernard soulier syndrome; giant platelets; pediatrics; random donor platelet; GPIb-V-IX complex mutation.

ABBREVIATIONS

BSS - Bernard Soulier Syndrome
RDP - Random Donor Platelet
AVV - Adeno-Associated Virus

1. INTRODUCTION

“Bernard Soulier syndrome (BSS) is a rare inherited platelet disorder with a prevalence of one in a million people” [1]. “It is caused by genetic abnormalities in the function of the GPIb-V-IX complex, which is required to bind von-Willebrand factor IX” [2]. “The defective GPIb-V-IX complements cannot attach to the endothelium, leading to adhesion failure, and increased patient bleeding tendencies. Mutations in four genes (i.e., GPIb α , GPIb β , GPIX, and GPV) are mainly responsible for creating the products that combine to form the defective complex” [3]. “These mutations have been documented as missense, frameshift, or deletions” [4]. “The clinical signs of BSS involve mucocutaneous bleeding, with the most common presentations being unconstrained bruising, gum bleeding, & epistaxis. In addition to the typical clinical signs, the disorder can also present with menorrhagia, gastrointestinal bleeding, & profuse bleeding after surgery or injury that may be troublesome to control” [5]. “These clinical signs of BSS and the associated thrombocytopenia are more likely to be noted in early childhood. Still, it is often misdiagnosed as other bleeding disorders, such as immune thrombocytopenia (ITP)” [6]. “Due to the rare presentation of BSS and its similar symptomatology to other bleeding disorders, cases can often go undiagnosed or misdiagnosed. In developing countries, where healthcare resources are limited, diagnosing BSS correctly and utilizing resources for appropriate treatment is paramount” [7].

2. CASE PRESENTATION

A 15 yr. Old boy admitted in the hospital with the chief complaints of epistaxis~ 100ml and 2 episodes of vomiting characterized by dark

brown coloured vomitus. The platelet count was 9,000/mm³ (Outside investigational report) and was initially given with Injection Tranexamic acid 500mg twice a day and 1 pint of Ringer lactate. Upon general examination, the patient looked pale; alert, oriented and cooperative with normal vital signs. On systemic examination the findings were unremarkable. Emergency Complete blood picture showed that the patient was anemic and the platelet count was decreased to 27,000 10⁹/L marked by giant platelets, a hemoglobin of 8mg/dL, WBC count of 6.13 10⁹/L, Mean corpuscular volume of 25.3fL, Mean corpuscular hemoglobin of 66.4pg, Mean corpuscular hemoglobin concentration of 31.6g/dL was found. The patient has been diagnosed as Bernard-Soulier Syndrome at the age of 9 years. He had similar complaints 6 months back for which no medical intervention was required. History of cough on & off is informed. Treatment started with Inj. tranexamic acid 500mg BD, Inj. ondansetron 4mg BD, & 4 pint RDP (Random donor platelet) transfusion. On the next day status post 4 pint of RDP transfusion, epistaxis subsided and the patient received Factor VII 5000U/ IV in 100ml normal saline, Injection Tranexamic acid 500mg BD & 1 pint of PC (Platelet concentrate) transfusion. On the next day of admission Epistaxis subsided and the patient was prescribed with Inj. tranexamic acid 500mg BD, Tab. Iron folic acid [IFA] 325mg OD & Tab. Vitamin C 500mg OD. Complete blood picture report of patient shows a hemoglobin of 6g/dL, RBC of 2.78 10¹²/L, WBC of 8.55 10⁹/L and platelet of 9000 10⁹/L. Regards of these findings, 4 pint of RDP transfusion was again planned and was transfused the next day with post transfusion prescription of Inj. Tranexamic acid 500mg BD, Tab. IFA 325mg OD & Tab. Vitamin C 500mg OD. No active bleed has been observed and immediate CBP of the patient was advised by the doctor. The reports reveals slight increase in platelets to 16,000 10⁹/L. 2 pints of RDP was again planned after which the blood picture investigation shows increasing platelets to 21,000 10⁹/L & Hemoglobin 8g/dL. The treatment was continued with Inj. tranexamic

Table 1. Laboratory findings of the patient

Parametes	Day 1	Day2	Day 4	Day 7
Hb (g/dL)	8	6	7	8
WBC (10 ⁹ /L)	6.13	8.55	8.52	8.55
RBC (10 ¹² /L)	-	2.78	2.85	2.92
PLT (10 ⁹ /L)	27,000	9000	16,000	21,000

Note: WBC- White blood cells (4-11 10⁹/L), RBC- Red blood cells (3.50-5.50 10¹²/L), Hg- Hemoglobin (12-13 mg/dl), PLT- Platelet count (150-450 10⁹/L)

acid & vitamin supplements along with transfusions with a goal to stabilize the platelet count in the patient. The patient was mild anemic & in good health with follow up prescription of Iron folic acid.

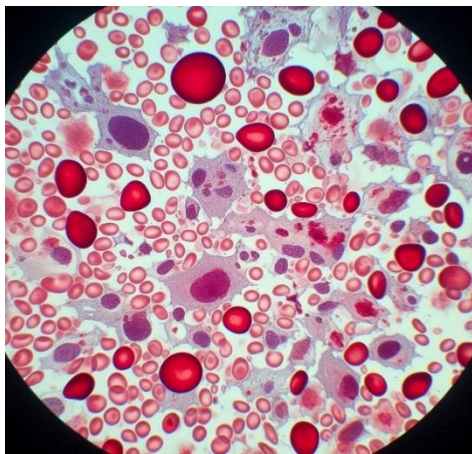


Fig. 1. Uneven and giant platelets on blood smear

3. DISCUSSION

The uncommon hereditary bleeding illness known as Bernard-Soulier syndrome, or hemorrhagiparous thrombocytic dystrophy, was initially reported by Bernard and Soulier in 1948 and affects the megakaryocyte cell line. The condition is caused by a quantitative or qualitative deficiency in the platelet membrane glycoprotein Ib/IX/V complex, which is a receptor for von Willebrand factor. Less than one in a million cases were documented, and it appears to be more common in nations with high rates of consanguineous marriage. Its test results show extended bleeding time, giant platelets, and thrombocytopenia. BSS is characterized by a constellation of mild hemorrhagic manifestations, including easy bruising, epistaxis, gingival bleeding, and excessive menstrual bleeding. Symptoms typically start in childhood but diagnosis may be delayed until late adulthood due to subtle bleeding. Bleeding severity and frequency can fluctuate, often decreasing with

age. However, females with BSS may still have heavy periods and bleeding issues during childbirth [8].

The GPIb-IX-V complex plays a vital role in processes like inflammation, hemostasis, and thrombosis. GP1ba, the linchpin of this complex acts as the principal ligand-binding domain, interacting with factors crucial for these processes. Mutations, particularly within the GP1BA gene, disrupt the function or expression of GP1ba, leading to Bernard-Soulier syndrome. BSS can manifest due to a spectrum of mutations in the GP1BA gene, including missense, nonsense, frameshift mutations, and thrombocytopenia due to severe thrombocytopenia. This patient exhibited normal GPIX (CD42a) expression, harbouring a homozygous nonsense mutation in the GP1BA insertions/deletions. A study by Ozdemir et al. described a pediatric BSS case initially misdiagnosed as neonatal immune gene [9]. Ghalloussi et al. documented the inaugural instance of BSS attributable solely to a complete deletion of the GP9 gene [10]. Minkov et al. identified two novel mutations within genes encoding key components of the GPIb-IX-V complex [GP1BA & GP9 genes], potentially leading to Bernard-Soulier syndrome One mutation in the GP9 gene results in an amino acid substitution (p.Cys38Arg), while the other, a nonsense mutation in the GP1BA gene, introduces a premature stop codon (p.Gln346Ter). This latter mutation likely truncates the GP1ba protein, potentially rendering it dysfunctional and contributing to BSS pathogenesis. A triad of low platelet count, macro thrombocytopenia, and diminished or absent expression of GPIb-IX-V complex components constitutes a definitive diagnostic indicator for BSS [11].

Flow cytometry aids in diagnosing hereditary platelet disorders, particularly in pediatric cases, yet confirms only 60% of diagnoses, necessitating further platelet morphology and laboratory analyses for a comprehensive

diagnosis of Bernard-Soulier syndrome. BSS is further characterized by a diminished response to ristocetin in light transmission platelet aggregometry. Clinical and laboratory evaluations reveal distinct variations among patients with Bernard-Soulier syndrome. While some GP1ba mutations are phenotypically silent, others manifest as a spectrum of BSS severity. This phenotypic heterogeneity is attributed to structural alterations within the receptor itself [9].

Lentiviral gene editing holds promise for treating severe inherited bleeding disorders like Bernard-Soulier syndrome, concerns remain regarding its potential to induce oncogenic or infectious changes, along with other unforeseen transformations in targeted cells. Conversely, Adeno-associated virus (AAV)-based gene therapy offers a potentially safer approach due to its epigenetic nature. The expression of transgenic proteins introduced by AAV therapy tends to diminish over time. Future research aimed at minimizing risk factors associated with lentiviral vectors could pave the way for a definitive and efficient cure for BSS by enabling single-cell line correction [12]. In our case, patient epistaxis has been not resolved alone by tranexamic acid and needed severe RDP transfusions to subside bleeding.

4. CONCLUSION

Accurate and prompt diagnosis of Bernard-Soulier syndrome is paramount for effective disease management. Given its clinical overlap with other platelet disorders, meticulous differential diagnosis is essential. Platelet transfusion should be approached cautiously. Empowering patients through comprehensive education regarding BSS and its potential complications is crucial; this fosters self-care strategies that enhance patient well-being.

DISCLAIMER (ARTIFICIAL INTELLIGENCE)

Author(s) hereby declare that generative AI technologies such as Large Language Models have been for Text to image generation in the manuscripts.

Details of the AI usage are given below:

1. Version name: COPILOT on Windows 11
2. Prompt: Create me a simplest and realistic image a slide under microscope of how giant platelet cells along with RBC, WBC will look on a slide under microscope in bernard soulier patient.

CONSENT

As per international standards or university standards, patient(s) written consent has been collected and preserved by the author(s).

ETHICAL APPROVAL

It is not applicable.

COMPETING INTERESTS

Authors have declared that no competing interests exist.

REFERENCES

1. Sumitha E, Jayandharan GR, David S, Jacob RR, Devi GS, Bargavi B, Srivastava A. Molecular basis of Bernard-soulier syndrome in 27 patients from India. *Journal of Thrombosis and Haemostasis*. 2011;9(8):1590-1598. DOI: 10.1111/j.1538-7836.2011.04417.x
2. Nurden P, Nurden AT. Congenital disorders associated with platelet dysfunctions. *Thrombosis and Haemostasis*. 2008;99(02):253-263. DOI: 10.1160/TH07-09-0568
3. Sandrock K, Knöfler R, Greinacher A, Füll B, Gerisch S, Schuler U, Zieger B. Novel mutation in Bernard-Soulier syndrome. *Transfusion Medicine and Hemotherapy*. 2010;37(5):278-283. DOI: 10.1159/000320255
4. Cattaneo M. Inherited platelet-based bleeding disorders. *Journal of Thrombosis and Haemostasis*. 2003;1(7):1628-1636. DOI: 10.1046/j.1538-7836.2003.00266.x
5. Andrews RK, Berndt MC. Bernard-Soulier syndrome: An update. In *Seminars in Thrombosis and Hemostasis*. Thieme Medical Publishers. 2013;39(06):656-662. DOI: 10.1055/s-0033-1353390
6. Sachs UJ, Kroll H, Matzdorff AC, Berghöfer H, López JA, Santoso S. Bernard-Soulier syndrome due to the homozygous Asn-45Ser mutation in GPIX: An unexpected, frequent finding in Germany. *British Journal of Haematology*. 2003;123(1):127-131. DOI: 10.1046/j.1365-2141.2003.04554.x
7. Iqbal S, Zakar R, Fischer F, Zakar MZ. Consanguineous marriages and their association with women's reproductive health and fertility behavior in Pakistan: Secondary data analysis from

- Demographic and Health Surveys. 1990–2018. BMC Women's Health. 2022;22(1):118.
DOI: 10.1186/s12905-022-01704-2
8. Reisi N. Bernard-Soulier syndrome or idiopathic thrombocytopenic purpura: A case series. Caspian Journal of Internal Medicine. 2020;11(1):105.
DOI: 10.22088/cjim.11.1.105
 9. Özdemir ZC, Kar YD, Ceylaner S, Bör Ö. A novel mutation in the GP1BA gene in Bernard–Soulier syndrome. Blood Coagulation & Fibrinolysis. 2020;31(1):83-86.
DOI: 10.1097/MBC.0000000000000868
 10. Ghalloussi D, Rousset-Rouvière C, Popovici C, Garaix F, Saut N, Sautier P, Baccini V. Bernard-Soulier syndrome: First human case due to a homozygous deletion of GP9 gene. British Journal of Haematology. 2020;188(6).
DOI: 10.1111/bjh.16374
 11. Minkov M, Zeitlhofer P, Zoubek A, Kager L, Panzer S, Haas OA. Novel compound heterozygous mutations in two families with Bernard–Soulier syndrome. Frontiers in Pediatrics. 2021;8:589812.
DOI: 10.3389/fped.2020.589812
 12. Martinez-Navajas G, Ceron-Hernandez J, Simon I, Lupiañez P, Diaz-McLynn S, Perales S, Real PJ. Lentiviral gene therapy reverts GPIX expression and phenotype in Bernard-Soulier syndrome type C. Molecular Therapy-Nucleic Acids, 202333, 75-92.
DOI: 10.1016/j.omtn.2023.06.008

Disclaimer/Publisher's Note: The statements, opinions and data contained in all publications are solely those of the individual author(s) and contributor(s) and not of the publisher and/or the editor(s). This publisher and/or the editor(s) disclaim responsibility for any injury to people or property resulting from any ideas, methods, instructions or products referred to in the content.

© Copyright (2024): Author(s). The licensee is the journal publisher. This is an Open Access article distributed under the terms of the Creative Commons Attribution License (<http://creativecommons.org/licenses/by/4.0>), which permits unrestricted use, distribution, and reproduction in any medium, provided the original work is properly cited.

Peer-review history:
The peer review history for this paper can be accessed here:
<https://www.sdiarticle5.com/review-history/126769>