

# MRI Evaluation of Cervical Spondylotic Canal Stenosis and Change in its Severity on Flexion and Extension Positioning: A Cross-sectional Study

DIVYA VISHWANATHA KINI<sup>1</sup>, TR KAPILAMOORTHY<sup>2</sup>, RUDRESH HIREMATH<sup>3</sup>, ANUPAMA CHANDRAPPA<sup>4</sup>, SACHIN P SHETTY<sup>5</sup>, BALASUBRAMANIAN GURUMURTHY<sup>6</sup>



## ABSTRACT

**Introduction:** Cervical spondylosis is a degenerative disorder of the cervical spine and has varied pathological forms of presentation. It presents as either varying degrees of intervertebral disc bulge, spinal cord compression, altered cord signals, neural exit foraminal stenosis, annular tears, facet joint degeneration and ligamentum flavum hypertrophy in combination or isolation. Magnetic Resonance Imaging (MRI) being known for its excellent soft tissue resolution helps assess and grade these pathologies efficiently.

**Aim:** To evaluate the flexion-extension MRI in regular cervical spondylosis imaging by assessing the effect of flexion and extension positioning on the severity of cervical spondylotic canal stenosis and spinal canal dimensions. Also, to compare the change in cervical canal dimensions on flexion and extension with that of neutral positioning.

**Materials and Methods:** A cross-sectional study was conducted in the Department of Radiodiagnosis, JSS Medical College, Mysuru, Karnataka, India, from January 2021-June 2022. A total of 50 participants, aged above 18 years with a clinical suspicion of cervical spondylosis and without history of trauma, tumour, infection, prior cervical surgery and with Nurick grade <3 were included in the

present study. In all the subjects, spinal canal dimension, degree of stenosis was assessed and graded, further assessment for presence of foraminal stenosis, ligamentum flavum hypertrophy and facet arthropathy were also documented. Data were statistically analysed using Chi-square test and Mc Nemer's test.

**Results:** Out of total 50 cases, 26 (52%) were males and the rest were females with mean age of 46 years. Least cervical canal space dimension of 0.4 cm at C6-7 level in the neutral position and at C3-4, C5-6 and C6-7 levels in extension were noted thus, proving the importance of extension positioning in recognising maximum levels and severity of involvement. Narrowest diameter was demonstrated on flexion and extension. Additionally, the elderly was seen more affected by central disc bulge, foraminal stenosis, facet arthropathy and ligamentum flavum hypertrophy as compared to the middle aged and the younger patients, more so in extension (12%).

**Conclusion:** Disc bulge and grade of stenosis vary extensively and are more conspicuous on additional flexion and extension imaging. Severity of the grade of stenosis and demonstration of maximum number of levels involved on extension as compared to flexion or neutral positioning thereby, benefitting clinical management plan.

**Keywords:** Cervical spine, Disc bulge, Magnetic resonance imaging, Spinal canal

## INTRODUCTION

Cervical spondylosis is a degenerative disorder of the cervical spine and its presence has been noted in 85% individuals, above the age of 60 years with one cervical level being the least involved [1]. It presents as either varying degrees of intervertebral disc bulge, spinal cord compression, altered cord signals, neural exit foraminal stenosis, annular tears, facet joint degeneration and ligamentum flavum hypertrophy in combination or isolation [2]. Elderly individuals are most predisposed to such changes [2]. Clinical presentation and disability levels of affected individuals are varied. Patients present with a varied grade of disability which has been graded by Nurick into six grades (0-5) [3].

Cervical spine is known to have the greatest mobility in the sagittal plane when compared to the rest of the spinal column and hence, more predisposed to the effects of spondylosis [4]. Day-to-day activities involve a varied range of motion in the cervical spine thus, demanding the need for a more dynamic imaging protocol to evaluate the pathology than a static conventional MRI in supine neutral posture. Flexion-extension MRI helps demonstrate previously missed pathologies, accurate identification of levels involved in spondylosis and identify the true nature of the pathology [4].

Zeitoun D et al., have proven the stage of stenosis in extension to be significantly higher when compared to neutral and flexion MRI [5]. Another comparative study by Lee SY et al., has also shown that spinal stenosis, disc abnormality and nerve root compression was much accurately diagnosed with a 3-position MRI technique [6]. Thus, a better presurgical radiological evaluation will help in a better surgical outcome. Additional findings in the form of intramedullary high signal intensities were also noted as per Yukawa Y et al., [7]. In the current Indian scenario, flexion-extension MRI is not routinely practiced as a part of the cervical spondylosis imaging protocol and the study regarding the same are scarce in India. The inclusion of the same is therefore imperative, as analysing the cervical spine with the new additional positional modifications helps in detailed and a more effective assessment of the cervical spine as demonstrated in the present study.

Thus, the present study aims to evaluate the flexion-extension MRI in regular cervical spondylosis imaging by assessing the effect of flexion and extension positioning on the severity of cervical spondylotic canal stenosis and spinal canal dimensions. Also, to compare the change in cervical canal dimensions on flexion and extension with that of neutral positioning.

## MATERIALS AND METHODS

Present cross-sectional study conducted in the Department of Radiodiagnosis at JSS Medical College, Mysuru, Karnataka, India. Duration of the study was, from January 2021- June 2022. This study was approved by the Institutional Ethics Committee's (reference number-JSS/MC/PG5189/2019-20 dated on 14.11.2019).

**Inclusion criteria:** All patients above the age of 18 years, who were referred with a clinical diagnosis of cervical spondylosis and presenting with complaints of neck pain with/without neurogenic symptoms of Nurick grade 0, 1, 2 was included [3].

**Exclusion criteria:** Patients with history of trauma, tumour, infection, prior cervical surgery and with Nurick grade >3 were excluded.

As per the Nurick grading,

Grade 0: Signs or symptoms of root involvement but without evidence of spinal cord disease;

Grade 1: Signs of spinal cord disease but no difficulty in walking;

Grade 2: Slight difficulty in walking which did not prevent full-time employment;

Grade 3: Difficulty in walking which prevented full-time employment or the ability to do all housework, but which was not so severe as to require someone else's help to walk;

Grade 4: Able to walk only with someone else's help or with the aid of a frame;

Grade 5: Chairbound or bedridden [3].

**Sample size calculation:** It was based on the study by Jha SC et al., [8].

Sample size was obtained by the formula- 
$$\frac{(Z\alpha+Z\beta)2 \times S^2 \times 2}{D^2}$$

Where  $Z\alpha$ -Z value for  $\alpha$  level (1.96 for an  $\alpha$  error of 0.05)

$Z\beta$ -Z value for  $\beta$  level (1.28 for an  $\beta$  error of 0.10)

S-Standard deviation

D-Clinically meaningful difference between the two groups.

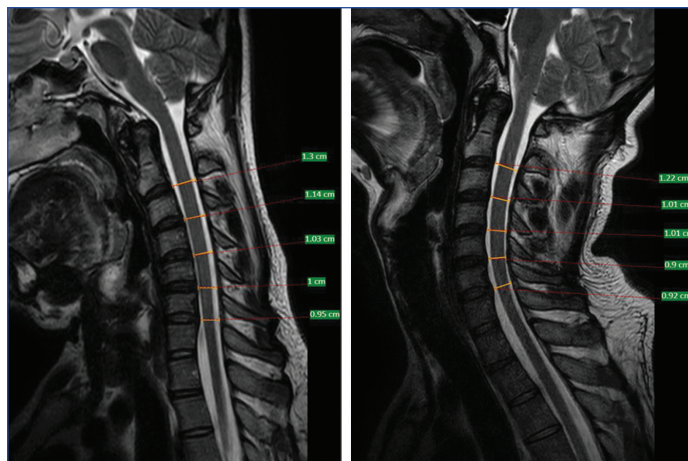
$$\text{i.e., } \frac{(1.96+1.28)2 \times (0.19)^2 \times 2}{(0.15)^2} = 33.68 \sim 34$$

However, study was conducted on 50 patients referred for MRI cervical spine in view of clinically diagnosed cervical spondylosis.

### Study Procedure

Patients were selected, relevant clinical history obtained and further subjected to MR imaging. MRI was performed using a 3.0 Tesla MRI Scanner (PHILIPS INGENIA 3.0 Tesla MRI Scanner) with the use of a 32-channel receive-only head and neck coil. Images were acquired using standard scanning protocols. The scanning protocol included 2D sagittal T1, T2, Short Tau Inversion Recovery (STIR), axial T2 and coronal STIR sequences in the neutral position and additional 2D T2 sagittal and axial sequences in both flexion and extension positioning. The acquired images were transferred to a dedicated workstation (Philips, Ingenuity workstation) for post-processing. Using a Region Of Interest (ROI) based approach spinal canal diameters were measured and graded [8]. Assessment for cord compression and signal changes, foraminal stenosis, ligamentum flavum hypertrophy and facet joint arthropathy at all subaxial levels in the cervical spine in neutral, flexion and extension positions was done. The parameters were assessed as follows:

- **Cervical spinal canal diameter:** was measured as mentioned earlier [Table/Fig-1,2]. This was further graded into grade 0-3 i.e., grade 0: refers to the absence of central canal stenosis; grade 1 refers to nearly complete obliteration of subarachnoid space, including obliteration of the arbitrary subarachnoid space exceeding 50%, without signs of cord deformity; grade 2 refers to central canal stenosis with cord deformity but without spinal cord signal change; grade 3 refers to the presence of



**[Table/Fig-1]:** Sagittal T2WI image with neck in flexion depicting the canal space dimension measurement. **[Table/Fig-2]:** Sagittal T2WI image with neck in flexion depicting the canal space dimension measurement. (Images from left to right).

spinal cord signal change near the compressed level on T2-weighted images [9].

- **Cord compression:** was determined by the presence of disc bulge and resultant canal stenosis compression on the cord causing change in contour on both sagittal and axial planes. Assessment was also made in comparison to the outline of the cord above and below the level of compression. In association, the presence of cord compression was associated with intrinsic signal change imaged as T2/Fluid-attenuated Inversion Recovery (FLAIR) hyperintensity within the involved cord segment.
- **Foraminal stenosis:** was assessed by the presence of disc bulge resulting in narrowing of the neural foramina corroborated on axial and sagittal planes. This was evidenced by the presence of effacement/loss of fat in the perineural region of the foramina and by indentation/impingement of the cord with resultant change in morphology [10].
- **Ligament flavum hypertrophy:** was considered when the thickness of the same was measured bilaterally and found to be more than or equal to 2 mm [11].
- **Facet joint arthropathy:** was imaged as presence of reduced facet joint space, articular surface irregularity, osteophytes and hypertrophy [12].

The patients were further divided into age groups of 20-35 years (group 1), 36-50 years (group 2) and above 50 (group-3) and above described pathologies assessed.

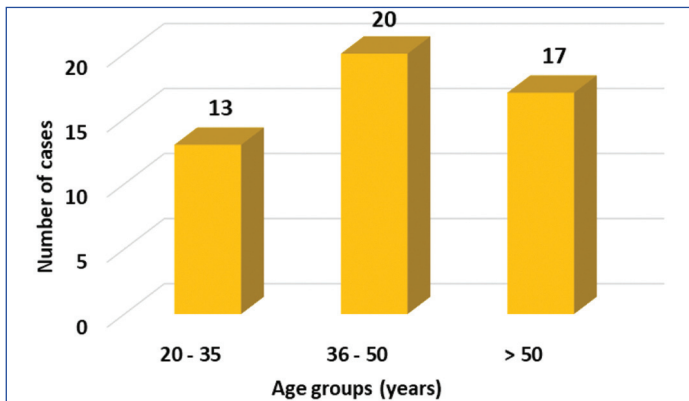
### STATISTICAL ANALYSIS

Data was entered in the Microsoft Excel sheet and statistical analysis was done using IBM Statistical Package for Social Sciences (SPSS) Statistics version 20.0 (IBM corp. released 2011). Data was subjected to normalcy test (Shapiro-wilk test). Data showed non normal distribution. Hence, nonparametric tests (Wilcoxon signed test) were applied. Further, Chi-square test and Mc Nemer's test was computed for qualitative variables.

### RESULTS

A total of 50 patients were assessed. Each patient was subjected to flexion, extension and neutral positioning and the subaxial cervical spinal levels were assessed i.e., C2-3, C3-4, C4-5, C5-6 and C6-7 intervertebral discs summing upto 250 levels in total. In present study, 26 (52%) cases were males and the rest were females. Least cervical canal space dimension of 0.4 cm at C6-7 level in the neutral position and at C3-4, C5-6 and C6-7 levels in extension were noted 26 (52%) cases were males and the rest were females. Patients ranged from the ages of 23 to 73 with an average of

46±13.02 years. 13 (26%) patients belonged to group 1, 20 (40%) patients belonged to group 2 and 17 (34%) in group 3 [Table/Fig-3]. Least dimension of spinal canal was documented at C5-6 levels in all position and at C2-3, C3-4, C4-5, C5-6 and C6-7 levels on extension positioning. On comparing the parameters in each position statistically significant difference was obtained [Table/Fig-4,5]. Upon assessment of the disc bulge and its association with age groups, grade 1 bulge was noted maximally in neutral position followed by flexion and extension position, more so, in those belonging to 36-50 years age group. However, grade 3 stenosis was maximum cases in the >50 year age group [Table/Fig-6].



**[Table/Fig-3]:** Bar chart illustrating the age wise distribution of cases into three predefined groups viz., 20-35 years (young), 36-50 years (middle aged), >50 years (elderly).

Mean spinal canal dimensions (cm)				p-value	
	Flexion	Extension	Neutral		
Cervical subaxial disc levels	C2-3	1.17±0.16	1.13±0.23	2.52±0.20	<0.01
	C3-4	1.02±0.18	0.95±0.21	1.01±0.18	
	C4-5	1±0.18	0.92 ±0.21	0.98±0.18	
	C5-6	0.95±0.95	0.85±0.23	0.93±0.21	
	C6-7	0.96±0.20	0.89±0.21	0.96±0.22	

**[Table/Fig-4]:** Tabular representation of the average spinal canal dimensions at each subaxial cervical intervertebral disc levels.

Neck positioning	Subaxial cervical intervertebral disc levels	p-value
Flexion vs Extension	C2-C3	0.194
	C3-C4	<0.001*
	C4-C5	<0.001*
	C5-C6	<0.001*
	C6-C7	<0.001*
Flexion vs Neutral	C2-C3	0.989
	C3-C4	0.564
	C4-C5	0.173
	C5-C6	0.130
	C6-C7	0.772
Extension vs Neutral	C2-C3	0.148
	C3-C4	<0.001*
	C4-C5	<0.001*
	C5-C6	<0.001*
	C6-C7	<0.001*

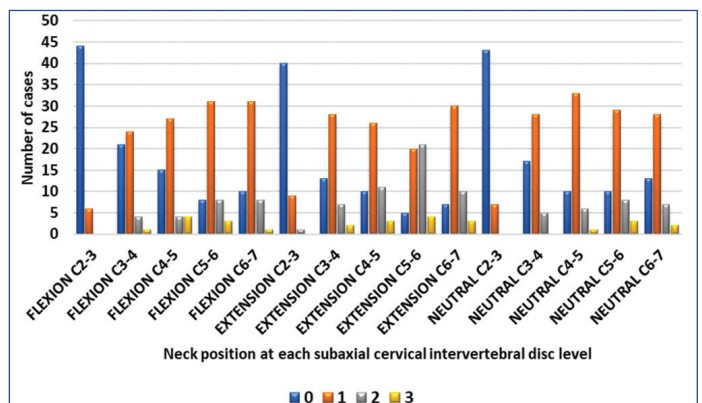
**[Table/Fig-5]:** Tabular representation depicting the p-value upon comparing the canal space narrowing at each subaxial intervertebral disc level on flexion, extension and neutral positioning. \*Significant

Grading of spinal canal stenosis was done at all levels, ranging from 0 to 3 i.e., widest to narrowest spinal canal diameter. Severe grades of stenosis were obtained maximally at the C5-6 levels in all the neck positions- flexion, extension and neutral. Of these, maximum

	Position	Grade of disc bulge	n (%)			p-value
			20-35 years	36-50 years	>50 years	
Disc bulge	Flexion	0	4 (8)	0	0	0.001
		1	8 (16)	12 (24)	10 (20)	
		2	1 (2)	6 (12)	3 (6)	
		3	0	2 (4)	4 (8)	
	Extension	0	4 (8)	0	1 (2)	0.015
		1	7 (14)	10 (20)	4 (8)	
		2	2 (4)	8 (16)	8 (16)	
		3	0	2 (4)	4 (8)	
	Neutral	0	6 (12)	0	0	0.001
		1	4 (8)	13 (26)	8 (16)	
		2	3 (6)	6 (12)	6 (12)	
		3	0	1 (2)	3 (6)	

**[Table/Fig-6]:** Tabular representation of the association of percentage distribution of cases with disc bulge in each age group and cervical spine position. Wilcoxon signed test was applied followed by Chi-square test and Mc Nemer's test for qualitative variables.

stenosis was derived on extending the neck at the C5-6 level [Table/Fig-7]. Cord compression was observed at multiple levels with some being severe in nature resulting in cord signal change. These features were maximally noted on extension as compared to flexion and neutral [Table/Fig-8].



**[Table/Fig-7]:** Bar graph demonstrating the number of cases (y-axis) demonstrating various grades (x-axis; blue: grade 0, orange: grade 1, grey: grade 2, yellow: grade 3) of stenosis in flexion, extension and neutral positioning.

Variables	Level	Flexion n (%)	Extension n (%)	Neutral n (%)
Cord compression	C2-C3	1 (2)	1 (2)	0
	C3-C4	1 (2)	4 (8)	2 (4)
	C4-C5	4 (8)	8 (16)	2 (4)
	C5-C6	9 (18)	11 (22)	6 (12)
	C6-C7	4 (8)	11 (22)	4 (8)
Cord signal	C2-C3	0	0	0
	C3-C4	3 (6)	4 (8)	1 (2)
	C4-C5	4 (8)	5 (10)	3 (6)
	C5-C6	6 (12)	6 (12)	6 (12)
	C6-C7	3 (6)	5 (10)	5 (10)

**[Table/Fig-8]:** Tabular representation of the percentage distribution of cases with cord compression and cord signal change and the corresponding cervical spine position.

Similarly, foraminal stenosis was present at all intervertebral disc levels except C2-C3 level with maximum number of foramina were involved at the C5-C6 level, more so in the extension position. Ligamentum flavum hypertrophy was seen as a secondary aetiological factor resulting in canal compression/stenosis in addition to disc bulge thereby causing symptomatic pain. Maximum

cases with thickening of ligamentum flava were at the C6-C7 level in the extension position [Table/Fig-9]. Though, higher number of patients demonstrated foraminal stenosis in the elderly age group, no statistical significance was obtained. On flexion, upto 6 (12%) of elderly patients showed Ligamentum Flavum Haematoma (LFH) while 11 (22%) did not ( $p$ -value=0.021). On extension, most patients did not display LFH. Of those who did, maximum (14%) belonged to the elderly age group ( $p$ -value=0.016) [Table/Fig-10].

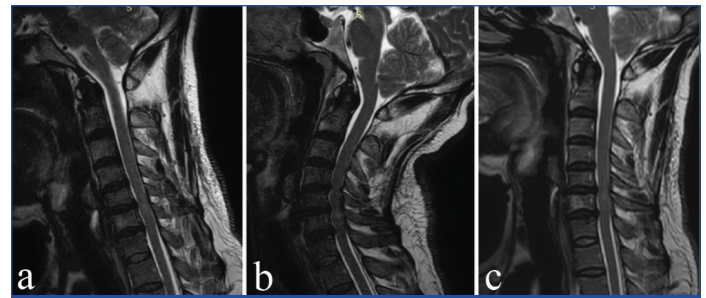
Variables	Level	Flexion n (%)	Extension n (%)	Neutral n (%)
Femoral stenosis	C2-C3	0	0	0
	C3-C4	6 (12)	12 (24)	6 (12)
	C4-C5	14 (28)	17 (34)	12 (24)
	C5-C6	18 (36)	22 (44)	18 (36)
	C6-C7	12 (24)	18 (36)	12 (24)
Ligamentum flavum hypertrophy	C2-C3	0	0	0
	C3-C4	2 (4)	2 (4)	3 (6)
	C4-C5	3 (6)	6 (12)	4 (8)
	C5-C6	5 (10)	7 (14)	5 (10)
	C6-C7	7 (14)	9 (18)	6 (12)

**[Table/Fig-9]:** Tabular representation of the percentage distribution of maximum number of involved cases with foraminal stenosis and ligamentum flavum hypertrophy and the corresponding cervical spine position.

Variables	Position	Grade	n (%)			p-value
			20-35 years	36-50 years	>50 years	
Foraminal stenosis	Flexion	Absent	7 (14)	9 (18)	10 (20)	0.69
		Present	6 (12)	11 (22)	7 (14)	
	Extension	Absent	6 (12)	9 (18)	8 (16)	0.99
		Present	7 (14)	11 (22)	9 (18)	
	Neutral	Absent	6 (12)	9 (18)	10 (20)	0.66
		Present	7 (14)	11 (22)	7 (14)	
Ligamentum flavum hypertrophy	Flexion	Absent	13 (26)	18 (36)	11 (22)	0.021
		Present	0	2 (4)	6 (12)	
	Extension	Absent	13 (26)	17 (34)	10 (20)	0.016
		Present	0	3 (6)	7 (14)	
	Neutral	Absent	13 (26)	17 (34)	11 (22)	0.04
		Present	0	3 (6)	6 (12)	
Facet joint arthropathy	Flexion	Absent	13 (26)	18 (36)	12 (24)	0.057
		Present	0	2 (4)	5 (10)	
	Extension	Absent	13 (26)	18 (36)	11 (22)	0.021
		Present	0	2 (4)	6 (12)	
	Neutral	Absent	13 (26)	18 (36)	12 (24)	0.057
		Present	0	2 (4)	5 (10)	

**[Table/Fig-10]:** Tabular representation of the association of percentage distribution of cases with foraminal stenosis, ligamentum flavum hypertrophy and facet joint arthropathy in each age group and cervical spine position (Wilcoxon signed test was applied followed by Chi-square test and Mc Nemer's test for qualitative variables).

Facet joint involvement in the form of hypertrophy, osteophytes, subchondral erosions and articular surface irregularities with joint space fluid was noted as facet joint arthropathy and the change in the frequency of identification of this pathology was compared on flexion, extension and neutral positioning. A slightly higher number of facet arthropathic changes were appreciated on extension when compared to neutral and flexion, maximally at the C5-6 level. A relatively higher percentage of elderly patients showed features of facet arthropathy that were better expressed on extension imaging 6 (12%). However, no statistical significance was obtained [Table/Fig-10]. The pathological findings of cervical spondylosis in a 45-year-old male presenting with neck pain for three years are depicted in [Table/Fig-11].



**[Table/Fig-11]:** A 45-year-old male with neck pain in the last three years with increase in symptoms since past six months with radiating pain to bilateral upper limbs- T2WI sagittal images on neutral (a), flexion (b) and extension (c) positioning depicting the posterior disc bulge at C5-6 and C6-7 levels with intramedullary T2 hyperintensity (myelomalacia) and corresponding increase in degree and levels of disc bulge on extension as compared to neutral and flexion.

## DISCUSSION

Cervical spondylosis is a clinical entity that is commonly encountered in day-to-day practice. It needs a thorough understanding of its pathogenesis, available efficacious diagnostic techniques and effective treatment modalities. Extension and Flexion are movements that are initiated physiologically at the lower cervical spine [13]. Of the intervertebral levels, maximal mobility is seen to occur at the C5-C6 level and least at the C2-C3 level [14]. The canal tends to be longer on flexion as compared to extension with the antero posterior diameter known to reduce in extension and mildly increase in flexion [15,16]. However, a sagittal canal diameter of  $\leq 10$  mm at C7 level was considered as a landmark, below which the occurrence of dynamic cord impingement on further extension tends to rise [17]. Jha SC et al., in their study estimated the average length of the spinal cord, length of the cervical spinal anterior column and length of the cervical spinal posterior column [8]. Their study showed a significant decrease in all of these parameters at each level in extension when compared to flexion. Also, higher grades of cervical canal stenosis were noted in extension when compared to flexion with statistically significant differences.

In the present study, a similar pattern of results was obtained, grades of stenosis were the highest (maximum stenosis) in extension. Also, significant difference was noted between the grades of canal stenosis on extension than compared to neutral and flexion. Maximum grades of stenosis were obtained at C5-6 intervertebral level on extension. This therefore, validates the need for additional incorporation of this positioning as a part of regular imaging protocol. A study has also shown that, MRI is a better imaging modality when compared to conventional plain radiography. MRI helped in better additional assessment of the disc, ligaments and surrounding soft tissues [18]. Further, it was seen that on dynamic MRI, spinal canal widening was significantly higher with a difference of about 1.99 mm between flexion and extension positioning. Also, accurate assessment of the total number of levels involved was found to be better on extension than flexion and neutral positioning [19]; similar findings were obtained in present study as well. Recent studies, such as that by Lee SY et al., have also shown similar findings as the above mentioned studies [20]. Here, the total cervical spine stenosis score, defined as the sum of the individual score at each level, was found to be significantly higher when in extension than neutral as well as higher in neutral position when compared to flexion. However, supine positioning of the patient was one of the limitations of their study as suggested by the authors.

In the present study, a similar assessment was performed and the authors obtained least cervical canal space dimension at C6-7 level in the neutral position and at C3-4, C5-6 and C6-7 levels in extension position. Also, narrowest diameter (i.e., corresponding to highest grades) was demonstrated on flexion and extension, significantly more so in extension. Extension positioning yielded

a narrower canal, higher grade of stenosis and more severe and better appreciated ligamentum hypertrophy as well as the foraminal stenosis on extension. Extension MRI has been shown to help assess the true number of levels as well as the degree of narrowing of the spinal canal [18]. Furthermore, assessment of presence of intramedullary high signal intensity necessitates the use of flexion MRI preoperatively as well. This is explained by flexion of the neck that results in increasing the spinal canal diameter thereby, improving estimation and visualisation of the degree of pathology. In the present study, the differing extent and severity of cord compression and resultant signal change on different neck was illustrated and obtained contradicting results as compared to the afore mentioned studies. The better visualisation and analysis of cord compression on extension positioning at C3-4 and C4-5 levels was observed. At C5-6, cord compression was equally demonstrable on flexion, extension and neutral. At C6-7 levels, extension and neutral were found to be equally helpful. Maximum depiction of cord signal changes was seen on extension, mainly at the C5-6 and C6-7 levels. At the C2-3 level, flexion positioning was found to be equally beneficial in detecting and accentuating the findings.

Additional contributory factors which play a causative role in cervical spinal canal stenosis such as ligamentum flavum hypertrophy were assessed. Significant flaval hypertrophy was noted at the C6-7 level on extending the neck. Sayit E et al., performed a study to assess the change in ligamentum flavum thickness on kinematic MRI in extension, flexion and neutral [21]. They obtained findings corroborative with the present study wherein, the ligamentum flavum was found to be thicker on extension as compared to flexion. Additionally, the ligamentum flavum at the C6-7 and the C7-T1 level is known to be inherently thick on extension position. This was attributed to result in symptomatic neural and cord compression. A total of 40 patients showed facet arthropathic changes of which maximal cases were demonstrated on extension maximally at the C5-6 level. Kinetic MRI has been analysed for its benefits in assessment of the lumbar spine and its use regularised [22]. Radiographic examination with flexion and extension has been a much practiced maneuver for the assessment of degenerative pathologies of the cervical spine, however, the inclusion of this modification for the assessment of the cervical spine during MR imaging is not as prevalent in the current Indian scenario. As detailed earlier, all of the 50 patients were divided into three clinically relevant age groups. Disc bulge was seen predominantly in the middle aged and elderly patients with higher grades seen in the elderly. Similarly, ligamentum flavum hypertrophy and facet joint arthropathy was seen to affect the elderly, more so on extension. The middle-aged and young patients were affected largely by disc bulge, predominantly on flexing. Thus, avoiding excessive extension of the cervical spine may benefit the elderly patients while obviating activities involving excessive flexion at the neck may be supportive in avoiding symptoms in the middle aged and young patients. This interpretation, as per the authors assessment, helps clinicians and patients themselves to be aware of the dynamic worsening of cervical spondylotic symptoms and hopefully advice avoidance of activities exaggerating such neck positions. As per the knowledge, there is very scarce literature, where such correlation has been provided.

### Limitation(s)

The accurate assessment of the obtained results and further generalisation to the normal population cannot be done. Though, normative data was taken into account, certain extent of change in canal space dimension, foraminal stenosis and ligamentum flavum hypertrophy is physiological on dynamic motion of the spinal cord. This needs to be considered as a part of assessment to avoid unnecessary false positive results.

## CONCLUSION(S)

The severity of disc bulge and grade of stenosis vary significantly challenging the ability of the diagnostic modalities to depict the pathology in totality. Addition of the flexion-extension projections in the imaging protocol of MRI evaluation was noted to be beneficial in delineating the actual extent and severity of spondylosis. These imaging findings also contributed in the clinical management by demonstrating the physical posture which worsened the compression. However, larger population-based studies have to be performed for further validation of the data.

## REFERENCES

- [1] Matsumoto M, Fujimura Y, Suzuki N, Nishi Y, Nakamura M, Yabe Y, et al. MRI of cervical intervertebral discs in asymptomatic subjects. *J Bone Joint Surg Br.* 1998;80(1):19-24. Doi: 10.1302/0301-620x.80b1.7929. PMID: 9460946.
- [2] Kalsi-Ryan S, Karadimas SK, Fehlings MG. Cervical spondylotic myelopathy: the clinical phenomenon and the current pathobiology of an increasingly prevalent and devastating disorder. *Neuroscientist.* 2013;19(4):409-21. Doi: 10.1177/1073858412467377. Epub 2012 Nov 30. PMID: 23204243.
- [3] Nurick S. The pathogenesis of the spinal cord disorder associated with cervical spondylosis. *Brain.* 1972;95(1):87-100. Doi: 10.1093/brain/95.1.87. PMID: 5023093.
- [4] Brain WR, Northfield D, Wilkinson M. The neurological manifestations of cervical spondylosis. *Brain.* 1952;75(2):187-225. Doi: 10.1093/brain/75.2.187. PMID: 14934989.
- [5] Zeitoun D, El Hajj F, Soriali E, Catonné Y, Pascal-Moussellard H. Evaluation of spinal cord compression and hyperintense intramedullary lesions on T2-weighted sequences in patients with cervical spondylotic myelopathy using flexion-extension MRI protocol. *Spine J.* 2015;15(4):668-74. Doi: 10.1016/j.spinee.2014.12.001. Epub 2014 Dec 5. PMID: 25485484.
- [6] Lee SY, Hur JW, Ryu KS, Kim JS, Chung HJ, Song MS. The clinical usefulness of preoperative imaging studies to select pathologic level in cervical spondylotic myelopathy: comparative analysis of three-position MRI and post-myelographic CT. *Turk Neurosurg.* 2019;29(1):127-33. Doi: 10.5137/1019-5149.JTN.23249-18.1. PMID: 30614510.
- [7] Yukawa Y, Kato F, Yoshihara H, Yanase M, Ito K. MR T2 image classification in cervical compression myelopathy: predictor of surgical outcomes. *Spine (Phila Pa 1976).* 2007;32(15):1675-78; discussion 1679. Doi: 10.1097/BRS.0b013e318074d62e. PMID: 17621217.
- [8] Jha SC, Miyazaki M, Tsumura H. Kinetic change of spinal cord compression on flexion-extension magnetic resonance imaging in cervical spine. *Clin Neurol Neurosurg.* 2018;174:86-91. Doi: 10.1016/j.clineuro.2018.09.017. Epub 2018 Sep 10. PMID: 30219623.
- [9] Kang Y, Lee JW, Koh YH, Hur S, Kim SJ, Chai JW, et al. New MRI grading system for the cervical canal stenosis. *AJR Am J Roentgenol.* 2011;197(1):W134-40. Doi: 10.2214/AJR.10.5560. PMID: 21700974
- [10] Park HJ, Kim SS, Lee SY, Park NH, Chung EC, Rho MH, et al. A practical MRI grading system for cervical foraminal stenosis based on oblique sagittal images. *Br J Radiol.* 2013;86(1025):20120515. DOI: 10.1259/bjr.20120515. Epub 2013 Feb 14. PMID: 23410800; PMCID: PMC3635796
- [11] Jeong HW, Yi J, Lee S, Park S, Kang KN, Lee J, et al. Prognostic value of cervical ligamentum flavum thickness as a morphological parameter to predict cervical stenosis. *Medicine.* 2021;100(34):e27084. Doi: 10.1097/MD.00000000000027084
- [12] Kim JH, Sharan A, Cho W, Emam M, Hagen M, Kim SY. The prevalence of asymptomatic cervical and lumbar facet arthropathy: a computed tomography study. *Asian Spine J.* 2019;13(3):417-22. Doi: 10.31616/asj.2018.0235. Epub 2019 Feb 13. PMID: 30744307; PMCID: PMC6547401.
- [13] Swartz EE, Floyd RT, Cendoma M. Cervical spine functional anatomy and the biomechanics of injury due to compressive loading. *J Athl Train.* 2005;40(3):155-61. PMID: 16284634; PMCID: PMC1250253.
- [14] Penning L. Normal movements of the cervical spine. *AJR Am J Roentgenol.* 1978;130(2):317-26. Doi: 10.2214/ajr.130.2.317. PMID: 414586.
- [15] McCracken B, Klineberg E, Pickard B, Wisner DH. Flexion and extension radiographic evaluation for the clearance of potential cervical spine injuries in trauma patients. *Eur Spine J.* 2013;22(7):1467-73. Doi: 10.1007/s00586-012-2598-z. Epub 2013 Feb 13. PMID: 23404352; PMCID: PMC3698361.
- [16] Nigro L, Donnarumma P, Tarantino R, Rullo M, Santoro A, Delfini R. Static and dynamic cervical MRI: two useful exams in cervical myelopathy. *J Spine Surg.* 2017;3(2):212-16. Doi: 10.21037/jss.2017.06.01. PMID: 28744502; PMCID: PMC5506301.
- [17] Bartlett RJ, Hill CA, Rigby AS, Chandrasekaran S, Narayanamurthy H. MRI of the cervical spine with neck extension: is it useful? *Br J Radiol.* 2012;85(1016):1044-51. Doi: 10.1259/bjr/94315429. Epub 2012 Jan 3. PMID: 22215879; PMCID: PMC3587072.
- [18] Dalbayrak S, Yaman O, Firdin MN, Yilmaz T, Yilmaz M. The contribution of cervical dynamic magnetic resonance imaging to the surgical treatment of cervical spondylotic myelopathy. *Turk Neurosurg.* 2015;25(1):36-42. Doi: 10.5137/1019-5149.JTN.9082-13.1. PMID: 25640543.

- [19] Zhang L, Zeitoun D, Rangel A, Lazennec JY, Catonné Y, Pascal-Moussellard H. Preoperative evaluation of the cervical spondylotic myelopathy with flexion-extension magnetic resonance imaging: about a prospective study of fifty patients. *Spine (Phila Pa 1976)*. 2011;36(17):E1134-39. Doi: 10.1097/BRS.0b013e3181f822c7. PMID: 21785299.
- [20] Lee Y, Kim SY, Kim K. A dynamic magnetic resonance imaging study of changes in severity of cervical spinal stenosis in flexion and extension. *Ann Rehabil Med*. 2018;42(4):584-90. Doi: 10.5535/arm.2018.42.4.584. Epub 2018 Aug 31. PMID: 30180528; PMCID: PMC6129716.
- [21] Sayit E, Daubs MD, Aghdasi B, Montgomery SR, Inoue H, Wang CJ, et al. Dynamic changes of the ligamentum flavum in the cervical spine assessed with kinetic magnetic resonance imaging. *Global Spine J*. 2013;3(2):69-74. Doi: 10.1055/s-0033-1337121. Epub 2013 Mar 19. PMID: 24436854; PMCID: PMC3854599.
- [22] Michelini G, Corridore A, Torlone S, Bruno F, Marsecano C, Capasso R, et al. Dynamic MRI in the evaluation of the spine: state of the art. *Acta Biomed*. 2018;89(1-S):89-101. Doi: 10.23750/abm.v89i1-S.7012. PMID: 29350639; PMCID: PMC6179074

**PARTICULARS OF CONTRIBUTORS:**

1. Senior Resident, Department of Radiology, JSS Medical College, Mysore, Karnataka, India.
2. Professor, Department of Radiology, JSS Medical College, Mysore, Karnataka, India.
3. Professor, Department of Radiology, JSS Medical College, Mysore, Karnataka, India.
4. Assistant Professor, Department of Radiology, JSS Medical College, Mysore, Karnataka, India.
5. Assistant Professor, Department of Radiology, JSS Medical College, Mysore, Karnataka, India.
6. Assistant Professor, Department of Radiology, JSS Medical College, Mysore, Karnataka, India.

**NAME, ADDRESS, E-MAIL ID OF THE CORRESPONDING AUTHOR:**

Divya Vishwanatha Kini,  
119, Mahamaya Krupa, 12<sup>th</sup> Cross, 4<sup>th</sup> Main, Jayanagar, Mysore, Karnataka, India.  
E-mail: drkinidivya@gmail.com

**PLAGIARISM CHECKING METHODS:** [Jain H et al.]

- Plagiarism X-checker: Aug 07, 2022
- Manual Googling: Jan 21, 2023
- iThenticate Software: Mar 16, 2023 (11%)

**ETYMOLOGY:** Author Origin**AUTHOR DECLARATION:**

- Financial or Other Competing Interests: None
- Was Ethics Committee Approval obtained for this study? Yes
- Was informed consent obtained from the subjects involved in the study? Yes
- For any images presented appropriate consent has been obtained from the subjects. Yes

Date of Submission: **Aug 02, 2022**Date of Peer Review: **Nov 15, 2022**Date of Acceptance: **Mar 25, 2023**Date of Publishing: **May 01, 2023**