



# Complex Lisfranc Fracture: Bidirectional Cuneiform Dislocation with Successful Closed Reduction: A Case Report

Timothy K. Summers<sup>1\*</sup>, Benjamin D. Sookhoo<sup>1\*</sup>, Robert Shelley<sup>1</sup>  
and William Rosenblum<sup>1</sup>

<sup>1</sup>Department of Orthopaedic Surgery, Medical College of Georgia at Augusta University, Georgia.

## **Authors' contributions**

*This work was carried out in collaboration among all authors. All authors read and approved the final manuscript.*

## **Article Information**

### Editor(s):

(1) Dr. Ikem, Innocent Chiedu, Professor, Department of Orthopaedic Surgery and Traumatology, Obafemi Awolowo University, Ile-Ife Nigeria.

### Reviewers:

- (1) Dr. Mohit Kumar Patralekh, GGS IP University, India.  
(2) Motsitsi Nkosana, University of Pretoria, South Africa.  
(3) Dr. K. Ramesh Kumar, K. N. R. University of Health Sciences, India.  
(4) Xing Wu, Tongji University, China.  
Complete Peer review History: <http://www.sdiarticle3.com/review-history/48589>

**Case Study**

**Received 02 February 2019**

**Accepted 11 April 2019**

**Published 18 April 2019**

## **ABSTRACT**

**Aim:** Lisfranc fractures with cuneiform displacement are rare, commonly involving only a single cuneiform dislocation. Literature is limited in multi-cuneiform fracture dislocations. This case report elaborates on treatment of a Lisfranc injury with concurrent dorsomedial and plantar dislocations of the medial and intermediate cuneiforms, respectively.

**Presentation of Case:** A 35-year-old male was diagnosed with a Lisfranc fracture with bidirectional dislocation of the medial and intermediate cuneiforms following a motor vehicle accident. The injury was reduced successfully with manual retraction, midfoot manipulation, and Kirschner wire fixation in the operating studio.

**Discussion / Conclusion:** Closed reduction and percutaneous pinning are sufficient for reduction in this injury, decreasing morbidity and complications associated with open reduction. Given the nature of our approach, and the distinctiveness of this particular Lisfranc variant, we offer an original methodology to expand on existing literature.

**Keywords:** Lisfranc injury; lisfranc fracture; cuneiform dislocation; medial cuneiform; intermediate cuneiform.

## 1. INTRODUCTION

Lisfranc fractures—aptly named after French surgeon, Jacques Lisfranc de St. Martin (1790-1847), who served in the Napoleonic war in 1815, relieving soldiers plagued with gangrenous injuries by performing amputations at the level of the tarsometatarsal joint (TMTJ)—are rare foot injuries that comprise a small portion (0.2%) of all fractures [1-5]. Two well-established causalities for Lisfranc injuries exist: direct trauma to the dorsal foot [6] or indirect trauma by way of rotational or axial loads applied to a plantarly flexed, inverted foot [1-2,4-5,7-8]. Literature review suggests that Lisfranc injuries are two to four times more prevalent in males, particularly around 30 years of age [1,7,9]. While this injury is uncommon, a Lisfranc injury compounded by cuneiform dislocation adds further to infrequency. Both are suggested to occur at an interval of one patient per 55,000 every year [2,8,10-11].

Although rare, dislocations of cuneiforms, with or without a Lisfranc fracture, are increasingly being reported [8]. There exists great variation among cases ranging from medial and dorsal dislocations of the first cuneiform [11-12], plantar and dorsal dislocations of the intermediate cuneiform [4,6,9,13-17] with the former often developing secondarily to direct, crushing type injuries [6,9,16-17], and plantar and dorsal dislocations of the lateral cuneiform [18]. The lack of literature describing Lisfranc injuries with concomitant multi-cuneiform displacement suggests that dislocation of more than one cuneiform per injury incident is even more obsolete. *Bulut G. et al* describe such an event, a Lisfranc variation in which plantar dislocations of both the medial and intermediate cuneiforms and dorsal dislocation of the lateral cuneiform accompanied the injury, and per their account, it is the first reported case [19]. We believe our report, also a unique variant exhibiting bidirectional cuneiform dislocation, to be the only documented case of this pattern. Adding further distinction is our method of closed reduction, particularly provided the severity of the injury, whereas most authors yield to an open reduction internal fixation (ORIF) approach [4,6,9,11,14,16-20]. Fewer closed reductions are reported and typically involve a single cuneiform dislocation [10,12,13,15].

## 1.1 Statement of Informed Consent

Patient was informed, and verbal consent obtained for publication of this study.

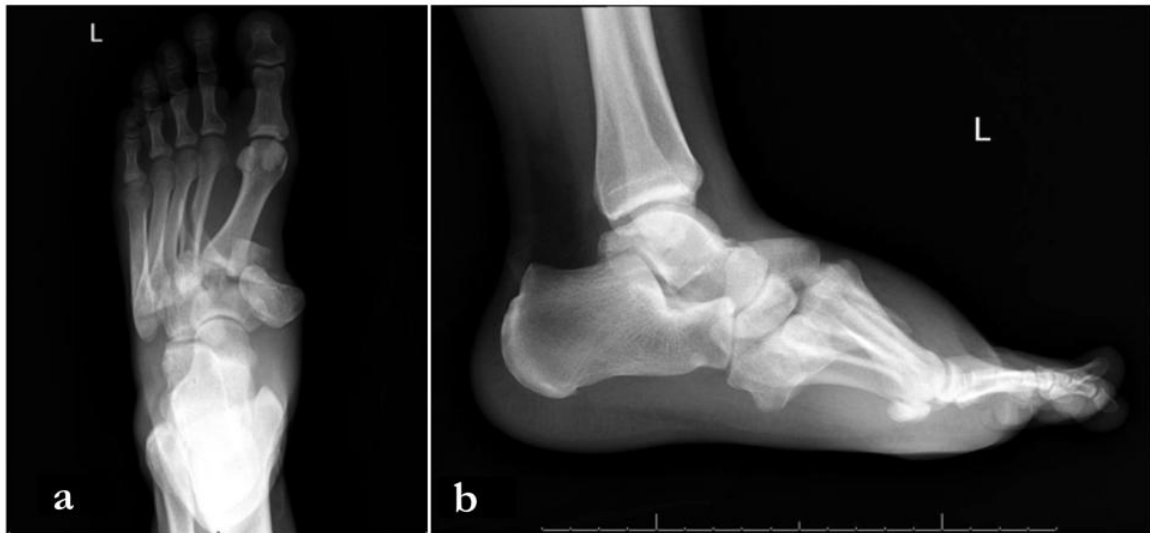## 2. CASE REPORT

The patient is a 35-year-old active duty male with no prior medical history who presented as a level one trauma to the Augusta University Emergency Department following a motor vehicle accident as an unrestrained patient versus brick wall. Immediately following the incident, he ambulated a distance of two blocks before transport to the emergency room. Upon arrival, left lower extremity pain was his major complaint. 14-point cursory review of systems was otherwise negative for constitutional symptoms, respiratory, cardiovascular, neurologic, psychiatric, or other musculoskeletal pathology. Exam revealed obvious deformity of the left midfoot with tenting and pallor of the overlying skin. Impressive midfoot edema was also readily apparent with inability to move toes secondary to pain. Left posterior tibial pulse was palpated, however, left dorsalis pedis pulse could not be appreciated. Biphasic dopplerable pulses of posterior tibial and peroneal arteries, without signal of dorsalis pedis artery, were observed. Toes were warm and well-perfused with brisk capillary refill, and extremity compartments were soft and compressible. Plain radiographs and computed tomography scans (CAT scan) (Fig. 1 and Fig. 2, respectively) demonstrated a Lisfranc injury similar to that of the B2 type (Hardcastle classification [1982]) [2,15], showing homolateral dislocations of the metatarsal relative to the tarsal bones (Quenu and Kuss [1909]) [2,15]; however, there was evident involvement of the first metatarsal precluding classification as a true B2 type. Notably, this injury included a dorsomedially dislocated medial cuneiform and plantarly dislocated intermediate cuneiform.

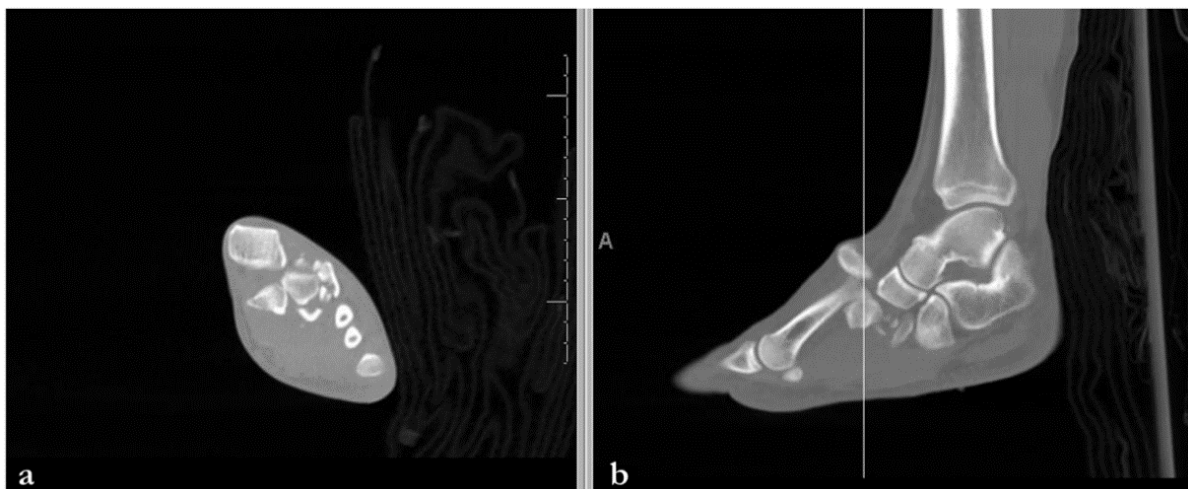
Prior to surgery, the patient was positioned supine with bony prominences padded and a non-sterile tourniquet applied to the left thigh. Following induction of anesthesia, sterile preparation, draping, and exsanguination of the left leg was performed. The Lisfranc dislocation was reduced under manual retraction of the hallux with a plantarly directed force over the foot dorsum reducing the dorsomedially displaced medial cuneiform. Next, reduction of the middle cuneiform was achieved by flexing the second

tarsometatarsal joint over a surgical mallet, increasing the joint interval. A dorsally directed force over the deformity provided reduction in a supinated forefoot. A 2.0 mm Kirschner wire was placed in a medial-to-lateral fashion stabilizing all three cuneiforms immediately followed by retrograde placement of a second wire from first metatarsal to medial cuneiform. A weber clamp was then used to further reduce and stabilize the Lisfranc joint. A third and final wire was placed medial to lateral through the 1<sup>st</sup>-3<sup>rd</sup> metatarsal bases, and reduction was confirmed with AP and

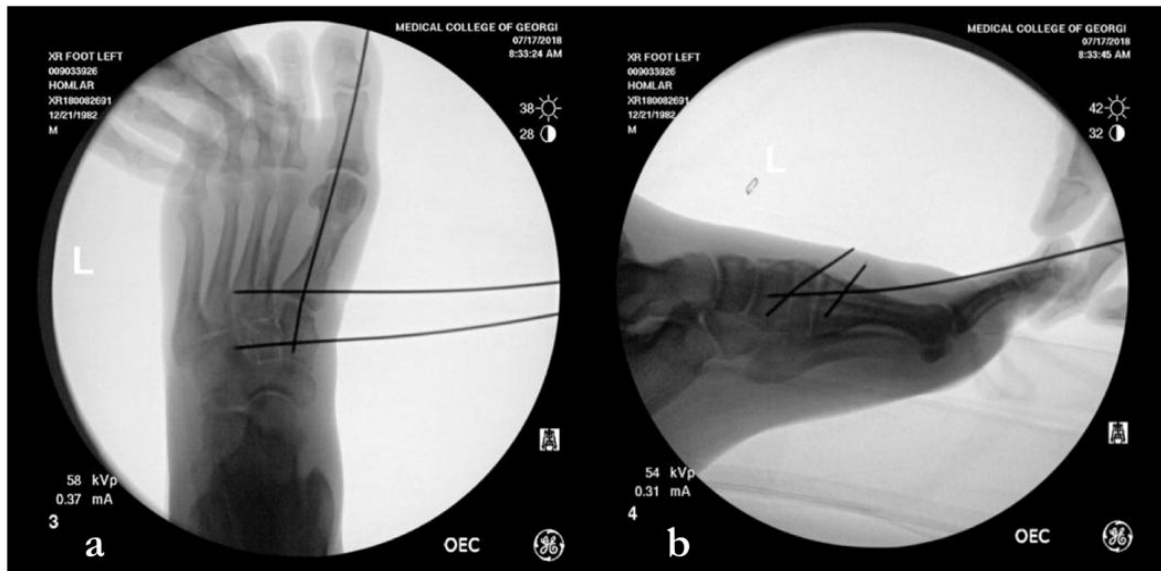
lateral X-ray views (Fig. 3). After tourniquet release, posterior tibial and dorsalis pedis pulses were confirmed through palpation and doppler revealing biphasic waveforms. Leg and foot compartments were compressible. After irrigation of the operative extremity, Kirschner wires were appropriately angled, cut, and surrounded with xeroform, 4x4 gauze, and a short leg splint. A CAT scan was obtained confirming reduction. The patient was advised to be non-weightbearing with planned wire removal at six weeks.



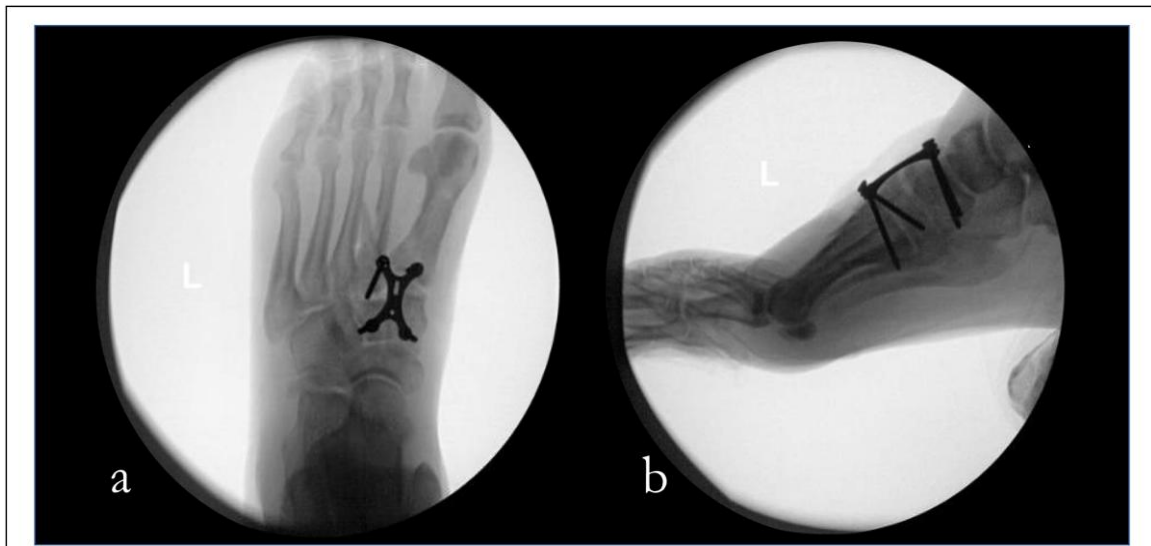**Fig. 1. Pre-operative AP(a) and lateral(b) X-ray images; lateral showing more clearly obvious dorsal dislocation of the medial cuneiform**



**Fig. 2. Coronal(a) and Sagittal(b) CT scans demonstrating evident dorsal dislocation of the medial cuneiform and moving left to right on coronal views, plantar dislocation of the intermediate cuneiform; while less apparent, the plantar dislocation is also discernable on sagittal sections**



**Figure 3:** AP(a) and lateral(b) X-rays showing successful reduction



**Fig. 4.** AP (a) and lateral (b) X-ray images showing successful X plate placement

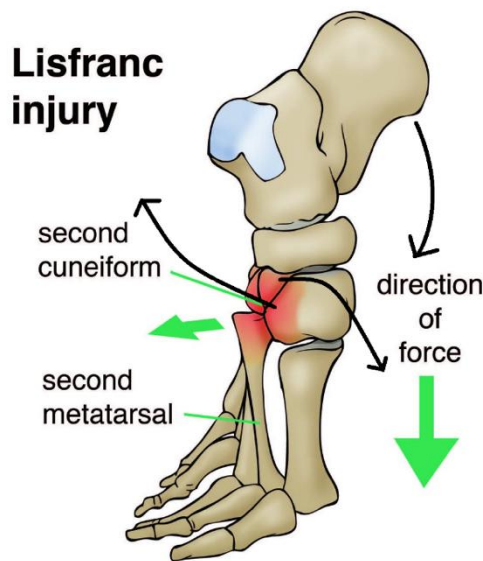
### 3. DISCUSSION

Regarding dislocations associated with Lisfranc fractures, notable bones are the medial, intermediate, and lateral cuneiforms which have distal articulations with the first, second, and third metatarsals, respectively, and proximal articulations with the navicular bone. Intercuneiform joints exist between the three wedge-shape bones, permitting gliding and rotational movements [5,13]. Contributions to the transverse and medial longitudinal arches of the foot are provided by the cuneiforms, and the intermediate cuneiform, between medial and

lateral cuneiforms, has a firm connection with the first metatarsal. Further, it holds a recess that accepts the base of the second metatarsal, comprising the “keystone” of the Lisfranc joint complex [5,11,14-16]. Stabilization of the bones forming the complex (i.e. tarsals and metatarsals) is provided by dorsal, deep transverse, and plantar ligaments, with the latter being further reinforced by slips of tibialis posterior tendon. [6,9-14,16,17]. While composite strength is created by many interosseous ligaments, it is the larger and stronger Lisfranc ligament between the second metatarsal base and medial cuneiform that contributes greatest

[5,7,8]. There is less dorsal support in the midfoot compared to the plantar aspect, and in the setting of excessive plantar flexion secondary to impact trauma, cuneiforms may be displaced dorsally [11,12,14,15].

In our case it is conceivable that the indirect traumatic injury sustained in the accident provided that rotational force to a plantarflexed foot necessary for a Lisfranc fracture and dorsomedial dislocation of the medial cuneiform. A second force vector caused a plantar dislocation of the intermediate cuneiform (Illustration 1) [21]. Lateral XR views best delineate sagittal malalignment. CAT scans were also obtained providing critical windows to define this fracture pattern.



**Illustration 1. Lorenz et. al (2013). Mechanism of lisfranc injury**

The majority of authors approximate Lisfranc fracture-dislocations by ORIF with many opting for an open approach following failed closed attempts [4,6,9,11,14,16-18,20]. *Abdelgaid et al* are among those with unsuccessful attempts who, consequently, have rested on recommendations from *Denton et al (1980)*, proposing that Lisfranc fracture dislocations are irreducible by closed means alone and require open reduction [20]. *P.H. Hardcastle et al.* suggest that, whenever possible, closed reduction should be attempted, and that the only absolute indication for ORIF is pre-operative vascular insufficiency not improved after closed reduction. We have demonstrated that closed reduction techniques are effective in reducing

high energy, complex Lisfranc fracture-dislocations successfully, as well as restoring vascular sufficiency, most notably in this one-off variant with multidirectional dislocations.

Given this patient's active duty status, a collaborative decision was reached at follow-up to convert to stabilization with a Synthes X Plate design (Fig 4). During the post-operative evaluation of his films and review of his expectations and personal obligations, the decision to provide plate fixation was two-fold. Firstly, the patient is active duty with demand for high function in training and combat requiring the most stable prosthetic. Literature has yet to support the use of closed reduction percutaneous pinning as monotherapy for the fracture pattern discussed above, particularly in such a high-demand patient. Secondly, due to surgeon experience and supporting literature, it was agreed to continue with an evidence-based technique that could provide established stability.

#### 4. CONCLUSION

Lisfranc fractures are rare, and this is a unique case of a Lisfranc injury with bidirectional dislocations of the medial and intermediate cuneiform bones. Appropriately executed manual traction and manipulation with Kirschner pin fixation was successful in this patient. In the setting of an average patient with low physical demand, the procedure detailed herein is an ideal approach for fixation as well as adequate future function. Further, closed reduction techniques limit infectious risks, decrease hospital costs, and shorten hospital stays. With higher physical demands, plate reinforcement by open reduction may be warranted, and a decision surrounding desired outcomes should be considered case by case.

As suggested above, other factors meriting consideration when selecting an approach are those of financial and infectious burden. This is true not only for the patient, but also the providing institution. Literature supports closed reduction percutaneous fixation of Lisfranc injuries for the desired effects on infection, skin and wound breakdown, recovery time (i.e. length of stay), early rehabilitative therapy, return to function, and peri-operative mortality [20]. We believe then that a more minimally invasive approach to an injury not previously reported-the fracture-dislocation and surgical technique described-can minimize complications and improve outcomes for patients and providers.

## CONSENT

It is not applicable.

## ETHICAL APPROVAL

It is not applicable.

## ACKNOWLEDGEMENTS

Consent was obtained by patient for publication of the study.

## CONFLICTS OF INTEREST STATEMENT

The authors have no competing interests or relationships that could inappropriately influence their work.

## REFERENCES

1. Sobrado MF, Saito GH, Sakaki MH, Pontin PA, Santos ALGD, Fernandes TD. Epidemiological study on Lisfranc injuries. *Acta Ortop Bras.* 2017;25(1):44-47.
2. Hardcastle PH, Reschauer R, Kutscha-Lissberg E, Schoffmann W. Injuries to the tarsometatarsal joint. Incidence, classification and treatment. *J Bone Joint Surg Br.* 1982;64(3):349-56.
3. Brown DD, Gumbs RV. Lisfranc fracture-dislocations: Report of two cases. *J Natl Med Assoc.* 1991;83(4):366-369.
4. Kalraiya AJ, Vanhegan I, Cheung A, Rudge B. A rare Lisfranc-type injury involving dorsal dislocation of the intermediate cuneiform. *BMJ Case Rep.* 2014;2014:bcr2013203364. Published 2014 Jul 29. DOI:10.1136/bcr-2013-203364.
5. Didomenico LA, Stein DY. Tarsometatarsal (Lisfranc) Joint Dislocation. In: *The Podiatry Institute. Mc Glamry's Comprehensive Textbook of Foot and Ankle Surgery*, 4<sup>th</sup> ed. Philadelphia, PA: Wolters Kluwer Health. 2012;1677-81.
6. Fujita M, Yamamoto H, Kariyama K, Yamakawa H. Isolated plantar dislocation of the middle cuneiform: A Case Report. *J Orthop Sci.* 2003;8(6):875-877.
7. Scolaro J, Ahn J, Mehta S. Lisfranc Fracture Dislocations. *Clin Orthop Relat Res.* 2011;469(7):2078-80. DOI: 10.1007/s11999-010-1586-z. Epub 2010 Sep 28.
8. Matar HE, Atkinson HD, Toh EM, Akimau PI, Davies MB. Surgical interventions for treating tarsometatarsal (Lisfranc) fracture dislocations. *Cochrane Database of Systematic Reviews.* 2014;7. Art. No.: CD011235. DOI: 10.1002/14651858.CD011235.
9. Verma A, Sharma VK, Batra S, Rohria MS. Neglected isolated plantar dislocation of middle cuneiform: A Case Report. *BMC Musculoskelet Disord.* 2007;8:5. Published 2007 Jan 17. DOI:10.1186/1471-2474-8-5
10. Doshi D, Prabhu P, Bhattacharjee A. Dorsal dislocation of the intermediate cuneiform with fracture of the Lisfranc joint: A Case Report. *J Foot Ankle Surg.* 2008;47(1):60-2. DOI: 10.1053/j.jfas.2007.10.004
11. Kumar MA, Madaan E. Dorsal Dislocation of Medial Cuneiform Along with Lisfranc Injury: Approach to a Rare Injury. *J Clin Exp Orthop.* 2017;3:30. DOI:10.4172/2471-8416.100030.
12. Hidalgo-Ovejero A, García-Mata S, Ilzarbe-Ibero A, Gozzi-Vallejo S, Martínez-Grande M. Complete Medial Dislocation of the First Cuneiform: A Case Report. *J Foot Ankle Surg.* 2005;44(6):478-82.
13. Singh AP, Singh AP, Garg V, Garcha JS. Dislocation Intermediate Cuneiform with Fracture Medial Cuneiform. *J Orthop Case Rep.* 2016;6(5):32-34. DOI: 10.13107/jocr.2250-0685.618.
14. Akan B, Yildirim T. Dorsal Dislocation of the Intermediate Cuneiform with a Medial Cuneiform Fracture: A Case Report and Review of the Literature. *Case Rep Orthop.* 2013;2013:238950. DOI: 10.1155/2013/238950.
15. Hung J, Chan S. Intercuneiform and lisfranc fracture-dislocation due to seizure: A Case Report. *J Foot Ankle Surg.* 2016;55(2):314-6. DOI: 10.1053/j.jfas.2014.09.039.
16. Nishi H, Takao M, Uchio Y, Yamagami N. Isolated Plantar Dislocation of the Intermediate Cuneiform Bone. *J Bone Joint Surg Am.* 2004;86-A(8):1772-7.
17. Nashi M, Banerjee B. Isolated plantar dislocation of the middle cuneiform- A case report. *Injury.* 1997;28(9-10):704-6.
18. Papanikolaou A, Maris J, Arealis G, Papadimitriou G, Charalambidis C. Dislocation of the lateral cuneiform. Report of two cases: One with dorsal and one with plantar displacement. *Foot Ankle Surg.* 2010;16(4):e91-5. DOI: 10.1016/j.fas.2009.11.006.

19. Bulut G, Yasmin D, Heybeli N, Erken H, Yildiz M. A Complex Variant of Lisfranc Joint Complex Injury. J Am Podiatr Med Assoc. 2009;99(4):359-63.
20. Abdelgaid SM, Salah M, Abdulsalam S, Abdulmalak F. Closed Reduction & Percutaneous Fixation of Lisfranc Joints Injuries: Possibility, Technique & Results. Clin Res Foot Ankle. 2013;1(2):109. DOI:10.4172/2329-910X.100010.
21. Lorenz DS, Beauchamp C. Functional progression and return to sport criteria for a high school football player following surgery for a lisfranc injury. International Journal of Sports Physical Therapy. 2013 ; 8(2):162.

---

© 2019 Summers et al.; This is an Open Access article distributed under the terms of the Creative Commons Attribution License (<http://creativecommons.org/licenses/by/4.0>), which permits unrestricted use, distribution, and reproduction in any medium, provided the original work is properly cited.

*Peer-review history:*

*The peer review history for this paper can be accessed here:  
<http://www.sdiarticle3.com/review-history/48589>*