



# **Histological Assessment on Cadmium Induced Liver Damage Following Oral Administration of *Moringa oleifera* Oil and *Anacardium occidentale* Nuts Oil in Wistar Rats**

**O. D. Omotoso<sup>1</sup>, S. A. Adelakun<sup>2\*</sup>, O. O. Oyewo<sup>2</sup> and B. T. Adediran<sup>3</sup>**

<sup>1</sup>Department of Anatomy, Kogi State University, Anyigba, Kogi State, Nigeria.

<sup>2</sup>Department of Anatomy, Ladoké Akintola University of Technology, Ogbomoso, Oyo State, Nigeria.

<sup>3</sup>Department of Anatomy, Bingham University, Karu, Nasarawa, Nigeria.

## **Authors' contributions**

*This work was carried out in collaboration among all authors. Authors SAA, ODO and OOO designed the study, wrote the protocol and wrote the first draft of the manuscript. Authors SAA and ODO managed the literature searches, analyses of the study and performed the spectroscopy analysis. Authors OOO and BTA managed the experimental process. Authors SAA and ODO identified the species of plant. All authors read and approved the final manuscript.*

## **Article Information**

DOI: 10.9734/JAMMR/2019/v29i330076

Editor(s):

(1) Dr. Chan-Min Liu, School of Life Science, Xuzhou Normal University, Xuzhou City, China.

Reviewers:

(1) Dr. Anthony Cemaluk C. Egbuonu, Department of Biochemistry, Michael Okpara University of Agriculture Umudike, Nigeria.

(2) Dr. Eman N. Ali, Faculty of Chemical and Natural Resources Engineering, Universiti Malaysia Pahang, Malaysia.

(3) Martin Potgieter, Department of Biodiversity, University of Limpopo, South Africa.

Complete Peer review History: <http://www.sdiarticle3.com/review-history/24142>

**Original Research Article**

**Received 12 December 2015**

**Accepted 25 February 2016**

**Published 30 March 2019**

## **ABSTRACT**

**Background:** Cadmium is a human carcinogen element and one of the most toxic pollutants in the environment. Present study aims at histomorphological study of some of the effects of *Moringa oleifera* oil and cashew (*Anacardium occidentale*) nuts oil on Cadmium-induced liver damage in wistar rats.

**Methods:** Thirty-five Wistar rats (80-180 g) were randomly selected and divided into seven groups of five rats each after acclimatization for two weeks. Group A which served as control received phosphate buffer, Group B received Cadmium only (3.5 mg/kg body weight). Group C received Vitamin C and Vitamin E; Group D received Vitamin C, Vitamin E and Cadmium. Group E received

\*Corresponding author: E-mail: [anasony2008@gmail.com](mailto:anasony2008@gmail.com);

Cadmium and *Moringa oleifera* oil, Group F received Cadmium and Cashew nut oil and Group G received Cadmium (3.5 mg/kg body weight) and *Moringa oleifera* oil and Cashew (*Anacardium occidentale*) nut oil.

**Results:** Histological examination revealed normal histo-architecture of the liver, the central vein and the hepatocytes were seen clearly and there was orderly arrangement of the hepatocytes in Group A (control group). In group B, there was enlarged portal vein and there was distorted arrangement of the hepatocytes. In group C, the hepatocytes and the central vein were seen. In group D, the central vein and hepatocytes were seen though not orderly arranged. In groups E, F and G, there was restoration of the hepatocytes and the central vein was seen.

**Conclusion:** This therefore suggests that *Moringa oleifera* oil and Cashew (*Anacardium occidentale*) nut oil have ameliorative effects which led to the restoration of the damaged and distorted hepatocytes.

**Keywords:** Histomorphology; *Moringa oleifera*; *Anacardium occidentale*; oxidative stress; liver; cadmium.

## 1. INTRODUCTION

Human beings are being exposed to heavy metals in their daily activities. Several human activities such as in the industries, agriculture, foods and even in medicines predispose them to these toxic metals and exposure to toxic metals remains a wide spread occupational and environmental problems in the world (a global concern) [1]. Heavy metals may enter the human body through food, water, air, or absorption through the skin when they come in contact with humans in agriculture and in manufacturing, pharmaceutical, industrial, or residential settings. Industrial exposure accounts for a common route of exposure for adults.

Cadmium (Cd) is one of the most toxic metal ions of the environment which is bound in the air, food and water [2]. It is a non essential, group II metal. Cadmium is an inorganic toxicant of great environmental and occupational concern which was classified as a human carcinogen in 1993 [3,4]. It is one of the most toxic pollutants in the environment. Cadmium (Cd) enters the environment mainly from industrial processes or fertilizer application and it can be transferred to the food chain by plant uptake. Cd is a toxic heavy metal for humans, animals and plants. It is found in foods (vegetables, grains and cereals), water and tobacco leaves, and is also produced as a byproduct of zinc and lead mining and smelting [5]. Cadmium as a heavy metal is non-biodegradable and its environmental levels are increasing due to industrial practices [6].

In the last few decades there has been an exponential growth in the field of herbal medicine. It is getting popularized in developing and developed countries owing to its natural

origin and lesser side effects [7]. Herbal drugs constitute a major share of all the officially recognized systems of health. In many developing countries, a large proportion of the population relies on traditional practitioners and their armamentarium of medicinal plants in order to meet health care needs. Although modern medicines may exist side-by-side with such traditional practice, herbal medicines have often maintained their popularity for historical and cultural reasons. Such products have become more widely available commercially, especially in developed countries. Use of herbal medicines in developed countries has expanded sharply in the latter half of the twentieth century [8]. The evaluation of various plant products according to their traditional uses and medicinal value based on their therapeutic efficacy leads to the discovery of newer and recent drugs for treating various ailments. This fact forms the basis for the development of new drugs from various plant sources. Two of such plants of medicinal value are *Moringa olifera* and Cashew (*Anacardium occidentale*,) nut [9]. *Moringa oleifera* L (*Moringaceae*) known commonly as Ben oil tree or drumstick tree in English language, 'Okwe oyibo' in Igbo, 'Gawara' or 'Habiwal' in Hausa and 'Adagba maloye' or 'Ewe Igbale' in Yoruba grows rapidly in most regions and climatic conditions of Nigeria. It is an important food commodity which has had enormous attention as the 'natural nutrition of the tropics' [10]. A number of medicinal properties have been ascribed to various parts of this tree. Most parts of this plant: root, bark, gum, leaf, fruit (pods) flowers, seed and seed oil have been used in folk medicine in Africa and South Asia [11]. It has been used for the treatment of inflammation, infectious diseases, cardiovascular, gastrointestinal, and hematological and hepatorenal disorders [12,6].

Most of plants uses for medicinal purposes have been correlated to their possession of antioxidant activity [13,14,15]. Cashew is a tree in the family of the flowering plant Anacardiaceae. It is a native of Brazil and the Lower Amazons. The cashew has been introduced and is a valuable cash crop in the Americas, the West Indies, Madagascar, India and Malaysia [16]. Cashew nut is a high value edible nut. It yields two "Oils" one of these found, between the seed coat (or pericarp) and the nuts, is called the Cashew Nut Shell Liquid (CNSL). It is not a triglyceride and contains a high proportion of phenolic compound. It is used in industry as a raw material for brake lining compounds. CNSL has wide commercial applications, biological and medicinal properties [17,18,19]. The biological properties of CNSL such as larvicidal [20], molluscicidal [21,22], antifungal and antibacterial [23,24] were also reported. The medicinal properties of phytochemicals present in CNSL reported are cytotoxic activity against several tumor cell lines [25], anti-diabetic [26], anti-inflammatory and analgesic effects [27,28].

Present study therefore aims at histomorphological study of some of the effects of *Moringa oleifera* oil, Cashew nut oil and Vitamin C and E on Cadmium-induced liver damage in wistar rats.

## 2. MATERIALS AND METHODS

### 2.1 Extract Preparation

#### 2.1.1 Extraction of *Moringa oleifera* oil

*Moringa oleifera* seed was purchased from Maraba market in Nasarawa State. The oil was extracted using the following procedures. The husks were removed from 2330 g of *Moringa* seeds and were heated in an oven at a temperature of 40°C and were pounded using a mortar and pestle to separate the chaff from the seeds. The seed was grinded into powder using a grinding mill. The powdered form of *Moringa Oleifera* was dissolved in 466ml of water at ambient temperature for two days and was later filtered through Whatman filter paper. The aqueous extract was then poured into molten mesh and placed on an oil extractor machine. The seed oil was removed at high temperature and pressure.

#### 2.1.2 Extraction of cashew nut oil

Cashew nut was purchased from Kuchikau in Nasarawa state. The oil was extracted using the

following procedure. Cashew (*Anacardium occidentale*) nuts (2000 g) were heated in an oven at a temperature of 40°C and were grinded into powder using a grinding mill. The powdered form was poured into a molten mesh and placed in an oil extractor machine. The oil was removed at high temperature and pressure and both oil extract were kept at room temperature.

### 2.2 Drug Preparation

The Cadmium Sulphate Solution (3CdSO<sub>4</sub>.8H<sub>2</sub>O) was prepared by dissolving 9.9198 mg of Cadmium Sulphate salt (CdS) in 5 ml of 0.9% w/v Phosphate buffer. The Ascorbic acid (Vitamin C) was prepared by dissolving 5mg of Vitamin C in 10 ml of 0.9% w/v Phosphate buffer. The Vitamin E (Alpha Tocopherol) was prepared by dissolving 6 mg of Vitamin E in 20 ml of olive oil.

### 2.3 Experimental Animals

Thirty five (35) Wistar rats weighting between 80 g-180 g were used for this study. The rats were randomly selected into seven groups as follow A, B, C, and D, E, F and G each group containing five rats. They were kept in the animal house of Bingham University, Nigeria and given feed and water *ad libitum*. The treatment for the various groups was administered accordingly.

### 2.4 Chemical and Extract Administration

0.32 ml (40 mg/kg body weight) of *Moringa Oleifera* and Cashew nut seed oil, 0.16 ml (20 mg/kg body weight) each of *Moringa oleifera* seed oil and Cashew nut oil, 0.8 ml (100 mg/kg body weight) of Vitamin C, 0.3 ml of Vitamin E (300 mg/kg body weight) and 5 ml of 0.9% w/v of Phosphate buffer were administered orally to the experimental rats according to their individual groups for a period of four (4) weeks using a 2 ml syringe with an oral cannular at the tip. The administration was done by holding the rats with a glove using the left hand in such a way that the neck region was being held so that the rats would be stable while the extracts were being administered orally. The treatment was done every morning after which the animals were fed.

### 2.5 Animal Sacrifice

The animals were sacrificed twenty four (24) hours through cervical dislocation after which food and water had already being withdrawn from them. The animals were laid in a supine position on the dissecting board, the two hind

limbs were held and the tail was pulled until a sound was held which indicated that the animal was dead. The thoracic and abdominal cavities were exposed adequately by using a surgical blade to make a midline incision through the skin of the abdominal wall from the xiphisternum to the pubic symphysis. After the abdominal cavity had been adequately exposed, the liver was removed and fixed in 10% formosaline for histological analysis.

## 2.6 Histological Preparation of Tissues

After the livers of the Wistar rats were harvested, they were placed in specimen bottles containing 10% formosaline to prevent autolysis. The processes involved are;

**Fixation:** The liver was fixed in 10% formosaline to preserve the cell and tissue in a life-like state as much as possible and to prevent autolysis.

**Dehydration:** The liver was passed through ascending grades of alcohol (70%, 80%, 90% and absolute 100%) to gradually remove its water contents.

**Clearing:** The sample was placed in a clearing agent which is xylene to remove the alcohol. This improves the refractive index of the tissue.

**Infiltration:** This is the immersion of the tissue in molten paraffin wax so that the holes left by the alcohol would be filled up. This gives the tissue support.

**Embedding:** The tissue is placed into an embedding mould which is filled with more paraffin wax and allowed to solidify. This is done in order to make the tissue compact for sectioning. The block is trimmed to remove the excess wax.

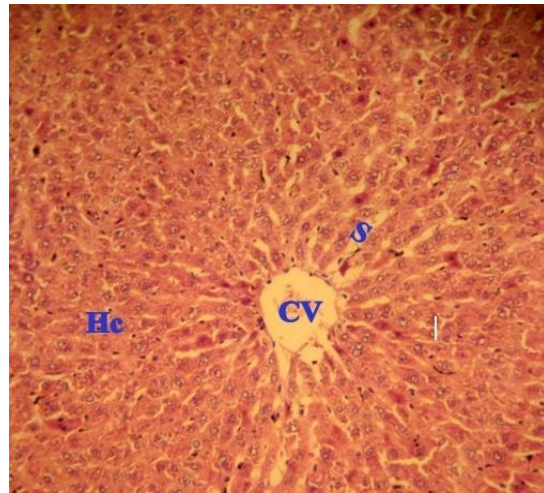
**Sectioning:** The block of tissue was placed in a microtome and trimmed to expose the surface. The microtome was set to 3-5 micron and the tissue was sectioned. The sections were picked with forceps and placed in a water bath to float out and spread well. It was picked with a slide and the slide was placed on a hot plate in order for the tissue to stick to the slide.

**Staining:** The slides were arranged on a staining rack and dewaxed in two changes of xylene for 10 minutes. It was then hydrated in descending grades of alcohol and rinsed. The stain was applied and the slides left to dry.

## 3. RESULTS

### 3.1 Histological Findings

Fig. 1 shows the photomicrograph of liver from control (group A) rats. The Liver histological examination revealed normal histo- architecture of the liver, the central vein and the hepatocytes were seen clearly and there was orderly arrangement of the hepatocytes.



**Fig. 1. Histological demonstration of the liver using H & E staining techniques [X400] showing the normal central vein (CV) sinusoids (S) and hepatocytes (Hc)**

Fig. 2 shows the histological features from the liver of experimental animal administered Cadmium only, there was enlarged portal vein and there was distorted arrangement of the hepatocytes.

Fig. 3 shows the liver histological features from experimental animal administered Vitamin C and Vitamin E showing enlarged portal vein (EPV) and hepatocytes (Hc).

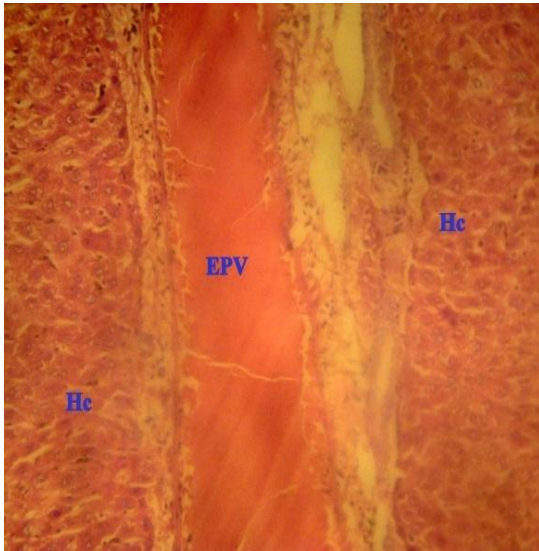
Fig. 4 shows the liver histological features from experimental animal administered Vitamin C and E and Cadmium, showing distorted hepatocytes (Hc), central vein (CV) and Sinusoids (S).

Fig. 5 shows the liver histological features from experimental animal administered Cadmium and Moringa oil. Showing restored terminal hepatic (centrilobular) venule (tHL) and central vein (CV).

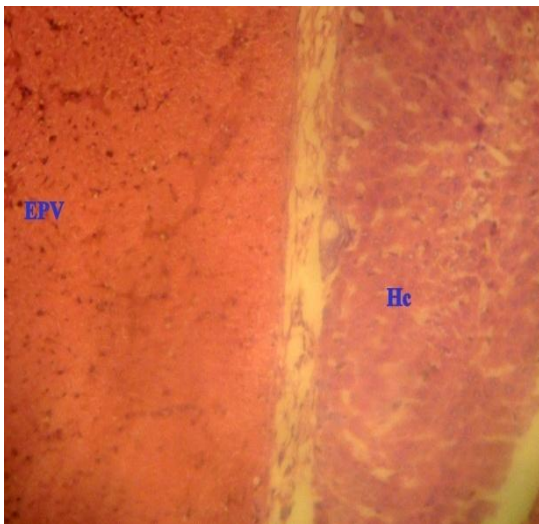
Fig. 6 shows the liver histological features from experimental animal administered Cadmium and

Cashew oil showing restoration of Central vein (CV), sinusoids (S) and hepatocytes (Hc).

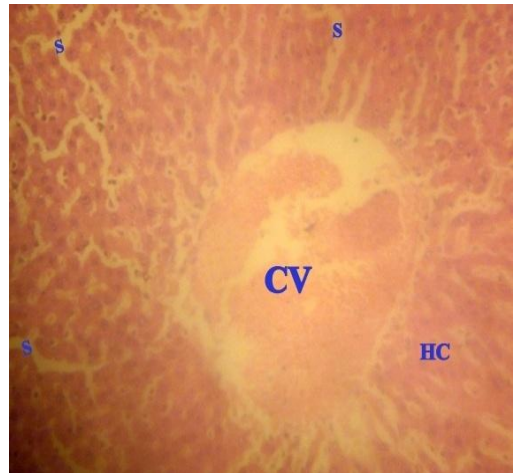
Fig. 7 shows the liver histological features from experimental animal administered Cadmium and Moringa oil and Cashew oil showing the portal vein (PV) and restored hepatocytes (Hc) with the sinusoidal beds.



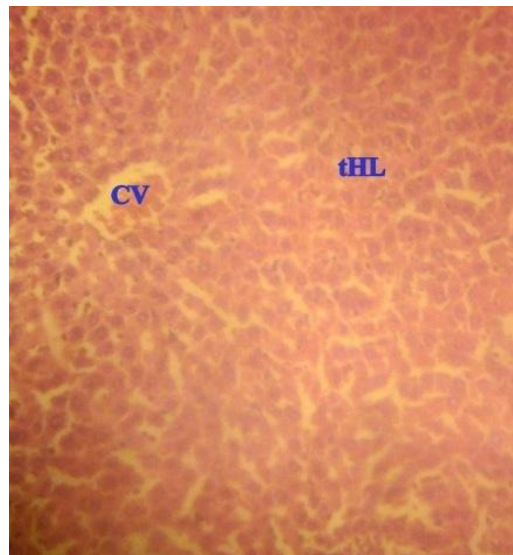
**Fig. 2.** Histological demonstration of the liver using H & E staining techniques [X400] showing enlarged portal vein (EPV) with distortion of the hepatocytes (Hc)



**Fig. 3.** Histological demonstration of the liver using H & E staining techniques [X400] showing enlarged portal vein (EPV) and hepatocytes (Hc)



**Fig. 4.** Histological demonstration of the liver using H & E staining techniques [X400] showing the hepatocytes (Hc), central vein (CV) and Sinusoids (S)



**Fig. 5.** Histological demonstration of the liver using H & E staining techniques [X400] showing the terminal hepatic (centrilobular) venule (tHL) and central vein (CV)

### 3.2 Histological Demostration

#### 3.2.1 Group A (control)

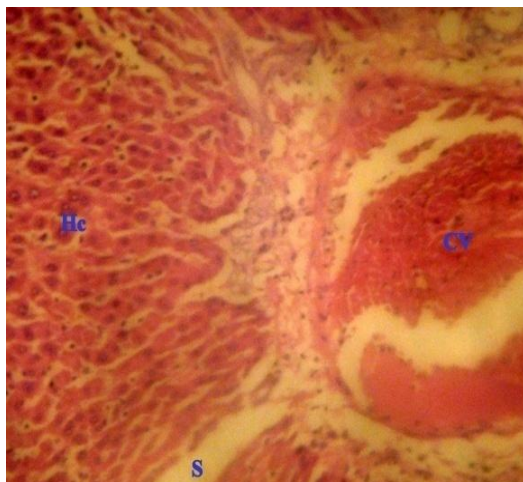Photomicrographs of the liver of experimental animal administered phosphate buffer as control.

#### 3.2.2 Group B

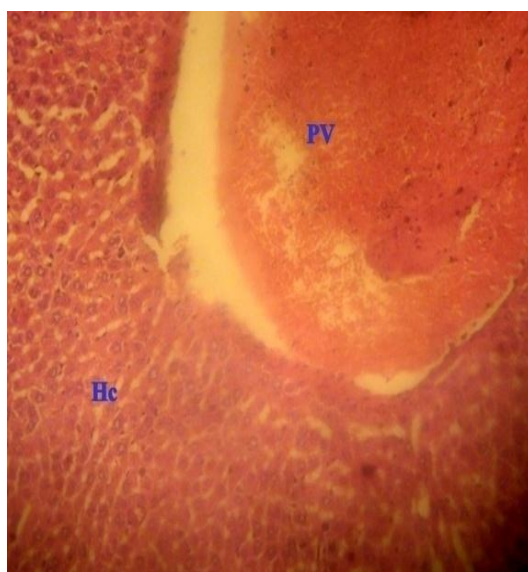Photomicrographs of the liver of experimental animal administered Cadmium only.

### 3.2.3 Group C

Photomicrographs of the liver of experimental animal administered Vitamin C and Vitamin E.



**Fig. 6. Histological demonstration of the liver using H & E staining techniques [X400] showing Central vein (CV), sinusoids (S) and hepatocytes (Hc)**



**Fig. 7. Histological demonstration of the liver using H & E staining techniques [X400] showing the portal vein (PV) and hepatocytes (Hc) with the sinusoidal beds**

### 3.2.4 Group D

Photomicrographs of the liver of experimental animal administered Vitamin C and E and Cadmium.

### 3.2.5 Group E

Photomicrographs of the liver of experimental animal administered Cadmium and Moringa oil.

### 3.2.6 Group F

Photomicrographs of the liver of experimental animal administered Cadmium and Cashew oil.

### 3.2.7 Group G

Photomicrographs of the liver of experimental animal administered Cadmium and Moringa oil and Cashew oil.

## 4. DISCUSSION

In group A, the normal histological architecture of the liver was seen. The central vein and the hepatocytes were seen clearly and there was orderly arrangement of the hepatocytes. In group B, there was enlarged portal vein and there was distorted arrangement of the hepatocytes. This thus indicates hepatic dysfunction due to the generation of reactive oxygen species. This therefore confirms the suggestion by [29] that upon acute exposure to cadmium, hepatotoxicity is indicated by changes such as swelling of hepatocytes, fatty changes, focal necrosis, hepatocytes degeneration and impaired functions of biomarkers of liver function. In group C, the hepatocytes and the central vein were seen. This suggests that the antioxidant activities of the Vitamins can help to enhance the liver functions. In group D, the central vein and hepatocytes were seen though not orderly arranged. This suggests that the antioxidant activities of the Vitamins have helped to curb the free oxygen radicals generated by the Cadmium. This therefore is in line with the suggestion made by [1,30] that antioxidant has been found to heal the free radical mediated cell damage. In groups E, F and G, there was restoration of the hepatocytes and the central vein was seen. This therefore suggests that *Moringa oleifera* oil and *Anacardium occidentale* nut oil cause restoration of the damaged and distorted hepatocytes.

## 5. CONCLUSION

We therefore concluded from the present study that *Moringa oleifera* oil and *Anacardium occidentale* nut oil have ameliorative effects which led to the restoration of the damaged and distorted hepatocytes. *Moringa oleifera* oil and

*Anacardium occidentale* nut oil may be effective for treatment of any form of liver damage.

## CONSENT

It is not applicable.

## ETHICAL APPROVAL

All the authors hereby declare that all the experiments have been examined and approved by the appropriate ethics committee and have therefore been performed in line with the ethical procedure laid down by Nigeria Medical Ethical Association for Accreditation of Laboratory Animal Care.

## COMPETING INTERESTS

Authors have declared that no competing interests exist.

## REFERENCES

1. Flora SJS, Mittal M, Mishra D. Co-exposure to arsenic and fluoride on oxidative stress, glutathione linked enzymes, biogenic amines and DNA damage in mouse brain. *J. Neurol Sci.* 2009;285:198-205.
2. Lin S, Sandow M, Decandido S, Waslien C, Naughton B. The effect of vitamin D3 and 1,25-dihydroxy vitamin D3 on the toxic symptoms of cadmium exposed rats. *Nutr. Res.* 1992;12:1393.
3. Alfen T, Elinder CG, Jarup L. Cadmium: A public health problem. *Nord Med.* 1997;112:331-333.
4. Friberg L, Elinder CG, Kjellström T. Environmental health criteria: Cadmium. World Health Organization (Geneva). 1992;134:36-43.
5. Stohs ST, Bagchi D. Oxidative mechanism in the toxicity of chromium and cadmium ions. *J Environ Pathol Toxicol Oncol.* 2000;19(3):201-213.
6. Waalkes MP, Klaassen CD. Toxicology of cadmium. In: Goyer, R.A., Cherian, M.G. (Eds.), *Toxicology of metals: Biochemical aspects.* Handbook of experimental pharmacology. Springer, New York. 1995;115:189-213.
7. Nku-Ekpang Okot-Asi T, Nwaehujor Chinaka O, Ofem Ofem E, Ezekiel Josiah I. Effect of *Moringa oleifera* Lam. Ethanol leaf extract on hematology in phenylhydrazine-induced anemic albino wistar rats. *American Journal of Pharmacological Sciences.* 2015;3(3):67-73. DOI: 10.12691/ajps-3-3-3
8. Nku-Ekpang Okot-Asi T, Nwaehujor Chinaka O, Ofem Ofem E, Ezekiel Josiah I. Effect of *Moringa oleifera* Lam. Ethanol leaf extract on hematology in phenylhydrazine-induced anemic albino wistar rats. *American Journal of Pharmacological Sciences.* 2015;3(3):67-73. DOI: 10.12691/ajps-3-3-3
9. Gupta VK, Kumria R, Garg M, Gupta M. Recent updates on free radicals scavenging flavonoids: An overview. *Asian J. Plant Sci.* 2010;9:108-117.
10. Anwar F, Rashid U. Physico-chemical characteristics of *Moringa oleifera* seeds and seed oil from a wild provenance of Pakistan. *Pak. J. Bot.* 2007;39:1443-1453.
11. Fahey JW. A review of the medical evidence for its nutritional, therapeutic and prophylactic properties. *Trees Life Journal.* 2005;1:5.
12. Siddhuraju P, Becker K. Antioxidant properties of various solvent extracts of total phenolic constituents from three different agroclimatic origins of drumstick tree (*Moringa oleifera* Lam.) leaves. *Journal of Agricultural and Food Chemistry.* 2003;51(8):2144-55.
13. Middleton E. Jr, Kandaswami C, Theoharides TC. The effects of plant flavonoid on mammalian cells: Implications for inflammation, heart disease cancer. *Pharmacol. Rev.* 2000;52:673-751.
14. Nithya N, Chandrakumar K, Ganavan V, Senthilkumar S. Efficacy of *Momordica charantia* in attenuating abnormalities in cyclophosphamide intoxicated rats. *J. Pharmacol. Toxicol.* 2012;7(1):38-45.
15. Sofidiya MO, Odukoya OA, Familoni OB, Inya-Agha SI. Free radical scavenging activity of some Nigerian medicinal plant extracts. *Pak. J. Biol. Sci.* 2006;9:1438-1441.
16. Frankel E. Poison ivy, Poison oak, Poison sumac and their relative pistachios: Mangoes and cashew. The Boxwood Press Pacific Grove CA. 1991;2:15-16.
17. Mahanwar PA, Kale DD. Effect of cashew nut shell liquid (CNSL) on properties of phenolic resins. *J. Appl. Polymer Sci.* 1996;61:2107-2111.
18. Menon ARR. Flame-retardant characteristics of natural rubber modified

- with a bromo derivative of phosphorylated cashew nut shell liquid. J. Fire Sci. 1997;15:3-13.
19. Murthy BGK, Sivasamban MA. Recent trends in CNSL utilization. Cashew Research and Development: Proceedings of the International Cashew Symposium, Cochin, Kerala, India. 1979;201-207.
  20. Evans DA, Raj RK. Extracts of Indian plants as mosquito larvicides. Indian J. Med. Res. 1988;88:38-41.
  21. Laurens A, Fournau C, Hocquemiller R, Cave A, Bories C, Loiseau PM. Antivectorial activities of cashew nut shell extracts from *Anacardium occidentale* L. Phytother. Res. 1997;11:145-146.
  22. Casadei E, Bruheim S, Latis T. Active substances in cashew nut shell with molluscicidal activity: Possible use in schistosomiasis control programmes. Revista Medica de Mocambique. 1984;2:35-39.
  23. Echendu TNC. Ginger, cashew and neem as surface protectants of cowpeas against infestation and damage by *Callosobruchus maculatus*. Trop. Sci. 1991;31:209-211.
  24. Weerasena OVDSJ, Amarasekara AS, Wijesundera RLC. Fungicidal activity of synthetically modified cashew nut shell. J. Nat. Sci. Coun. 1993;21:253-258.
  25. Kubo I, Ochi M, Vieira PC, Komatsu S. Antitumor agents from the cashew *Anacardium occidentale* apple juice. J. Agri. Food Chem. 1993;41:1012-1015.
  26. Sokeng SD, Kamtchouing P, Watcho P, Jatsa HB, Moundipa PF, Lontsi D. Hypoglycemic activity of *Anacardium occidentale* L. aqueous extract in normal and streptozotocin-induced diabetic rats. Diabetes Res. 2001;36:001-009.
  27. Patil MB, Jalalpure SS, Pramod HJ, Manvi FV. Antiinflammatory activity of the leaves *Anacardium occidentale* L. Ind. J. Pharmaceutical Sci. 2003;65:70-72.
  28. Pawar S, Pal SC. Analgesic and anti-inflammatory activity of *Anacardium occidentale* root extracts. Hamdard-Medicus. 2002;45(4):63-68.
  29. Thijissen SA, Cuypers J, Maringwa K, Smeets, Horemans N. Low cadmium exposure triggers a biphasic oxidative stress response in mice kidneys. Toxicology. 2007;236:29-41.
  30. Flora SJS. Lead in the environment: Prevention and treatment. J. Environ. Biol. 2002;23:29-44.

© 2019 Omotoso et al.; This is an Open Access article distributed under the terms of the Creative Commons Attribution License (<http://creativecommons.org/licenses/by/4.0>), which permits unrestricted use, distribution, and reproduction in any medium, provided the original work is properly cited.

Peer-review history:  
The peer review history for this paper can be accessed here:  
<http://www.sdiarticle3.com/review-history/24142>