


# Intra-Sellary Arachnoidocele: About a Case at the Medical Clinic “The Stars” of Bamako

Ousmane Traore<sup>1,2</sup> , Alassane Kouma<sup>1</sup>, Souleymane Sanogo<sup>1</sup>, Mamadou N’Diaye<sup>3</sup>, Ouncoumba Diarra<sup>4</sup>, Mahamadou Diallo<sup>5</sup>, Adama Diaman Keita<sup>2</sup>

<sup>1</sup>Radiology Department of the Medical Clinic “The STARS”, Bamako, Mali

<sup>2</sup>Radiology Department of the “G” Point University Hospital Center, Bamako, Mali

<sup>3</sup>Radiology Department of the Health Center of the Military Camp, Bamako, Mali

<sup>4</sup>Radiology Department of the Reference Health Center of Municipality III, Bamako, Mali

<sup>5</sup>Radiology Department of the Gabriel Toure University Hospital Center (CHU), Bamako, Mali

Email: ghousno1@yahoo.fr

**How to cite this paper:** Traore, O., Kouma, A., Sanogo, S., N’Diaye, M., Diarra, O., Diallo, M. and Keita, A.D. (2022) Intra-Sellary Arachnoidocele: About a Case at the Medical Clinic “The Stars” of Bamako. *Open Journal of Medical Imaging*, **12**, 190-194. <https://doi.org/10.4236/ojmi.2022.124020>

**Received:** September 27, 2022

**Accepted:** November 29, 2022

**Published:** December 2, 2022

Copyright © 2022 by author(s) and Scientific Research Publishing Inc.

This work is licensed under the Creative Commons Attribution-NonCommercial International License (CC BY-NC 4.0).

<http://creativecommons.org/licenses/by-nc/4.0/>



Open Access

## Abstract

Intrasellar arachnoidocele is a herniation of the optochiasmatic cistern through a dehiscence of the sellar diaphragm producing an empty sella turcica, hence its name empty sella turcica syndrome. It is an extremely rare benign malformative pathology. We report a case of intra-sellar arachnoidocele in a 34-year-old woman revealed during an annual control of a sellar mass under dossinex by cerebral magnetic resonance imaging (MRI) which found the cystic formation of liquid signal identical to that of the LCS in hypo signal T1 and hyper signal T2 without enhancement after injection of Gadolinium. The epidemiological, clinical and radiological aspects of arachnoidocele were analyzed. The purpose of this work is to bring the interest of MRI in the management of this pathology.

## Keywords

Arachnoidocele, Arachnoid Cyst, Sellar, MRI, Bamako

## 1. Introduction

Intrasellar arachnoidocele is a herniation of the optochiasmatic cistern through a dehiscence of the sellar diaphragm resulting in an empty sella turcica in which the sella turcica is partially or completely filled with cerebrospinal fluid (CSF), resulting in displacement of the pituitary hence its name empty sella syndrome [1] [2] [3] [4] [5]. It is also called an intrasellar arachnoid cyst. It is an extremely rare benign malformative pathology, first described in 1831 by BRIGHT [1]. It represents approximately 3% of all intracranial arachnoid cysts [6] [7]. Visual

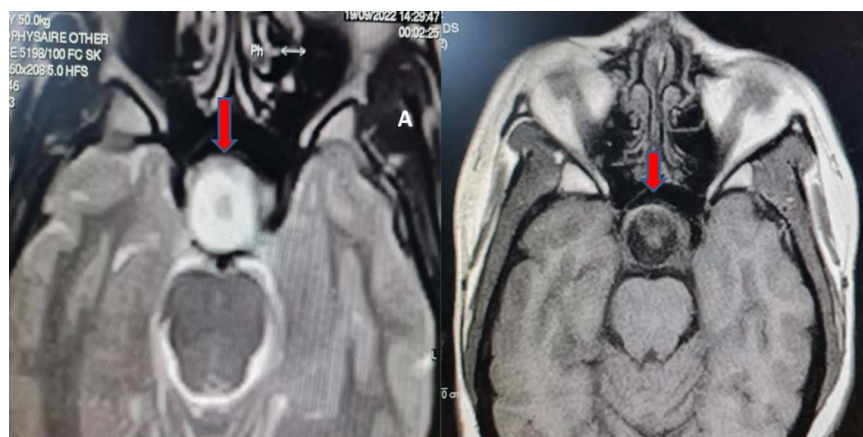
disturbances, headaches and sometimes hormonal disturbances are the typical signs of this intra-sellar localization [6]. However, its etiology is poorly known, congenital, can also be secondary to post-infectious arachnoiditis or hemorrhage. Its radiological diagnosis is essentially made by magnetic resonance imaging (MRI) and should be considered in the presence of any formation of a cystic nature whose signal is identical to that of the cerebrospinal fluid [3] [6] [8]. We report the case of a patient who presented with a hormonal disorder revealing an arachnoid cyst or intrasellar arachnoidocele by MRI. To our knowledge, no study has focused on this pathology in Bamako, hence the initiative of this work, the aim of which is to bring the interest of MRI in the management of this pathology.

## 2. Observation

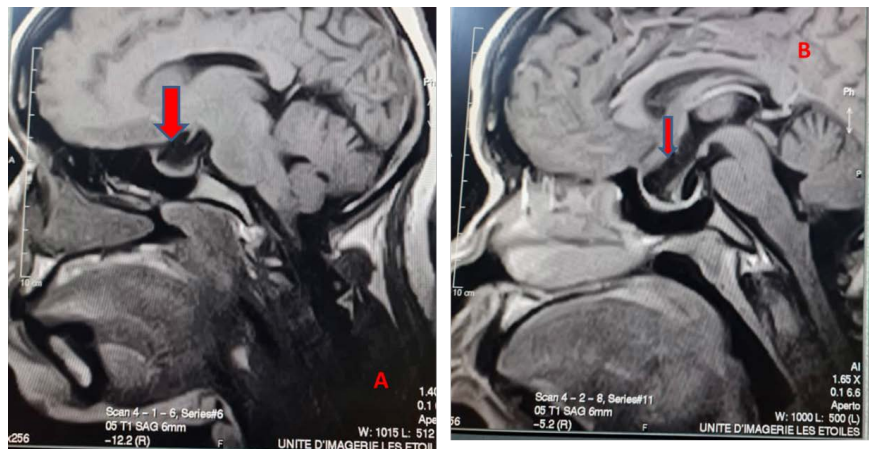
This was a 34-year-old patient with no notable pathological history, in particular no notion of head trauma or surgery. She consulted for headaches, late menstruation 12 months ago, including a CT scan to show a sellar mass discovered by chance and confirmed by MRI and treated for pituitary adenoma. In view of the persistence of the clinical signs, a control pituitary MRI was requested visualizing an intrasellar fluid formation in T1 hypo signal and in T2 hyper signal identical to that of the cerebrospinal fluid, without enhancement of its wall after injection of gadolinium, communicating with the opto-chiasmatic suprasellar cistern (**Figure 1**).

Localized enhancement of the left postero-lateral wall of the cyst which was identified as corresponding to the displaced pituitary gland (**Figure 2** and **Figure 3**).

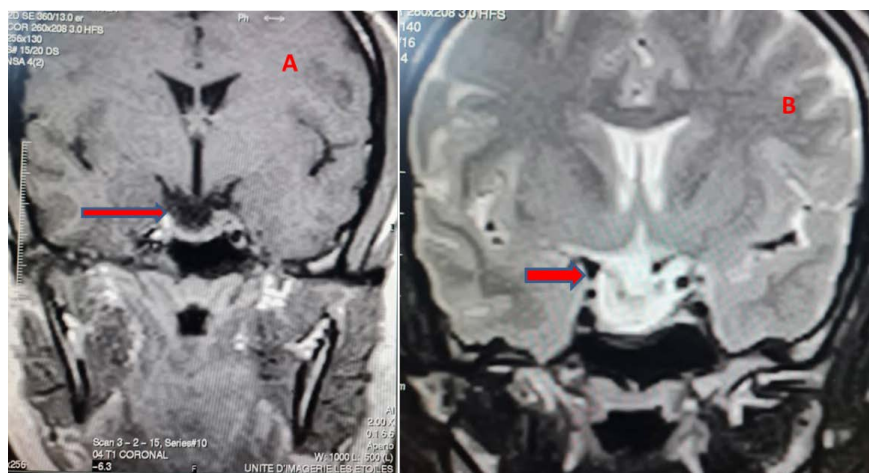
A neurosurgical opinion is requested in order to develop a surgical intervention for the evacuation of the cyst. The cystic formation was successfully bypassed surgically thus confirming the diagnosis of intrasellar arachnoidocele. Its evolution is clinically favorable.



**Figure 1.** MRI in axial T2 (A) and axial T1 (B) sequence showing an arachnoid cyst: rounded formation of intrasellar fluid appearance in hypo signal T1 and hyper signal T2 seeming to be communicated with the opto-chiasmatic suprasellar cistern.



**Figure 2.** MRI in sagittal T1 sequence (A) without injection of gadolinium and sagittal T1 sequence (B) after injection showing an intrasellar arachnoid cyst in hyposignal with enhancement of the postero-lateral wall of the cyst and the displaced pituitary gland.



**Figure 3.** Coronal T1 (A) and coronal T2 (B) sequence MRI showing cystic formation intrasellar in T1 hypo signal without visible contrast enhancement (A) and in T2 hyper signal (B) without invasion cavernous sinuses without bone lysis opposite.

### 3. Discussion

**Epidemiology:** Intrasellar arachnoidocele is an extremely rare pathology and represents less than 10% of cases [3] [9], of poorly known etiopathogenesis [1]. It can be primary, generally found in middle-aged, obese and hypertensive women [4], or secondary. Our case was 34 years old, pregnant with 2 children and the first case encountered in the medical clinic “The Stars” in Bamako, Mali. This pathology was described for the first time in 1831 by BRIGHT and constituted a fluid formation, the wall of which is formed by the arachnoid, containing cerebrospinal fluid under tension. Two theories attempt to explain their pathogenesis; the first by the evolution of empty Turkish stools, and the second by duplication of the arachnoid membrane located under the sellar diaphragm [1] [2] [10].

**Clinics:** In the literature, headaches and visual disturbances are found as revealing signs of an intra-sellar arachnoid cyst. Endocrine signs are less frequent;

most complaints relate to the gonadotropic axis, including menstrual irregularities, infertility, low libido [2] [11] [12]. This is the case of our patient who consulted for headaches and menstrual irregularity such as delayed menstruation. No visual disturbances were found in our patient. These headaches can arise from the distention of the dura mater caused by the cyst. In some cases, they are probably not related to the cyst, the latter being discovered incidentally, during explorations for other pathologies [13].

**Imaging:** The diagnosis of an arachnoidocele or intrasellar arachnoid cyst is often difficult before surgery [6]. MRI is the examination of choice that allows us to evoke it formally, specifying the signal of the contents of the cyst and the presence or absence of peripheral contrast enhancement [6] [13] [14]. The diagnosis of intrasellar arachnoid cyst should be considered in the presence of any formation of a cystic nature whose signal is identical to that of the cerebrospinal fluid, even if there are contrast uptakes at the level of the cyst wall [6]. These enhancements may be related to compression of the pituitary stalk and displacement of the normal pituitary which may be enhanced [6] [9]. In our patient, the diagnosis was evoked in front of an intrasellar lesion without suprasellar extension without peripheral enhancement in hypo signal on the T1 sequence and hyper signal on the T2 sequences. The differential diagnosis is made with multiple lesions of the sellar and suprasellar region such as necrotic pituitary adenomas, cystic craniopharyngiomas, Rathke's pouch cyst, etc. [6]. Our patient was followed and wrongly treated for necrotic pituitary adenoma for one year.

**Treatment:** Surgical treatment is indicated in symptomatic patients or when the cyst evolves. Various surgical procedures and approaches have been proposed including the direct approach by craniotomy, cyst diversion, and endoscopic fenestration [6]. Our neurosurgeon used cyst diversion as a solution. And the evolution is clinically favorable and the patient is still under clinical and radiological medical supervision.

## 4. Conclusion

Intrasellar arachnoidocele is an extremely rare benign malformation in our country Mali. Headaches and hormonal disturbances can be telltale symptoms. MRI is the reference examination and has made it possible to diagnose the arachnoid cyst and guide the appropriate therapy. It also makes it possible to appreciate its relationship with the optical structures and the pituitary gland.

## Consent

The patient has given informed consent for publication.

## Conflicts of Interest

The authors declare no conflict of interest.

## References

- [1] Khelifi, D., Debbabi, W., Kharrat, I. and Samet, S. (2020) Arachnoïdocèle intrasel-

- laire primitive. *Annales d'Endocrinologie*, **81**, 301. <https://doi.org/10.1016/j.ando.2020.07.438>
- [2] Nomura, M., Tachibana, O., Hasegawa, M., Kohda, Y., Nakada, M., Yamashita, T., Yamashita, J. and Suzuki, M. (1996) Contrast-Enhanced MRI of Intracellular Arachnoid Cysts: Relationship between the Pituitary Gland and Cyst. *Neuroradiology*, **38**, 566-568. <https://doi.org/10.1007/BF00626100>
- [3] Badaouiet, M., et al. (2015) Kyste arachnoïdien intra et supra sellaire: Apport de l'IRM. *Pan African Medical Journal*, **22**, 245. <http://www.panafrican-med-journal.com/content/article/22/245/full/> <https://doi.org/10.11604/pamj.2015.22.245.7535>
- [4] Izizag, B.B., et al. (2019) Syndrome de la selle turcique vide: À propos d'un cas. *Pan African Medical Journal*, **33**, 317. <http://www.panafrican-med-journal.com/content/article/33/317/full/> <https://doi.org/10.11604/pamj.2019.33.317.17423>
- [5] Fouad, W. (2011) Review of Empty Sella Syndrome and Its Surgical Management. *Alexandria Journal of Medicine*, **47**, 139-147. <https://doi.org/10.1016/j.ajme.2011.06.005>
- [6] Mbaye, M., et al. (2019) Mise au point sur le kyste arachnoïdien intrasellaire: À propos d'un cas. *Pan African Medical Journal*, **34**, 55. <http://www.panafrican-med-journal.com/content/article/34/55/full/> <https://doi.org/10.11604/pamj.2019.34.55.18564>
- [7] Rengachary, S.S. and Watanabe, I. (1981) Ultrastructure and Pathogenesis of Intracranial Arachnoid Cysts. *Journal of Neuropathology & Experimental Neurology*, **40**, 61-83. <https://doi.org/10.1097/00005072-198101000-00007>
- [8] Dubuisson, A.S., Stevenaert, A., Martin, D.H. and Flandroy, P.P. (2007) Intracellular Arachnoid Cysts. *Neurosurgery*, **61**, 505-513. <https://doi.org/10.1227/01.NEU.0000290896.69825.40>
- [9] Dietemann, J.L., Guessoum, M., Schultz, A., Sanoussi, S., Maitrot, D. and Buchheit, F. (1997) Kyste arachnoïdien intrasellaire: a propos de deux observations. *Journal of Neuroradiology*, **24**, 168-173.
- [10] Smouni, M., Failali, H.E., Bernichi, O. and Benkacem, M. (2021) Arachnoïdocèle intrasellaire idiopathique: À propos d'un cas. *Annales d'Endocrinologie*, **82**, 382-383. <https://doi.org/10.1016/j.ando.2021.08.365>
- [11] Murakami, M., Okumura, H. and Kakita, K. (2003) Recurrent Intracellular Arachnoid Cyst. *Neurologia Medico-Chirurgica (Tokyo)*, **43**, 312-315. <https://doi.org/10.2176/nmc.43.312>
- [12] Tamburrini, G., D'Angelo, L., Paternoster, G., Massimi, L., Caldarelli, M. and Di Rocco, C. (2007) Endoscopic Management of Intra and Paraventricular CSF Cysts. *Child's Nervous System*, **23**, 645-651. <https://doi.org/10.1007/s00381-007-0327-4>
- [13] Weber, F. and Knopf, H. (2006) Incidental Findings in Magnetic Resonance Imaging of the Brains of Healthy Young Men. *Journal of the Neurological Sciences*, **240**, 81-84. <https://doi.org/10.1016/j.jns.2005.09.008>
- [14] Eskandary, H., Sabba, M., Khajehpour, F. and Eskandari, M. (2005) Incidental Findings in Brain Computed Tomography Scans of 3000 Head Trauma Patients. *Surgical Neurology*, **63**, 550-553. <https://doi.org/10.1016/j.surneu.2004.07.049>