



Analysis of in Situ Posterior Spinal Fusion with Pedicle Screws and Rods in Grade I and Grade II Isthmic

S. Manivannan^{1*}

¹*Department of Orthopaedics Sree Balaji Medical College & Hospital Chennai – 600044, India.*

Author's contribution

The sole author designed, analyzed, interpreted and prepared the manuscript.

Article Information

DOI: 10.9734/JPRI/2021/v33i42A32392

Editor(s):

(1) Dr. Mohamed Salem Nasr Allah, Weill Cornell Medical College, Qatar.

Reviewers:

(1) Felix-Martin Werner, Euro Akademie Pößneck, Germany.

(2) Anagha P Patil, R.T.M Nagpur University, India.

Complete Peer review History: <https://www.sdiarticle4.com/review-history/72111>

Original Research Article

Received 20 June 2021
Accepted 25 August 2021
Published 26 August 2021

ABSTRACT

Spondylolysis has never been found in a newborn. Repetitive cyclic loading ultimately results in a stress fracture. Impingement between the inferior articular process of the cephalad vertebra and the superior articular process of the caudal vertebra creates a bending moment that must be resisted by the pars. The hard cortical bone of the pars predisposes it to fatigue fracture, as well as nonunion, decreasing the likelihood of spontaneous healing. If healing occurs, the pars often heal in an elongated position. Either non-union or healing with elongation permits vertebral subluxation. This fundamental change in bony anatomy exposes the disc to increased shear load, even though the axial load remains unchanged. When the stiffness of the cortical bone is reduced by an underlying condition (congenital dysplasia), smaller amounts of tensile forces are required to produce a fatigue fracture. Another possible mechanism is an extension torque which is developed by the erector spinae acting through its attachment to the spinous process, resulting in a stress concentration at the pars. The aim of the study is to analyze the post-operative outcomes in, in-situ posterior spinal fusion with pedicle screws and rods in Grade I and Grade II isthmic and degenerative spondylolisthesis.

Keywords: Spondylolysis; pedicle screws and rods; cortical bone; cephalad vertebra; congenital dysplasia.

1. INTRODUCTION

Spondylolisthesis is derived from the Greek word spondylos (vertebra) and "olis thesis" (to slip or fall). Spondylolisthesis is defined as the forward slippage of a cephalad vertebra on a caudal vertebra. The term spondylolysis is also derived from the Greek word "lysis" (loosening). Spondylolisthesis refers to a break in the pars interarticularis which is necessary precursor for the listhesis to ensure. In rare instances spondylolisthesis is a consequence of lengthening of the pars without necessary a break especially happening in the congenital variety [1-3].

Herbinaux I, a Belgian Obstetrician is credited with the first description of this condition. In 1982 reported a complete dislocation of the L5 vertebral body in front of the sacrum, with narrowing of the birth canal and resultant problem in delivery. Killian in 1857 coined the term Spondylolisthesis that the slippage occurred gradually secondary to body weight and subluxation of the lumbo-sacral facets [4].

In 1855, Robert reported on anatomic studies involving the neural arch. By removing all soft tissue from the lumbo-sacral junction, he demonstrated that the vertebra would not subluxate as long as the arch was intact. After a defect was made, the vertebra was free to subluxate. In 1858, Lambi proved the existence of a neural arch defect in cadaver specimens. The fact that these defects were not always found in anatomic specimens was resolved by Neugehauer's scholarly work published in 1888. He concluded that spondylolisthesis might arise from a lysis of the pars interarticularis or from the elongation of the neural arch [5-7].

Spondylolisthesis is present in 5% of the adult population with clinical evidence of low back pain. These patients are treated initially by conservative measures, failing of which surgical intervention is contemplated. Numerous studies prove that reduction of severe high grade spondylolisthesis is essential, whereas low grade listhesis depending on the etiology, can be managed by several methods like direct repair of the pars defect in lysis patients or instrumented

posterolateral fusion in situ with or without decompression [8-10].

2. MATERIALS AND METHODS

This is a prospective study of 24 patients carried out in the Department of Orthopaedics, Sree Balaji Medical College and Hospital, Chennai from Nov 2010 to Oct 2012.

2.1 Inclusion Criteria

- Gr I and II listhesis
- Degenerative and Isthmic Spondylolisthesis
- 18 to 60 Years
- Failure of Conservative Management

2.2 Exclusion Criteria

- Age <18 Years
- Age >60 Years
- High Grade Listhesis
- Congenital and Traumatic Listhesis
- Generalised Bone Disorders

Clinical examination and neurological examination was done in all patients and were assessed for sensory motor deficit. All the patients were evaluated by anteroposterior and lateral radiographs of the lumbosacral spine centered at the appropriate level.

In all cases flexion and extension views were taken to assess the instability. More than 4 to 5 mm of sagittal translation and 10 degrees of rotation were considered as instability. All cases were evaluated further by CT/MRI to evaluate facet joint pathology, socialization, and to find the associated disc changes and the nerve root involvement.

All patients were treated by in-situ posterior spinal fusion with pedicle screws and rods and posterolateral bone grafting with or without discectomy/ laminectomy depending on the disc involvement considering that disc pathology may be the cause for the symptoms.

2.3 Surgical Procedure

The patients were operated under general anaesthesia. After induction, patients were

positioned prone on the Rolton-Hall frame. The level of listhesis is confirmed by C-Arm. In some of the Gr I Spondylolisthesis patients, some degree of reduction is achieved spontaneously. However, though reduction is not our criteria, we plan in-situ fusion at the level of listhesis through mid line posterior incision, paraspinal muscles were retracted laterally. Spinous process, lamina and the facet joints were exposed. Further subperiosteal reflection of the muscles exposes the base of the transverse process on either side. Laminectomy/Discectomy of the appropriate level is done when symptoms of spinal stenosis/Disc prolapse or root compression are present.

Since Pedicle Screws traverse all the three columns of the vertebrae, they can rigidly stabilize both the ventral and dorsal aspects of the spine. This pedicle also represents the strongest part of attachment of the spine and the significant forces can be applied to the spine without failure of the bone-metal junction [11-13]. Further, the rigidity of the pedicle fixation allows the incorporation of few normal motion segments in order to achieve stabilization of all the abnormal segments. Pedicle screw fixation does not require dorsal elements. Thus, it can be used after a laminectomy, pars fracture, spinous process fracture and/or facets and thereby improves the fusion rates¹⁶. At the junction of the lateral facet and the transverse processes or intersection of the vertical line through the facet joints as a horizontal line through the transverse process. Lateral and AP radiographs does not guarantee screw placement. Accuracy can be improved by a slide oblique AP view. Pin located in the middle of the pedicle has a characteristic "target sign". Ventral screw penetration is usually between 50% to 80% of AP diameter of the vertebral body. Penetration more than 80% of the vertebral body on the lateral plain X-ray raises the concern of ventral penetration of the vertebral body cortex [14-16].

2.4 Post Operative Protocol

The drainage tubes were removed after 48 hours and the patient is allowed to turn in bed. The sutures are removed on 12th day. Patients were allowed to ambulate after drain removal with a lumbosacral belt and the patient is

discharged with lumbosacral belt. After 3 months the lumbosacral belt is withdrawn gradually.

3. RESULTS

The patients were followed-up at regular intervals, i.e., every month during the first 3 months and there after every 3 months during the first year. The minimum follow up period was 6 months and the maximum follow up was 28 months. The mean follow up in this study of 22 cases were 19 months. During the followup, patients were assessed clinically for pain, spasm and recovery of neurological deficit. Radiologically assessment of spinal fusion was done, percentage of slip correction achieved, slip angle improvement after instrumentation was done using serial X-rays and oblique views [17-19].

The quality of life is assessed by a scanning system called OSWESTRY SCORING INDEX as described subsequently, taking into account the social life which is more important than the radiological indices. Moreover the better radiological indices, does not always correlate with the better scoring indices and vice versa. 20 to 30% improvement of the scoring system during the post op period is considered satisfactory.

Out of the 22 patients, 16 patients(72.72%) had improvement in the OSWESTRY SCORING INDEX significantly in the range above 20%. 5 patients(22.72%) had improvement in the range below 20% and the remaining 1 patient (4.54%) had a deterioration in the oswestry scoring index.

Radiologically, the percentage of slip is maintained in 20 patients (90.90%). Though 2 patients (9.09%) had an increase in the percentage of slip, there was an improvement in the functional index probably due to decompression. One patient (4.54%) had persistent pain in the back due to pseudoarthrosis and was subsequently planned for anterior stabilization. One patient (4.54%) had persistent LS weakness from the pre-op period which failed to recover. Another patient had a pedicle screw back out. One patient (4.54%) had a superficial wound infection in the immediate post-op period which subsided with antibiotics.

Case Illustrations:

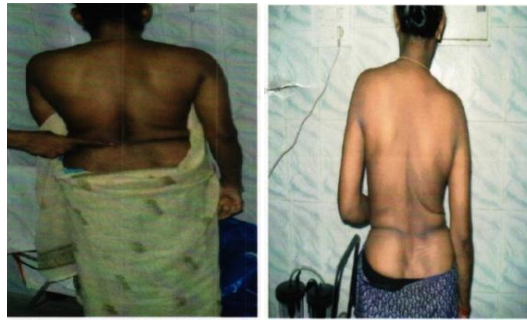

Fig. 1. Clinical photo of the back to show the disappearance of the step

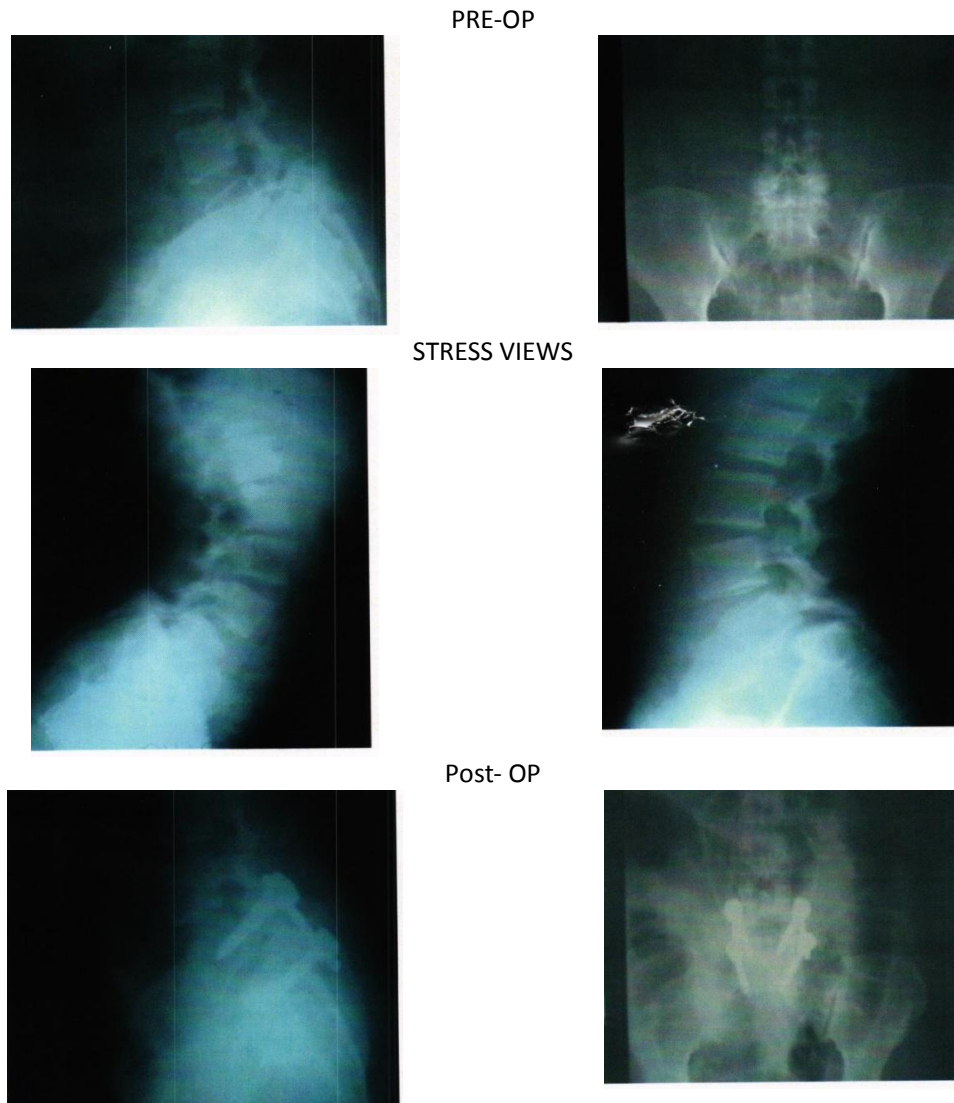
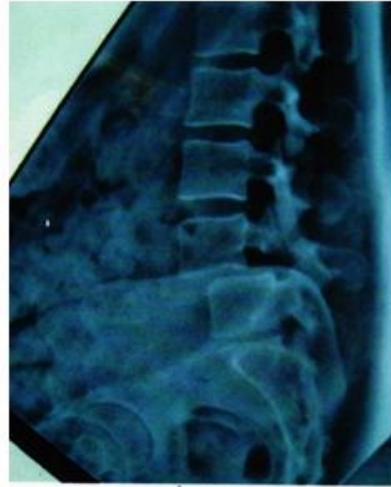
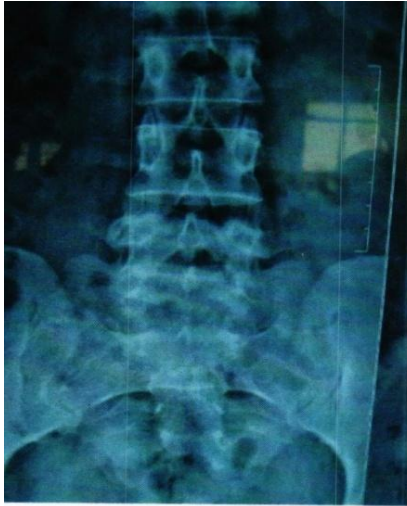
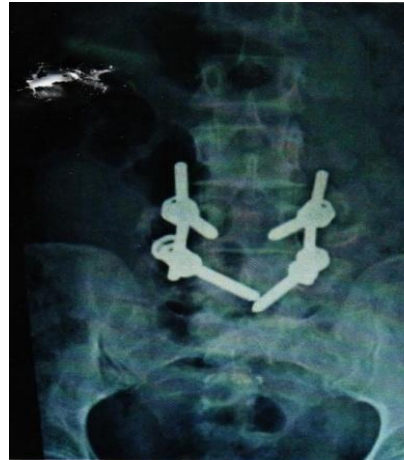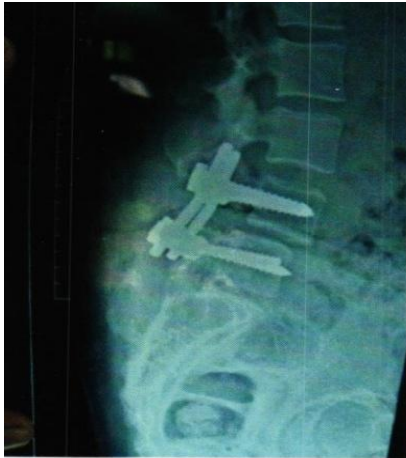Fig. 2. Case I 40/F with GR 1 L5 - Silytic Spondylolisthes/S

PRE-OP



POST- OP



2 Years followup

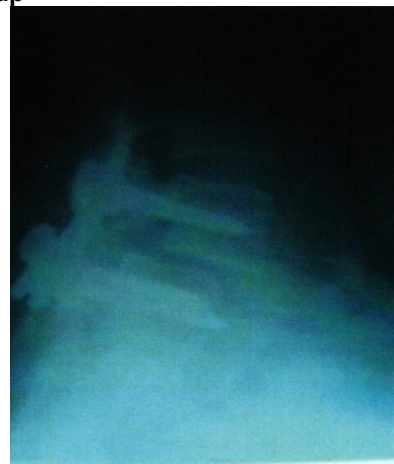
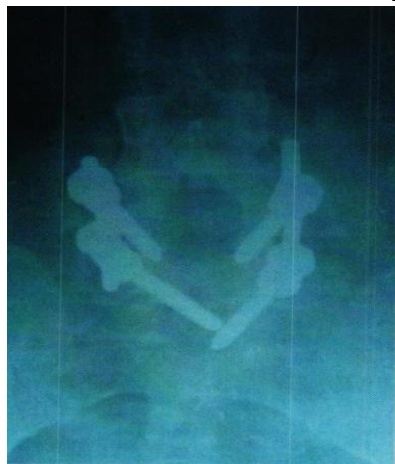
Fig. 3. Case 2. 38/F With Lytic L4- L5 GR 1 Spondylolisthesis

PREOP

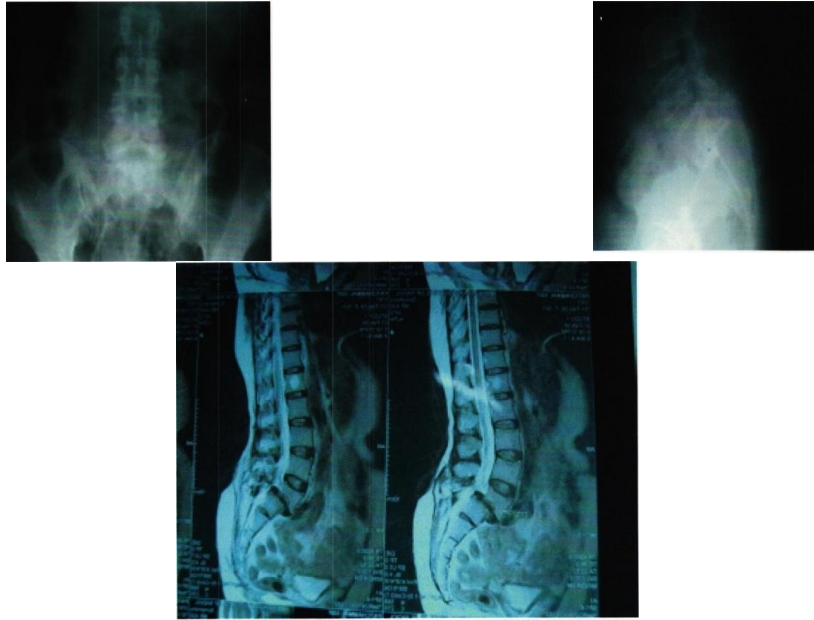


Fig. 4. Case 3. 50/F with Degenerative LS-S1 Spondylolisthesis



Fig. 5. Post Operative Phase

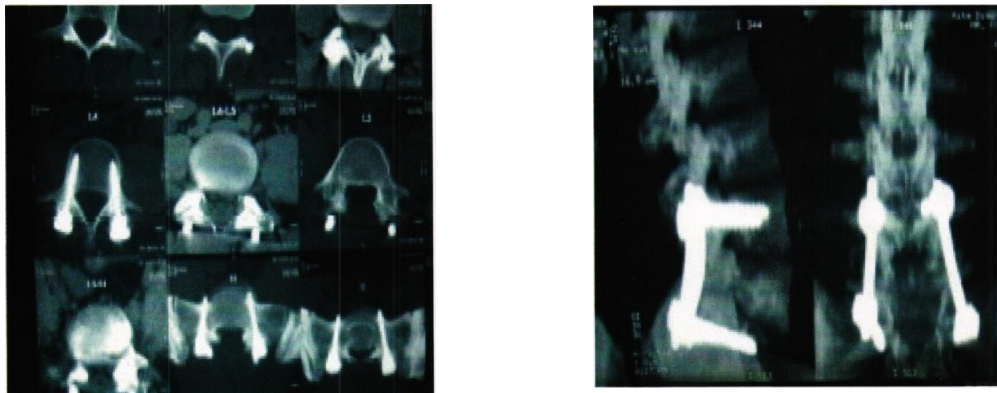


Fig. 6. 2 Years followup

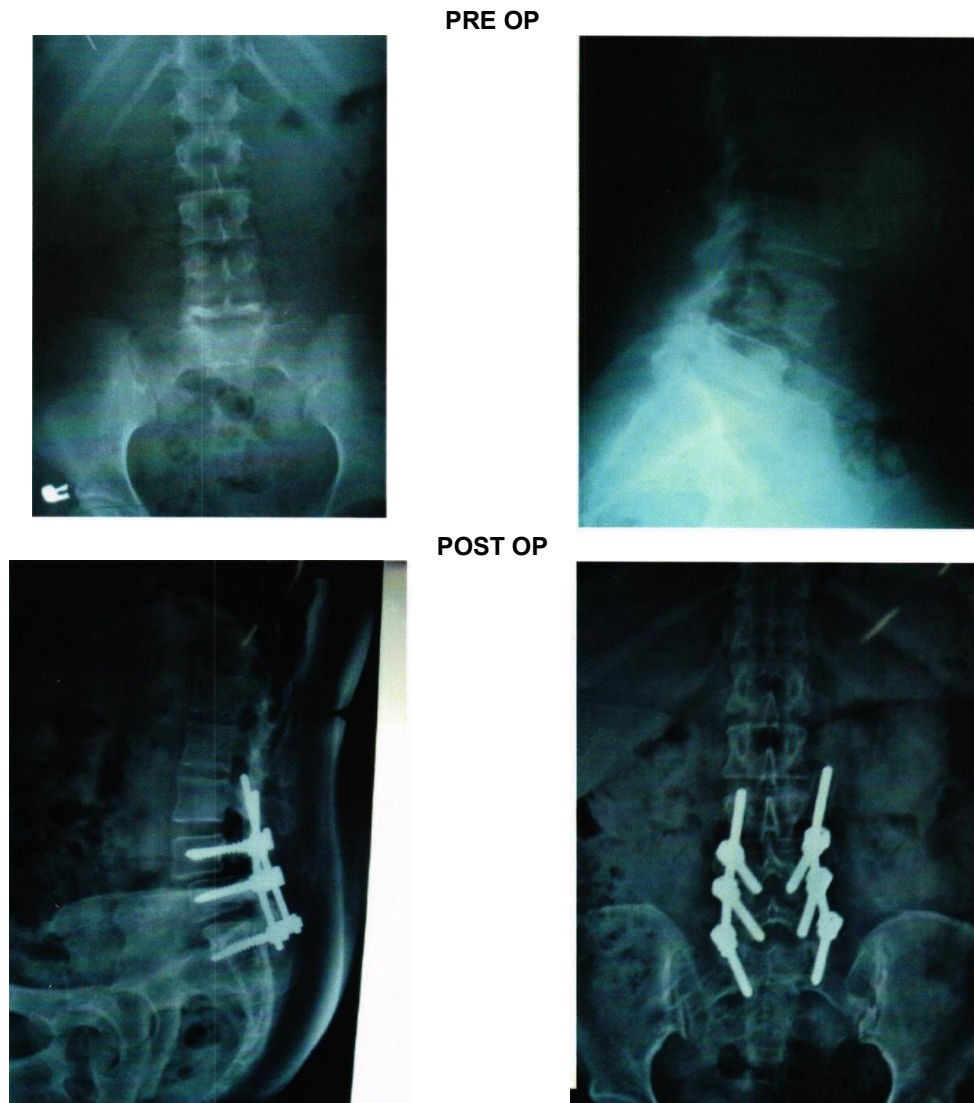


Fig. 7. Case 4. 45/F Degenerative L4 - L5 Spo Dylolisthesis

4. DISCUSSION

Spondylolisthesis is a fascinating condition reported over two centuries ago, with so many different types and degrees of slip. Community prevalence rates for the condition are not known but probably around 5 - 6% in the adult population. Thus widely disparate figures for those who are symptomatic has been reported - 50% in 20. Morscher study [20] and less than 25 % in 21. Nachemson study [21]. It is clear however, that only a small minority of affected individuals ever has symptoms but this proportion increases with severity of slip.

In our study of 22 cases, the mean age of the

patients were found to be 45 years. Many other observations in this study are also comparable to the established facts described in the literature. This includes the overwhelming female preponderance in this condition. (Female - Male Ratio 15: 1) and the fact that spondylolisthesis being commonest in the lower lumbar level. However in our series the sex distribution (F:M was 4.75:1) Dysplastic type of listhesis was uncommon whereas isthmic and degenerative were the commonest [22-24].

The ann of the surgical management in spondylolisthesis are to relieve pain and the neurological deficit, to provide stability and to

prevent its progression by achieving sound fusion. The role of instrumentation is to temporarily achieve reduction and to maintain such reduction until fusion is sound. The role of instrumentation ceases once fusion is solid. If fusion doesn't proceed to soundness there is a likelihood of implant failure due to prolonged fatigue.

In general the younger the patient with painful spondylolisthesis, the more definite is the indication for surgery and the more likely is surgery to be successful. Persistence of symptoms in spite of adequate conservative management constitutes the main indication in our study. 'Risk of progression of slip if not surgically treated' is --often - used surgical indication. However, it is difficult to quantify what the real risk of progressive slipping. In isthmic spondylolisthesis, conservative management is the mainstay of treatment. Only if it fails, surgical management is considered. With the available literature, instrumented in situ posterior spinal fusion is the current method of choice with or without decompression.

Decompressive procedures in spondylolisthesis have their proponents and there are two basic methods - removal of the loose posterior element (Gill's operation) or decompressive laminectomy. In dysplastic and isthmic types a true neurological deficit is rare and radicular symptoms occasionally encountered resolve with solid fusion, along with other symptoms such as hamstring tightness. In our study of 19 cases of isthmic lytic spondylolisthesis, our management involved instrumented in situ posterolateral bone grafting with decompression except in 3 cases where pre op MRJ did not show spinal canal or root compromise.

All patients during their follow up showed an improvement in their clinical and functional outcome, though radiologically, slip were not reduced in about 35% of cases. We are treating the clinical picture rather than radiological picture. Degenerative spondylolisthesis is a special problem, that it produces symptoms of stenosis of either the canal or the lateral recess. Physiotherapy mostly used method to apply non-operative treatment of symptoms associated with Spondylolisthesis. Despite many surgical options existing for the treatment of DS, it is generally agreed that in most cases non-

operative treatment should be attempted before surgical intervention is pursued. Surgical management requires decompression of the appropriate roots by laminectomy and foraminotomy with insitu instrumented fusion with postero lateral bone grafting [21].

In our series of 23 cases except for 3 cases, we did laminectomy and instrumented fusion with excellent results during the follow up. Only one patient with the neurological deficit in pre op also showed no post op improvement in the clinical outcome. The remaining 19 of the 20 patients who had the decompression done simultaneously showed significant clinical improvement. This data corroborates well with the world wide published data that decompression has a definite role in most of the cases of degenerative spondylolisthesis [22].

With regard to spinal fusion, fixation of the unstable spine by posterolateral fusion is the treatment most surgeons prefer. Posterior rather than anterior fusion is preferred by most because its technique is more flexible; it permits exploration of the defects, nerve roots and intervertebral discs.

Another interesting debating point is whether spinal instrumentation is required to improve the results in surgery for spondylolisthesis. Pedicle screw fixation of plates or rods has shown the greatest improvement in the overall fusion rates in adults. Deguchi in their study of 83 cases, concluded that for multilevel spinal fusion in isthmic spondylolisthesis a rigid pedicle screw fixation resulted in a high fusion rate and single level fusion was equally effective with either rigid or semi-rigid pedicle screw instrumentation.

Fishchgrund observed that in patients undergoing single level posterolateral fusion for degenerative spondylolisthesis, the use of pedicle screws may lead to a higher fusion rate but clinical outcome shows no improvement in pain in the back and lower limbs. In our study the fusion rate with pedicle screw instrumentation was 95%. The failure of fusion which occurred in 2 cases could be attributed to inadequate immobilization. In our series 20 out of 23 cases were of the single level fusion type. The one case of implant failures were also of the single level fusion done cases.

Reduction of spondylolisthesis has been reported by many authors using both skeletal traction and instrumentation. There are a number of methods available for improving the degree of spondylolisthesis, but these are not without significant risk of neurological injury. In addition, long term follow-up of fusion in situ even for high grade spondylolisthesis indicates that this is a safe and reliable method of treatment and that very few patients are aware of or complain about their cosmetic appearance in the long term.

In our series most of the patients not only showed solid spinal fusion after insitu posterolateral fusion, but had significant improvement in appearance. With such good results from bilateral in situ intertransverse fusion it is difficult to justify the magnitude and attendant risks of reduction techniques in spondylolisthesis³⁰.

Spondylolysis and Spondylolisthesis are diagnoses that, for most patients have a benign prognosis and can be managed non operatively. For most symptomatic patients for whom this management fails fusion in situ yields satisfactory and long lasting results and remains the gold standard against which other surgical treatment.

5. CONCLUSION

However, this study should further be extended to include PLIF /TLIF/ALIF to produce better clinical results and in high grade spondylolisthesis. Also, it would be interesting to carry out such studies on a wider sample of this type of patients with a significant follow-up. In all modesty we also wish to submit that a 27 month follow up cannot enlist delayed complication such as sub-adjacent vertebral disc degeneration and also sub-adjacent facet joint arthrosis, which may become a later cause of back pain. Such evaluation was beyond the scope of our short term study which we also consider to be its drawback.

CONSENT AND ETHICAL APPROVAL

As per international standard or university standard guideline Patient's consent and ethical approval has been collected and preserved by the authors.

ACKNOWLEDGMENTS

The encouragement and support from Bharath Institute of Higher Education and Research, Chennai, Tamil Nadu, India is gratefully acknowledged for providing the laboratory facilities to carry out the research work.

COMPETING INTERESTS

Author has declared that no competing interests exist.

REFERENCES

1. Frymoyer JW. Segmental instability. Rationale for treatment. Spine 1985; 10(4): 325-327.
2. Boden SD, et al. Orientation of the lumbar facet joints: association with degenerative disc disease. J Bone Joint Surg. 1996;78(3):403- 411.
3. Gill GO, Manning JG, White HL. Surgical treatment of spondylo I is thesis without spinal fusion. J Bone Joint Surg Am. 1955;37:493-518.
4. Kim NH, Lee JW. Anterior interbody fusion versus posterolateral with transpedicular fixation for isthmi spondy loli sthesi s in adults. A comparison of clinical results. Spine 1999; 24: 812-817.
5. McAfee PC, et al. Anterior BAK instrumentation and fusion: complete versus partial discectomy. Clin Orthop. 2002;(394):55-63.
6. Lin PM, Cautilli RA, Joyce MF. Posterior lumbar interbody fusion. Clin Orthop. 1983;(180): 154-168.
7. Lin PM. Posterior lumbar interbody fusion technique: complications and pitfalls. Clin Orthop. 1985;(193):90-102.
8. Okuyama K, et al. posterior lumbar int erbody fusion: a retrospective study of complications after facet joint excision and pedicle screw fixation in 148 cases. Acta Ortho Scand. 1999;70(4):329-334.
9. Humphreys SC, et al. Comparison of posterior and transforaminal approaches to lumbar interbody fusion. Spine. 2001;26(5):567-571.
10. Harms J; Tabasso G. spondylolisthesis. In: Harms J, Tabasso G, eds. Instrumented spinal surgery: principles and technique. Stuttgart: Thieme; 1999.
11. Herb in aux, G. Traite sur divers: la borieu et sur les polipe de la matrice.

- Brussels: J.L.De Boubers; 1782.
12. Roy-Camille R, Demeulenaere C. Osteosynthese du rachis dorsal, lombaire et lombo-sacre par plaques metalliques vissees dans les pe Vertebrae et les apophyses articulaires. Presse Med. 1970;78:1447-1450.
 13. Zdeblick TA. A prospective, randomized study of lumbar fusion. Spine. 1993;18:983-991.
 14. Peffer HL, Wiesel SW, Cuckler JM, Rothman RH. Degenerative spondylolisthesis: to fuse or no fuse. Spine. 1985;10:287-289.
 15. Cloward RB. The treatment of ruptured lumbar intervertebral disc by vertebral body fusion: indications, operative technique, after care. J Neurosurg. 1953;10:195-202.
 16. Lehman Tr, Spratt KF, Tozzi JE et al. Long-term follow-up of lumbar fusion patients. Spine. 1987;12:97-104
 17. Mihara H, Onari K, Cheng BC et al. The biomechanical effects of spondylolysis and its treatment. Spine. 2003;28:235-238.
 18. Morscher E, Gerber B, Fasel J. Surgical treatment of spondylolisthesis by bone grafting and direct stabilization of spondylolysis by means of a hook screw. Acta Orthop Trauma Surg. 1984;03:175-178.
 19. Nachemson A. Repair of the spondylolisthetic defect and intertransverse fusion for young patients. Clin Orthop. 1971;101-105. Nicol R, Scott J. Lytic spondylolysis, repair by wiring. Spine. 1986;6;11:1027-1030.
 20. Ohmori K, Suzuki K, Ishida Y. Translaminar pedicular screw fixation with bone grafting for symptomatic isthmic lumbar spondylolysis. Neurosurgery. 1992;30:379-384
 21. Pavlovic V. Surgical treatment of spondylolysis and spondylolisthesis with a hook screw. Int Orthop. 1994;18:69.
 22. Pedersen A, Hagen R. Spondylolysis and spondylolisthesis: treatment by internal fixation and bone grafting of the defect. J Bone Joint Surg [Am]. 1988;70:15-24.
 23. Pavlovic V. Surgical treatment of spondylolysis and spondylolisthesis with a hook screw. Int Orthop. 1994;18:69
 24. Pedersen A, Hagen R. Spondylolysis and spondylolisthesis: treatment by internal fixation and bone grafting of the defect. J Bone Joint Surg [Am]. 1988;70:15-24.

© 2021 Manivannan; This is an Open Access article distributed under the terms of the Creative Commons Attribution License (<http://creativecommons.org/licenses/by/4.0>), which permits unrestricted use, distribution, and reproduction in any medium, provided the original work is properly cited

Peer-review history:

*The peer review history for this paper can be accessed here:
<https://www.sdiarticle4.com/review-history/72111>*