



# Optimizing Anesthesia Care in TAVR Patients: A Case Report and Review of Literature against Indian Scenario

Amruta Datye <sup>a\*</sup> and Ravikant Patil <sup>b++</sup>

<sup>a</sup> Chief Intensivist Sevasadan Lifeline Superspeciality Hospital, Miraj (SSLSH), India.

<sup>b</sup> Department of Cardiology, SSLSH, Miraj, India.

## Authors' contributions

This work was carried out in collaboration between both authors. Both authors read and approved the final manuscript.

## Article Information

DOI: <https://doi.org/10.9734/jammr/2024/v36i75519>

## Open Peer Review History:

This journal follows the Advanced Open Peer Review policy. Identity of the Reviewers, Editor(s) and additional Reviewers, peer review comments, different versions of the manuscript, comments of the editors, etc are available here: <https://www.sdiarticle5.com/review-history/119805>

Case Report

Received: 05/05/2024

Accepted: 13/07/2024

Published: 16/07/2024

## ABSTRACT

TAVR has now been accepted across the globe as a standard treatment in management of severe AS. The procedure got simpler over past two decades with newer and advanced generation valves and deployment techniques. Similarly, with evolved anesthesia techniques, peri-operative optimization and adoption of minimalist approach has considerably reduced the complications, shorten the stay and reduced all-cause morbidity and mortality.

India has seen surge in patients undergoing TAVR after first procedure in 2011. However, various factors economic, physician learning curve, demography seem to play a role in widespread adoption of this form of treatment.

Keywords: TAVR; peri-operative; optimizing anesthesia; conscious sedation.

++ DM, FSCAI, FACC and Chief Interventional Cardiologist;

\*Corresponding author: E-mail: [avdatye@gmail.com](mailto:avdatye@gmail.com);

Cite as: Datye, Amruta, and Ravikant Patil. 2024. "Optimizing Anesthesia Care in TAVR Patients: A Case Report and Review of Literature Against Indian Scenario". *Journal of Advances in Medicine and Medical Research* 36 (7):430-35. <https://doi.org/10.9734/jammr/2024/v36i75519>.

## **ABBREVIATIONS**

<i>TAVR</i>	: <i>Trans Catheter Aortic Valve Replacement</i>
<i>AS</i>	: <i>Aortic Stenosis</i>
<i>CAG</i>	: <i>Coronary Angiography</i>
<i>TTE</i>	: <i>Transthoracic Echocardiography</i>
<i>CT</i>	: <i>Computed Tomography</i>
<i>TR</i>	: <i>Tricuspid Regurgitation</i>
<i>PA</i>	: <i>Pulmonary Artery</i>
<i>TEE</i>	: <i>Transoesophageal Echocardiography</i>
<i>LMCA</i>	: <i>Left Main Coronary Artery</i>
<i>COPD</i>	: <i>Chronic Obstructive Pulmonary Disease</i>
<i>MAC</i>	: <i>Modified Anesthesia Care</i>
<i>GA</i>	: <i>General Anesthesia</i>
<i>LAD</i>	: <i>Left Anterior Descending</i>

## **1. INTRODUCTION**

TAVR has now been accepted across the globe as a standard treatment in management of severe AS. The procedure got simpler over past two decades with newer and advanced generation valves and deployment techniques. Similarly, with evolved anesthesia techniques, peri-operative optimization and adoption of minimalist approach has considerably reduced the complications, shorten the stay and reduced all-cause morbidity and mortality.

We report an interesting case of TAVR wherein procedural and patient complexities were overcome using FAST or minimally invasive strategy with a positive outcome. [1,2].

## **2. CASE REPORT**

84-year female, weight 40 kg presented with repeated syncopal attacks since 2-3 months. She was diagnosed moderate aortic stenosis (AS) and was on treatment for same since 8 years. The symptoms which had started from mild breathlessness on and off progressed to grade III dyspnea, intermittent angina and recent episodes of syncopal attacks. 2D echo showed a severe AS valve area < 1.0 sq cm with a gradient of 60 mmHg. Mild TR was noted with mild elevation of PA pressures. No vegetation, calcification seen.

All necessary investigations TEE, CT aortogram and CAG were done, for assessment and feasibility of procedure. Bicuspid valve and short LMCA were identified as potential procedural complications. A routine PAC done, the high risk indicators were flagged as: age, severe AS,

COPD. All other parameters were normal. Peri-operative goals were set for this patient. It included pre-operative stabilization of COPD. Cardiac medications diuretic, rate limiter was continued. EUROSCOREII was 6; intermediate or moderate risk noted. Routine NBM orders, antibiotic prophylaxis was advised. Patient was given mild anxiolytic previous night.

A written informed signed consent obtained. As a unique approach to standard protocol TAVR through femoral access, right radial artery cannulation for pigtail insertion was used for invasive blood pressure monitoring. Left femoral vein used for insertion for transvenous pacing wires was also utilized for inotropic support infusions. Thus, duplication of invasive lines was avoided. Continuous hemodynamic monitoring with invasive pressure recording was done.

Prior to serial dilatation for femoral approach injection midazolam 0.5 mg intravenous along with injection fentanyl 50 micrograms was given. Further, aliquots of injection propofol 10 mg intravenous was given at each step 1) balloon dilatation 2) high ventricular pacing 3) deployment. Inotropic support was adjusted to maintain a mean MAP of 70.

Intraoperatively, it was noticed that the valve could impinge the left coronary blood supply and hence was decided to save the coronary by stenting left main to LAD. During this intervention, apart from single dose of 10mg propofol intravenous, no other drug was repeated. Inotropic support had to increase to injection noradrenaline from 0.2-05 mics/kg/min. Adequate urine output was ensured. The deployment of valve was uneventful and gradient immediately reduced to below.

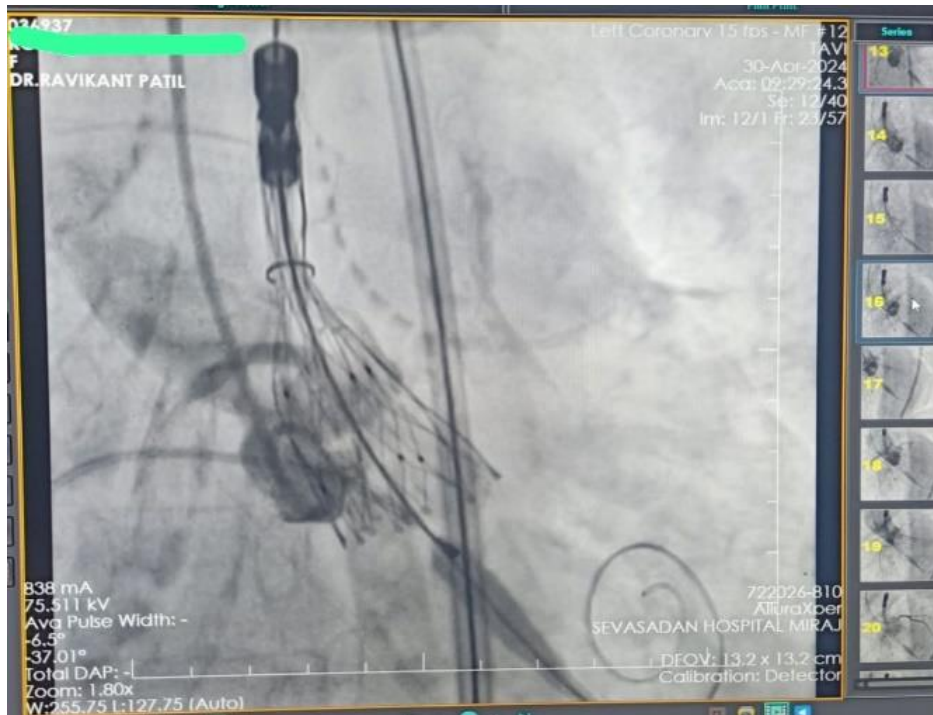


Fig. 1. Deployment of valve

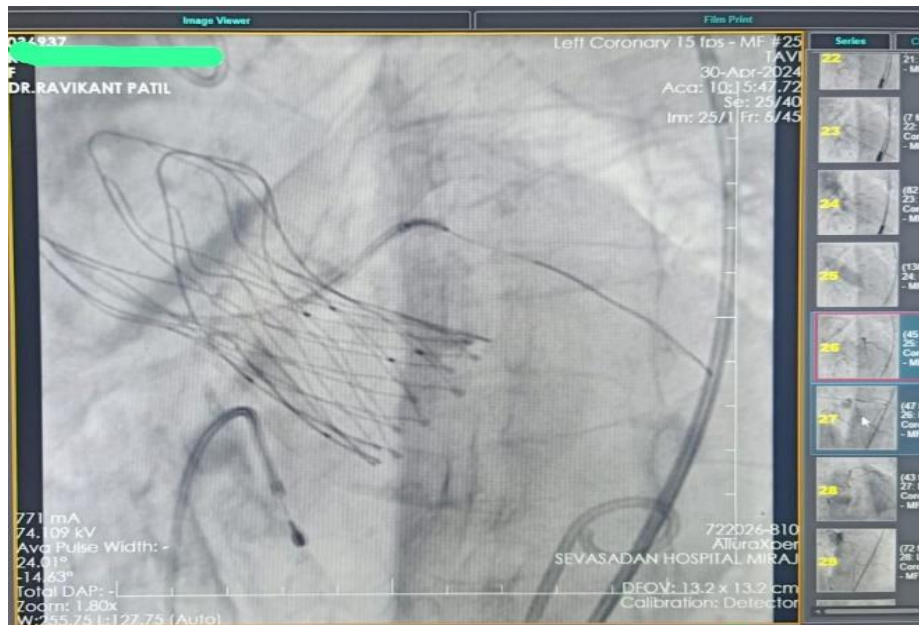

Fig. 2. LMCA stenting

Modified Richmond Agitation Sedation (RAAS) scoring was used during intraoperative procedure to monitor sedation. The propofol and fentanyl aliquots were given to maintain a RASS of 0 to -2. The total propofol used was 40 mg and fentanyl required was 80 micrograms. The entire procedure took two and half hours due to surgical nuances bicuspid valve and short LMCA

which were overcome by expertise and it went well. Check fluoroscopy revealed perfect alignment of valve and TIMI III flow through stent.

Post operatively, patient was shifted on minimal supports to coronary care unit awake with RAAS of 1. TTE next day morning was done to confirm valve placement and gradient, which was

acceptable. Having tapered the supports over 24 hours, with a screen echo the next day patient was shifted to room at 48 hours and discharged at 72 hours. No cognitive dysfunction was observed on discharge or a follow up through 90 days.

### **3. DISCUSSION**

TAVR has revolutionized treatment standards in elderly, symptomatic patients with severe disease posing intermediate to high risk for open surgery. Refinement in valve quality, advance techniques of delivery and deployment systems along with impeccable operator proficiency has greatly reduced the complications post procedure.

Anesthesiologist have also adopted minimally invasive and fast tracking techniques to reduce post –op morbidity. Lefèvre G et al<sup>1</sup>, in his study compared standard approach versus minimally invasive FAST approach for patients undergoing TAVR. FAST strategy consisted of local anesthesia with conscious sedation, USG guided TF puncture for main vascular access, radial approach for secondary arterial access, and left ventricular guidewire rapid pacing. Results showed lower rate of iatrogenic complications and shorter stay.

In another study by Sawan MA et al [2], reviewed the current minimalist TAVR care pathways. The summary gave a strong recommendation for procedural sedation, peri-operative optimization, for shorter stay and reduced cost. However, the study failed to categorize the patients' eligibility for fast-tracking or set certain protocols. This requires additional data and study.

Fröhlich GM et al [3], in a systematic meta-analysis for local anesthesia versus general for TAVR patients, analyzed data over eight years and 1542 patients. It was concluded that there is no significant difference in short-term outcomes for MAC or GA. MAC was associated with lower procedural times and shorter hospital stay. However, none of the studies were randomized control trials and needs further data validation for same.

Multiple studies have used ketamine, propofol, fentanyl, remifentanyl, midazolam drugs in combination for conscious sedation. There was no significant change in 60-day outcomes with these combinations. Although patient physiology, co-morbidities, renal and liver function tests

along with hemodynamic stability play an important role in choosing the combination, propofol + dexmedetomidine infusion has been recently the drug of choice for TAVR. Dosage adjustment to prevent post –op delirium needs to be considered when using sedative hypnotics as all patients are elderly. However, hemodynamic stability, analgesia with minimal side effects on priority is preferred for MAC during TAVR [4-7].

Our aim in using conscious sedation for our patient with minimally invasive strategy thus delivered us the desired outcome. There was significant intra-operative surgical difficulty, bicuspid valve which hinders deployment and stability was addressed. Also, coronary protection by stenting LMCA was required and short LMCA posed quite a problem. Despite these shortcomings, there were no vascular complications post-operatively and patient was mobilized and discharged within 72 hours. A 60day follow-up was uneventful.

Sato K et al [8], in their study tried to analyse the anesthesia protocol in depth. The study did reinforce the fact that MAC preferred over GA for lower complication rate, shorter stay and early recovery. However, the limitations found by this study were 1) patient selection criteria for MAC and GA were not clear 2) no data regarding conversion from MAC to GA 3) no consensus over sedation strategies 4) required more of RCTs and data for same.

#### **3.1 Indian Scenario**

India got its first TAVR in 2011 and since then it has been a slow progress with respect to adaptability and promotion of this procedure at multiple levels. Though India boasts of maximum peripheral Cath-labs, including stand-alone; up until 2020 only 30 centres were actively doing TAVR. The number has significantly increased since. A recent study estimated the case load for TAVR in India to be 0.25-0.3 million, based on incidence of AS and extrapolation of western data.

In the same study authors Gupta P et al [9], identify racial differentiation mainly peripheral vascular diameters, low BSA, higher incidence of rheumatic valvular heart disease, higher incidence of BAV as factors affecting acceptance of TAVR. This was further endorsed by Lee C et al [10-13] in their study on Asian population and TAVR.

The most important factor causing hindrance in wide spread acceptance is cost factor. It is estimated that cost is around \$35,000 in India for TAVR which is almost half of that in western world. However, when not even 5% of private TPA in India can afford this cost, coverage in government schemes is way beyond for now [14-16].

Another significant factor remains the steep curve of learning amongst interventional cardiologist and anesthesiologist also. Various European establishments now offer fellowships for the same SCAI etc [17,18].

The ray of hope here however is approval of two indigenous companies by regulatory for valve manufacturing and usage which may significantly lower the cost of the valve and thereby entire procedure.

#### 4. CONCLUSION

TAVR is accepted as standard treatment in management of severe aortic stenosis benefiting cases otherwise unfit for open surgical intervention. With advances in techniques and newer valve generations, the outcomes show significant improvement. Anesthesia optimization will further enhance the outcome as it directly affects the peri-operative recovery. Considering the Indian scenario, there is a tremendous scope for widespread adaptation of TAVR with two changes; number of expert interventional cardiologists doing procedures should increase and the apparatus should become cost effective.

#### DISCLAIMER (ARTIFICIAL INTELLIGENCE)

Author(s) hereby declare that NO generative AI technologies such as Large Language Models (ChatGPT, COPILOT, etc) and text-to-image generators have been used during writing or editing of manuscripts.

#### CONSENT

As per international standards or university standards, patient(s) written consent has been collected and preserved by the author(s).

#### ETHICAL APPROVAL

As per international standards or university standards written ethical approval has been collected and preserved by the author(s).

#### COMPETING INTERESTS

Authors have declared that no competing interests exist.

#### REFERENCES

1. Sawan MA, Calhoun AE, Grubb KJ, Devireddy CM. Update on minimalist TAVR care pathways: Approaches to care in 2022. *Curr Cardiol Rep.* 2022 Sep;24(9):1179-1187. DOI: 10.1007/s11886-022-01737-x. EPUB 2022 Jun 29. PMID: 35767177. PMCID: PMC9244066.
2. Lefèvre G, Jégou A, Dambrin G, Picard F, Anconina J, Pouzet B, Guesnier L, Cheikh Khelifa R, Hilpert L, Doan HL, Favereau X. Comparison of transfemoral transcatheter aortic valve replacement performed with a minimally invasive simplified technique: FAST Versus a Standard Approach. *J Invasive Cardiol.* 2019;31(10):300-306. PMID: 31567114.
3. Fröhlich GM, Lansky AJ, Webb J, Roffi M, Toggweiler S, Reinthaler M, Wang D, Hutchinson N, Wendler O, Hildick-Smith D, Meier P. Local versus general anesthesia for transcatheter aortic valve implantation (TAVR)--systematic review and meta-analysis. *BMC Med.* 2014 ;12:41. DOI: 10.1186/1741-7015-12-41 PMID: 24612945; PMCID: PMC4022332.
4. Motloch LJ, Rottlaender D, Reda S. Local versus general anesthesia for transfemoral aortic valve implantation. *Clinical Research in Cardiology.* 2012;101(1):45–53. DOI: 10.1007/s00392-011-0362-8
5. Kronfli AP, Lehman E, Yamane K, Roberts SM, Cios T. J. dexmedetomidine is an equal cost alternative to propofol in transcatheter aortic valve replacement, with equivalent in-hospital and 30-day outcomes. *Journal of Cardiothoracic and Vascular Anesthesia.* 2021;35(2):439–445. DOI: 10.1053/j.jvca.2020.08.039
6. Zhao CB, Yu J, Kong M, Han J, Du H, Huang J. Ketamine for monitored anesthesia care during transcatheter aortic valve replacement. *Journal of PeriAnesthesia Nursing .* 2022;37(2):234–237. DOI: 10.1016/j.jopan.2021.06.007
7. Fadah K, Khalafi S, Corey M, Sotelo J, Farag A, Siddiqui T, Abolbashari M. Optimizing anesthetic selection in transcatheter aortic valve replacement:

- striking a delicate balance between efficacy and minimal intervention. *Cardiol Res Pract.* 2024;2024:4217162.  
DOI: 10.1155/2024/4217162.  
PMID: 38454917; PMCID: PMC10919973
8. Sato K, Jones PM. Sedation versus general anesthesia for transcatheter aortic valve replacement. *J Thorac Dis.* 2018;10(Suppl 30):S3588-S3594.  
DOI: 10.21037/jtd.2018.08.89.  
PMID: 30505539; PMCID: PMC6242923.
  9. Gupta P, Arora S, Qamar A, Gupta M, Seth A. Current status of transcatheter aortic valve replacement in India. *Cardiovasc Diagn Ther.* 2020;10(1):83-88.  
DOI: 10.21037/cdt.2019.05.04.  
PMID: 32175230; PMCID: PMC7044098.
  10. Lee C, Inohara T, Hayashida K. Transcatheter aortic valve replacement in asia: present status and future perspectives. *JACC: Asia.* 2021;1(3):279–293.
  11. Prendiville T, Tanner R, Jacobsen AP, Margey R, McGorrian C, Casserly IP. Safety of conscious sedation for transcatheter aortic valve replacement without an anesthetist. *J Invasive Cardiol.* 2021;33(3):E220-E224.  
EPUB: 2021 Feb 4.  
PMID: 33542161.
  12. Afshar AH, Pourafkari L, Nader ND. Periprocedural considerations of transcatheter aortic valve implantation for anesthesiologists. *Journal of Cardiovascular and Thoracic Research.* 2016;8(2):49–55.  
DOI: 10.15171/jcvtr.2016.10
  13. Behan M, Haworth P, Hutchinson N, Trivedi U, Laborde JC, Hildick-Smith D. Percutaneous aortic valve implants under sedation: Our initial experience. *Catheterization and Cardiovascular Interventions.* 2008;72(7):1012–1015.  
DOI: 10.1002/ccd.21777
  14. Ahmad M, Patel JN, Vipparthy SC, Divecha C, Barzallo PX, Kim M, Schrader SC, Barzallo M, Mungee S. Conscious sedation versus general anesthesia in transcatheter aortic valve replacement: A cost and outcome analysis. *Cureus.* 2019;11(6):e4812.  
DOI: 10.7759/cureus.4812.  
PMID: 31281765; PMCID: PMC6599466
  15. Husser O, Fujita B, Hengstenberg C. Conscious sedation versus general anesthesia in transcatheter aortic valve replacement: the German aortic valve registry. *Journal of the American College of Cardiology: Cardiovascular Interventions.* 2018;11(6):567–578.  
DOI: 10.1016/j.jcin.2017.12.019.
  16. Hinkelbein J, Lamperti M, Akeson J. European society of anaesthesiology and european board of anaesthesiology guidelines for procedural sedation and analgesia in adults. *Eur J Anaesthesiol.* 2018;35:6-24.
  17. Petronio AS, Giannini C, De Carlo M. Anaesthetic management of transcatheter aortic valve implantation: results from the Italian CoreValve registry. *EuroIntervention.* 2016;12:381-8.  
DOI: 10.4244/EIJY15M03\_05
  18. Ichibori Y, Li J, Patel T, Lipinski J, Ladas T, Saric P, Kobe D, Tsushima T, Peters M, Patel S, Davis A, Markowitz AH, Bezerra HG, Costa MA, Kalra A, Attizzani GF. Short-term and long-term outcomes of patients undergoing urgent transcatheter aortic valve replacement under a minimalist strategy. *J Invasive Cardiol.* 2019;31(2):E30-E36.  
PMID: 30700628.

**Disclaimer/Publisher's Note:** The statements, opinions and data contained in all publications are solely those of the individual author(s) and contributor(s) and not of the publisher and/or the editor(s). This publisher and/or the editor(s) disclaim responsibility for any injury to people or property resulting from any ideas, methods, instructions or products referred to in the content.

© Copyright (2024): Author(s). The licensee is the journal publisher. This is an Open Access article distributed under the terms of the Creative Commons Attribution License (<http://creativecommons.org/licenses/by/4.0>), which permits unrestricted use, distribution, and reproduction in any medium, provided the original work is properly cited.

*Peer-review history:*  
The peer review history for this paper can be accessed here:  
<https://www.sdiarticle5.com/review-history/119805>