



# **Effectiveness of Knotless Barbed Sutures for Intraoral Closure after Impacted Mandibular Third Molar Surgery: A Split Mouth Randomized Clinical Trial**

**Sneha Krishnan<sup>a</sup>, Senthilnathan Periasamy<sup>a≡</sup> and M. P. Santhosh Kumar<sup>a\*#</sup>**

<sup>a</sup> Department of Oral and Maxillofacial Surgery, Saveetha Dental College and Hospital, Saveetha Institute of Medical and Technical Sciences, Saveetha University, Chennai-77, India.

## **Authors' contributions**

*This work was carried out in collaboration among all authors. All authors read and approved the final manuscript.*

## **Article Information**

DOI: 10.9734/JPRI/2022/v34i3A35385

## **Open Peer Review History:**

This journal follows the Advanced Open Peer Review policy. Identity of the Reviewers, Editor(s) and additional Reviewers, peer review comments, different versions of the manuscript, comments of the editors, etc are available here: <https://www.sdiarticle5.com/review-history/82023>

**Received 18 November 2021**

**Accepted 20 January 2022**

**Published 22 January 2022**

**Original Research Article**

## **ABSTRACT**

**Objectives:** The purpose of this clinical trial is to assess the efficiency of 3-0 knotless barbed suture (polydioxanone) with 4-0 polyglactin 910 (vicryl) in wound closure following impacted mandibular third molar surgery.

**Methods:** The split-mouth study involved 20 patients who were referred to the Oral Surgery Clinic at the Department of Oral and Maxillofacial Surgery for bilateral mandibular third molar impaction with equal difficulty index. Simple randomization was used to distribute the samples. Following extraction, the wounds were closed with 3-0 knotless sutures for the study group and 4-0 polyglactin 910 (vicryl) for the control group. Following surgical extraction in relation to impacted mandibular molars under local anesthesia, the clinical outcome parameters that were measured were (1) time taken to achieve wound closure and hemostasis, and (2) post-operative wound healing using "Landry's wound healing index" on the 1st, 3rd, and 7th post-operative days.

**Results:** In this study, we discovered that the average time taken to approximate a wound was 2.69 minutes for the study group and 4.27 minutes for the control group. The research and control groups had a statistically significant difference in suturing time (p-value < 0.05). On all postoperative

<sup>≡</sup> Professor and HOD;

<sup>#</sup> Professor;

<sup>\*</sup>Corresponding author: E-mail: [santhoshsurgeon@gmail.com](mailto:santhoshsurgeon@gmail.com);

review days, wound healing in the study group was shown to be better and statistically significant than in the control group (p-value <0.05).

**Conclusion:** Within the limitations of the present study, knotless barbed suture is a promising alternative to conventional sutures for intra-oral wound closure as it reduces suturing time and facilitates effective wound closure following surgical removal of impacted mandibular third molars.

*Keywords: Third molar; knotless sutures; barbed sutures; mandibular molar; intraoperative time; wound healing; polyglactin 910 suture.*

## 1. INTRODUCTION

To bind the suture material to the tissues and maintain proper tension at the approximated wound boundary, traditional suturing needs the application of knots [1,2]. Surgical knots are merely a necessary evil for anchoring smooth sutures so that they can do its purpose of tissue re-approximation [3]. Suturing after maxillofacial surgery procedures has a number of technical challenges, including limited access, equipment issues, and knot securing difficulties [4]. Surgical knots can cause a variety of knot-related problems, such as infection and soft tissue irritation since they act as a nidus for food debris to collect.

The following goals should be achieved with intraoral suturing in maxillofacial surgery: re-adaptation and maintenance of surgical flaps in normal anatomical position to facilitate wound healing, providing water-tight closure to avoid contamination of the surgical site by saliva and food debris, and preventing implant exposure, [5–7] as well as providing enough resistance to the dynamic peri-oral muscles [7].

The most common operation performed by a maxillofacial surgeon is the surgical removal of an impacted third molar [8]. Suturing is used to close the wound after the impacted third molar is removed. Suturing after mandibular third molar surgery, on the other hand, poses the following technical challenges: restricted access, instrumentation challenges, and knot securing challenges [7]. Furthermore, several knot-related problems, such as the collection of food debris leading to infection and soft tissue irritation, have been recorded in the literature [7,9] Furthermore, the knots may create ischemia as a result of the added pressure, making the wound more susceptible to infection. Suturing errors can lead to wound dehiscence, infection, and post-operative discomfort [10].

Knotless suturing is a cutting-edge wound closure technique used in bariatric surgery [11],

abdominoplasty [12], facial rejuvenation procedures [13], arthrotomy [14], laparoscopic myomectomy [15], partial nephrectomy [16], as well as in a variety of minimally invasive techniques. The configuration allows the suture to be self-anchoring, allowing close approximation of tissue while resisting the migration that can occur with swelling.

Previously our team had a rich experience in working on various research projects across multiple disciplines [17–31]. We decided to explore this project because of the growing trend in this field. We hope to evaluate the efficiency of knotless barbed sutures for intraoral wound closure following surgical removal of an impacted mandibular third tooth based on this motivation. This study compares the time it takes for a knotless barbed suture to close a wound during surgery and the time it takes for a wound to heal when knotless barbed sutures are used vs traditional vicryl sutures in minor oral surgery.

## 2. MATERIALS AND METHODS

### 2.1 Study Setup

This randomised prospective controlled clinical study was done among patients who visited the Oral Surgery Clinic's outpatient dental department between June 2020 and March 2021. The study comprised 20 adult patients who were chosen at random after being referred to the oral and maxillofacial surgery department for surgical removal of bilateral impacted mandibular third molars. Patients with similar difficulty indexes were enrolled for this clinical investigation based on preoperative orthopantomogram assessment, according to Pell and Gregory classification-Position A, Class I. The 'split-mouth study' was used in the investigation, with one side of the mouth assigned to Knotless suture (study group) and the contra-lateral side to polyglactin 910 suture (control group). One month following the first surgery, the affected molars in the opposite arch were removed.

Intraoperative wound closure was achieved in the Study group using 3-0 knotless barbed suture. Polyglactin 910 suture was used to close the wounds intraoperatively in the Control group.

## 2.2 Inclusion Criteria

- Patients between 18 years-50 years of age
- Both genders
- Patients who fall within the ASA 1 (American Society of Anaesthesiology) classification
- Patients with clinical and radiological records indicating that bilaterally impacted mandibular third molars require surgical removal.
- Patients with similar difficulty indexes of impacted teeth- Position A, Class I, Pell and Gregory categorization, and willingness to undertake surgical procedure

## 2.3 Exclusion Criteria

- Patients with incomplete clinical and radiological records.
- Patients with severe systemic conditions like diabetes and hypertension.
- Patients who have taken anticoagulant medication in the past or who have a history of lignocaine allergy

## 2.4 Procedure

The affected teeth were surgically removed under local anaesthesia. The surgical procedure was standardised as follows: inferior alveolar and buccal nerve blocks with 2% lignocaine hydrochloride and 1:80,000 adrenaline bitartrate. A mucoperiosteal flap was raised using a traditional Ward's incision [32]. For surgical exposure and delivery of the tooth, bone was removed with a surgical drill under cold saline irrigation. For the control group, haemostasis was accomplished and wound closure was performed using 4-0 polyglactin 910 suture (Ethicon Inc., Somerville, NJ, USA) (dyed) and 3-0 knotless suture (Ethicon Inc., Somerville, NJ, USA). (Covidien V-loc 90 knotless absorbable wound closure device) [Fig. 1] for the study research group respectively. For the polyglactin 910 group, suturing was done with two simple, interrupted sutures. Suturing was done in the knotless group using a continuous suturing approach from the distal end of the wound (2nd molar) to the proximal end. The barbs were pushed deeper into the tissues, and the wound

borders were firmly approximated. The sutures were then snipped closer to the tissues, leaving no suture material exposed in the mouth cavity [4].

## 2.5 Diagnostic Criteria

1. Intraoperative wound closure time: Using a stopmatch, the time it took to finish the suturing was measured in minutes.
2. Post-operative mucosal wound healing on the first, third, and seventh post-operative days, post-operative wound healing was examined using "Landry's wound healing index." Tissue colour, responsiveness to probing (bleeding), presence of granulation tissue, incision margin (epithelialization and exposure of connective tissue), and suppuration (present/absent) were all used to evaluate the wounds. The wound healing scores range from 1 to 5, with very bad (1), poor (2), decent (3), very good (4), and exceptional wound healing being the highest (5).

## 2.6 Study Parameters

For the purposes of the study, the following data were extracted:

- The patient's age
- The patient's gender
- Intraoperative wound closure time
- Post operative 1st, 3rd, and 7th day wound healing

The research subjects were distributed into four age groups- Group 1 was 11-20 years old, Group 2 was 21-30 years old, Group 3 was 31-40 years old, and Group 4 was 41-50 years old.

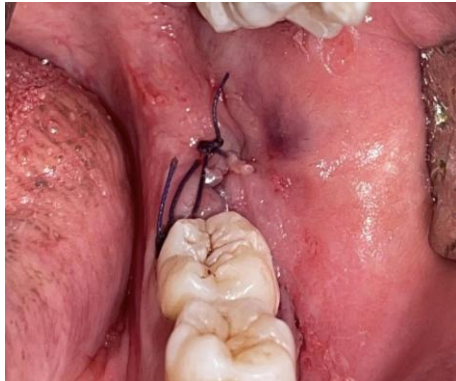## 2.7 Data Collection

Patients who reported to the Outpatient Department between June 2020 and March 2021 provided data for the research parameters. The Institutional Ethical Committee (SDC/SIHEC/2020/DIASDATA/0619-0320) mentioned their approval to the study. A single examiner completed all of the assessments, and two investigators examined and recorded the results. The patients gave their written informed permission.

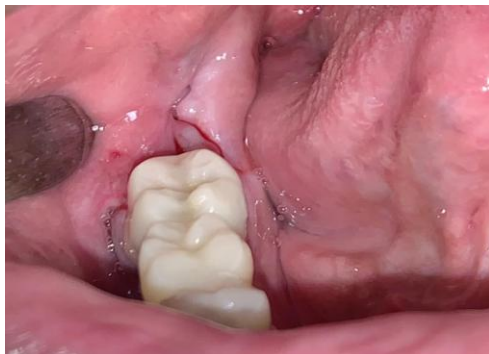## 2.8 Statistical Analysis

IBM SPSS version 23.0 software was used to tabulate and analyse the data. Descriptive

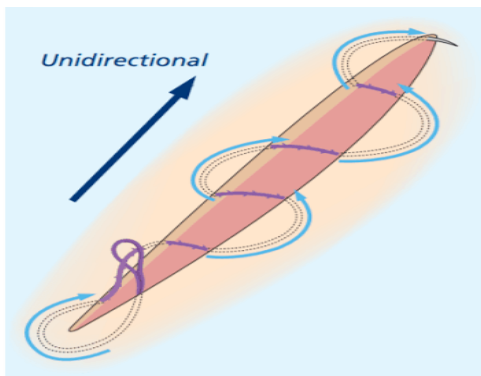
statistics was expressed in mean, standard deviation and frequency, percentage based on the obtained data. As this was a split mouth study, the paired t-test was used to compare the mean intraoperative suturing time values between the control and experimental groups. Landry's wound healing indices between the two groups were compared using the Mann Whitney test. The significance level was set at  $P < 0.05$  with a confidence interval of 95%.



**Fig. 1. Suturing with conventional 3-0 vicryl suture after surgical removal of 38**



**Fig. 2. Suturing with 3-0 knotless suture after surgical removal of 48**



**Fig. 3. Suturing technique**



**Fig. 4. 3-0 knotless suture (Covidien V-loc 90 knotless absorbable wound closure device)**

### 3. RESULTS

This study enrolled a total of 20 patients, with a 100 percent participation rate.

#### 3.1 Age Distribution

The patients who were the youngest and oldest were 18 and 50 years old, respectively. The age distribution of study participants revealed that the majority of patients were between the ages of 31 and 40 (67.50%).

#### 3.2 Gender Distribution

Over the course of ten months, the gender distribution of study subjects revealed that 15 patients (75%) were women and 5 patients (25%) were men.

#### 3.3 Intraoperative Wound Closure Time

When compared to the control group, the study group took much less time to suture. The research group had a mean suturing time of 2.69 minutes, while the control group had a time of 4.27 minutes. According to the students t-test [independent sample t test], the difference in suturing time between the study and control groups was statistically significant ( $p$ -value  $< 0.05$ ) (Table 1).

#### 3.4 Post Operative Wound Healing

On all review days, wound healing was observed to be better in the study group, and the results

were statistically significant. Mann-Whitney U test on 1<sup>st</sup> postoperative day (p-value < 0.05), 3<sup>rd</sup> postoperative day (p-value < 0.05) and 7<sup>th</sup> postoperative day (p-value < 0.05) was used to compare healing between the study and control groups (Table 2).

#### 4. DISCUSSION

Because of the limited space available for instrumentation and knot placement, intraoral suturing, particularly in the retromolar region, is technically challenging. The tendency of the knots to accumulate food waste and colonise the mouth cavity with microbial flora may obstruct further wound healing after intraoral suturing [4].

Knots are used in traditional suturing to bind the sutures to the tissues. The knot placement is also critical for providing the requisite strength to keep the wound edges in the approximated position, [33] notably in the early stages of wound healing [34]. The knots and the zone close to the knot, on the other hand, are the weakest parts of any suture. Knot slippage during tissue approximation causes insufficient wound closure and wound dehiscence. Knotting affects the tensile strength of traditional sutures by 35-95 percent due to structural distortion of the suture material [35].

Knots have also been linked to an uneven distribution of tension over the wound margin, which limits the wound's ability to heal and reconstruct. Knots that are overtightened to prevent knot slippage impede fibroblast growth [35]. One of the most common complaints of patients is the palpability of knots as well as tissue irritation [36].

McKenzie was the first to report the use of barbed sutures in human cadaveric models and animal investigations. After FDA approval in 2004, [7,37] barbed sutures are widely utilized in a variety of surgical procedures. For obstructive sleep apnoea, Vicini et al. and Babademez M A, et al. [38,39] have presented reports on pharyngoplasty using barbed sutures. Unidirectional barbed sutures have a single swaged needle with barbs pointing in a single direction, whereas bidirectional barbed sutures have needles on both ends with the barbs' orientation reversed in the middle [35].

Knotless suture has a lot of potential for intraoral application. Ganesh SK et al. [40] reported the first use of knotless sutures for intraoral wound closure in ORIF of a Le Fort fracture, where knotless sutures simplified the suturing method and eliminated debris formation at the operative suture site. According to a study performed by Ceyar et al, [4] knotless barbed sutures were used for intra oral wound closure following surgical removal of impacted mandibular third molar surgery. In comparison to the control group, the study group (knotless suture) exhibited a statistically significant reduction in the time it took to close the wound (polyglactin 910 sutures)(p < 0.0001).

Katherine smith et al. [41] compared the wound closure duration of barbed and standard suture in hysterectomy procedures in an extensive review. When comparing barbed sutures to conventional sutures for vaginal cuff closure, they found that barbed sutures cut wound closure time by 15.6 minutes on average. All of these findings were consistent with our research, which found that knotless suture took significantly less time to close wounds than vicryl suture since it eliminated the necessity for knot placement.

**Table 1. Wound closure time between the two study groups.**

Parameter	Study Group (Knotless Sutures) Mean (S.D)	Control Group (Polyglactin 910 Sutures) Mean (S.D)	P Value
Intraoperative wound closure time (mins)	2.69+ <sub>-</sub> 1.06	4.27+ <sub>-</sub> 0.61	0.021*

*\*Statistically significant; students t-test*

**Table 2. The difference in wound healing time between the two study groups**

Postoperative wound healing (Landry's wound healing index)	Study Group (Knotless Sutures)	Control Group (Polyglactin 910 Sutures)	P Value
POD 1st day	2.65+ <sub>-</sub> 0.55	2	<0.05*
POD 3rd day	3.41+ <sub>-</sub> 0.50	2.60+ <sub>-</sub> 0.44	<0.05*
POD 7th day	4.05+ <sub>-</sub> 0.60	3.65+ <sub>-</sub> 0.49	0.0034*

*\*statistically significant; Mann-Whitney U test*

The surgeon's comfort in tissue approximation was substantially improved by these sutures. Despite the fact that the wound closure time in both groups was slightly longer than typical, which might be attributable to the surgeon's lack of experience, the difference between the two groups was statistically significant. According to a study performed by Crosetti et al [42], barbed sutures were used in oral cavity reconstruction and the average intraoperative time for groups A and B was 486 minutes and 516.75 minutes, respectively. There was, however, no discernible difference between the groups.

The barbs are responsible for the knotless sutures' anchoring in the tissue. Barbs are evenly spaced throughout the long axis of the suture material, allowing them to efficiently engage the tissues at 1mm intervals [43]. The barbs help to distribute stresses evenly across a broader contact area along the wound edge, which is important for wound healing [41]. Because of the knotless nature of barbed sutures, there is a lower incidence of inflammation and irritation to the localised tissue, resulting in faster wound healing [7].

By comparing the bacterial adherence in contaminated wound models between barbed monofilament sutures and standard braided sutures, Fowler JR et al. colleagues [44] found that knotless barbed sutures had the least bacterial adherence. In laparoscopic hysterectomy procedures [45], Rettenmaier et al. and Seidhoff et al. discovered that barbed sutures caused less wound dehiscence than conventional sutures.

According to the study performed by Sharma et al [43], the knotless suture group had no wound dehiscence, and wound healing was determined to be better and statistically significant in the knotless suture group compared to the polyglactin 910 suture group. Crosetti et al [42] also demonstrated that when suturing a free flap to the recipient site with unidirectional barbed sutures, the complication rate is lower, especially in terms of dehiscence. All of these studies supported the findings of our research.

The only unique clinical symptom associated with knotless barbed sutures was mild erythema on the first postoperative day in a few patients. However, no other side effects were observed, and the erythema was painless and resolved on its own, indicating that the erythema was caused by a micro-haematoma caused by the barbs and

tissue reactivity to the Polydioxanone suture material. Our university is dedicated to conducting high-quality, evidence-based research and has achieved success in a number of areas [21,46–55].

## 5. CONCLUSION

Within the scope of this study, it can be concluded that knotless barbed sutures minimise intraoperative wound closure time, simplify suturing method, and promote superior wound healing, demonstrating their effectiveness as an intraoral wound closure agent in maxillofacial surgery operations.

## 6. LIMITATIONS OF THE STUDY

Knotless barbed sutures cannot be utilised for simple interrupted suturing since they need numerous points of tissue anchorage to keep the sutures in place. If a surgical site needs to be corrected, removing the suture can be harmful to the tissues due to its tight engagement in the tissues.

## FUTURE SCOPE

Despite the fact that there are numerous studies on the use of knotless sutures as an innovative way of wound closure in the area of surgery, there are few studies on its usage in third molar surgery operations. To add further clinical evidence about delayed tissue reaction and broad administration of these sutures, more blinded clinical trials with a bigger sample size and longer follow-up are needed.

## DISCLAIMER

The products used for this research are commonly and predominantly use products in our area of research and country. There is absolutely no conflict of interest between the authors and producers of the products because we do not intend to use these products as an avenue for any litigation but for the advancement of knowledge. Also, the research was not funded by the producing company rather it was funded by personal efforts of the authors.

## CONSENT

As per international standard or university standard, participants' written informed consent has been obtained and preserved by the author(s).

## ETHICAL APPROVAL

Ethical approval was obtained from the institution's ethical committee. (SDC/SIHEC/2020/DIASDATA/0619-0320)

## ACKNOWLEDGEMENTS

The authors would like to acknowledge the help and support rendered by the department of oral and maxillofacial surgery and information technology of saveetha dental college and hospitals for their constant assistance towards the research.

## COMPETING INTERESTS

Authors have declared that no competing interests exist.

## REFERENCES

1. Paul MD. Bidirectional barbed sutures for wound closure: Evolution and applications. *J Am Col Certif Wound Spec.* 2009; 1(2):51–7.
2. Guide E. Post-Operative Medications. *J Oral Maxillofac Surg.* 2015;73:1.
3. Greenberg JA. The use of barbed sutures in obstetrics and gynecology. *Rev Obstet Gynecol [Internet];* 2010. Available:https://www.ncbi.nlm.nih.gov/pmc/articles/pmc3046763/
4. Ramkumar Ceyar KA, Thulasidoss GP, Raja Sethupathy Cheeman S, Sagadevan S, Panneerselvam E, Krishna Kumar Raja VB. Effectiveness of knotless suture as a wound closure agent for impacted third molar - A split mouth randomized controlled clinical trial. *J Craniomaxillofac Surg.* 2020;48(10):1004–8.
5. Selvi F, Cakarar S, Can T, Kirli Topcu Si, Palancioglu A, Keskin B, et al. Effects of different suture materials on tissue healing. *Istanbul Univ Dishekim Fak Derg.* 2016;50(1):35–42.
6. Javed F, Al-Askar M, Almas K, Romanos GE, Al-Hezaimi K. Tissue reactions to various suture materials used in oral surgical interventions. *ISRN Dent.* 2012; 2012:762095.
7. Ganesh SK, Panneerselvam E, Sharma AK, Vb KR. Knotless suture for wound closure in intraoral surgery—A report of 2 cases [Internet]. *Journal of Oral and Maxillofacial Surgery.* 2018;76:1954.e1–1954.e4. Available:http://dx.doi.org/10.1016/j.joms.2018.03.017
8. de Almeida Barros Mourão CF, de Mello-Machado RC, Javid K, Moraschini V. The use of leukocyte- and platelet-rich fibrin in the management of soft tissue healing and pain in post-extraction sockets: A randomized clinical trial. *J Craniomaxillofac Surg.* 2020;48(4):452–7.
9. Bui CH, Seldin EB, Dodson TB. Types, frequencies, and risk factors for complications after third molar extraction [Internet]. *Journal of Oral and Maxillofacial Surgery.* 2003;61:1379–89. Available:http://dx.doi.org/10.1016/j.joms.2003.04.001
10. Sisk AL, Hammer WB, Shelton DW, Joy ED Jr. Complications following removal of impacted third molars: the role of the experience of the surgeon. *J Oral Maxillofac Surg.* 1986;44(11):855–9.
11. Ferrer-Márquez M, Belda-Lozano R, Soriano-Maldonado A. Retracted article: Use of barbed sutures in bariatric surgery. Review of the Literature. *Obes Surg.* 2016; 26(8):1964–9.
12. Warner JP, Gutowski KA. Abdominoplasty with progressive tension closure using a barbed suture technique. *Aesthet Surg J.* 2009;29(3):221–5.
13. Rachel JD, Lack EB, Larson B. Incidence of complications and early recurrence in 29 patients after facial rejuvenation with barbed suture lifting. *Dermatol Surg.* 2010; 36(3):348–54.
14. Nett M, Avelar R, Sheehan M, Cushner F. Water-tight knee arthrotomy closure: Comparison of a novel single bidirectional barbed self-retaining running suture versus conventional interrupted sutures. *J Knee Surg.* 2011;24(1):55–9.
15. lavazzo C, Mamais I, Gkegkes ID. The role of knotless barbed suture in gynecologic surgery: systematic review and meta-analysis. *Surg Innov.* 2015;22(5):528–39.
16. Nahai F. The art of aesthetic surgery: Principles and techniques, three volume set, second edition. CRC Press. 2015; 3187.
17. Govindaraju L, Gurunathan D. Effectiveness of Chewable Tooth Brush in Children-A Prospective Clinical Study. *J Clin Diagn Res.* 2017;11(3):ZC31–4.
18. Christabel A, Anantanarayanan P, Subash P, Soh CL, Ramanathan M, Muthusekhar MR, et al. Comparison of pterygomaxillary dysjunction with tuberosity separation in

- isolated Le Fort I osteotomies: a prospective, multi-centre, triple-blind, randomized controlled trial. *Int J Oral Maxillofac Surg.* 2016;45(2):180–5.
19. Soh CL, Narayanan V. Quality of life assessment in patients with dentofacial deformity undergoing orthognathic surgery- a systematic review. *Int J Oral Maxillofac Surg.* 2013;42(8):974–80.
  20. Mehta M, Deeksha, Tewari D, Gupta G, Awasthi R, Singh H, et al. Oligonucleotide therapy: An emerging focus area for drug delivery in chronic inflammatory respiratory diseases. *Chem Biol Interact.* 2019;308: 206–15.
  21. Ezhilarasan D, Apoorva VS, Ashok Vardhan N. Syzygium cumini extract induced reactive oxygen species-mediated apoptosis in human oral squamous carcinoma cells. *J Oral Pathol Med.* 2019; 48(2):115–21.
  22. Campeau PM, Kasperaviciute D, Lu JT, Burrage LC, Kim C, Hori M, et al. The genetic basis of DOORS syndrome: an exome-sequencing study. *Lancet Neurol.* 2014;13(1):44–58.
  23. Kumar S, S S. Knowledge and awareness regarding antibiotic prophylaxis for infective endocarditis among undergraduate dental students. *Asian J Pharm Clin Res.* 2016;154.
  24. Christabel SL. Prevalence of type of Frenal Attachment and morphology of frenum in children, Chennai, Tamil Nadu. *World J Dent.* 2015;6(4):203–7.
  25. Kumar S, Rahman R. Knowledge, awareness, and practices regarding biomedical waste management among undergraduate dental students. *Asian J Pharm Clin Res.* 2017;10(8):341.
  26. Sridharan G, Ramani P, Patankar S. Serum metabolomics in oral leukoplakia and oral squamous cell carcinoma. *J Cancer Res Ther.* 2017;13(3):556–61.
  27. Ramesh A, Varghese SS, Doraiswamy JN, Malaiappan S. Herbs as an antioxidant arsenal for periodontal diseases. *J Intercult Ethnopharmacol.* 2016;5(1):92–6.
  28. Thamaraiselvan M, Elavarasu S, Thangakumaran S, Gadagi JS, Arthie T. Comparative clinical evaluation of coronally advanced flap with or without platelet rich fibrin membrane in the treatment of isolated gingival recession. *J Indian Soc Periodontol.* 2015;19(1):66–71.
  29. Thangaraj SV, Shyamsundar V, Krishnamurthy A, Ramani P, Ganesan K, Muthuswami M, et al. Molecular portrait of oral tongue squamous cell carcinoma shown by integrative meta-analysis of expression profiles with validations. *PLoS One.* 2016;11(6):e0156582.
  30. Ponnulakshmi R, Shyamaladevi B, Vijayalakshmi P, Selvaraj J. In silico and in vivo analysis to identify the antidiabetic activity of beta sitosterol in adipose tissue of high fat diet and sucrose induced type-2 diabetic experimental rats. *Toxicol Mech Methods.* 2019;29(4):276–90.
  31. Fluoride, fluoridated toothpaste efficacy and its safety in children - review. *Int J Pharm Res [Internet].* 2018;10(04). Available:<http://www.ijpronline.com/ViewArticleDetail.aspx?ID=7041>
  32. Ali A, Alkhaldi AH. Chen inequalities for warped product pointwise bi-slant submanifolds of complex space forms and its applications. *Symmetry.* 2019;11(2):200.
  33. Greenberg JA, Goldman RH. Barbed suture: A review of the technology and clinical uses in obstetrics and gynecology. *Rev Obstet Gynecol.* 2013;6(3-4):107–15.
  34. Son D, Harijan A. Overview of surgical scar prevention and management. *J Korean Med Sci.* 2014;29(6):751–7.
  35. Greenberg JA, Clark RM. Advances in suture material for obstetric and gynecologic surgery. *Rev Obstet Gynecol.* 2009 Summer;2(3):146–58.
  36. Bennett RG. Selection of wound closure materials [Internet]. *Journal of the American Academy of Dermatology.* 1988;18:619–37. Available: [http://dx.doi.org/10.1016/s0190-9622\(88\)70083-3](http://dx.doi.org/10.1016/s0190-9622(88)70083-3)
  37. Gazivoda D, Pelemiš D, Vujašković G. A clinical study on the influence of suturing material on oral wound healing. *Vojnosanit Pregl.* 2015;72(9):765–9.
  38. Vicini C, Meccariello G, Cammaroto G, Rashwan M, Montevecchi F. Barbed reposition pharyngoplasty in multilevel robotic surgery for obstructive sleep apnoea. *Acta Otorhinolaryngol Ital.* 2017;37(3):214–7.
  39. Babademez MA, Gul F, Kale H, Sancak M. Technical update of barbed pharyngoplasty for retropalatal obstruction in obstructive sleep apnoea. *J Laryngol Otol.* 2019;133(7):622–6.
  40. Kasi Ganesh S, Panneerselvam E, Sharma AK, Raja VB K. Knotless Suture for Wound Closure in Intraoral Surgery—A



- Report of 2 Cases. *J Oral Maxillofac Surg.* 2018;76(9):1954.e1–1954.e4.
41. Smith K, Caceres A. Vaginal cuff closure in minimally invasive hysterectomy: A review of training, techniques, and materials. *Cureus.* 2017;9(10):e1766.
  42. Crosetti E, Caracciolo A, Arrigoni G, Delmastro E, Succo G. Barbed suture in oral cavity reconstruction: preliminary results. *Acta Otorhinolaryngol Ital.* 2019;39(5):308–15.
  43. Sharma AK, Thulasi Doss GP, Panneerselvam E, Ganesh SK, Krishna Kumar Raja V. Use of knotless barbed sutures for closure of intraoral incisions for maxillofacial trauma: a randomised controlled trial [Internet]. *British Journal of Oral and Maxillofacial Surgery.* 2021;59:e72–8. Available:<http://dx.doi.org/10.1016/j.bjoms.2020.08.015>
  44. Fowler JR, Perkins TA, Buttar BA, Truant AL. Bacteria adhere less to barbed monofilament than braided sutures in a contaminated wound model. *Clin Orthop Relat Res.* 2013;471(2):665–71.
  45. Siedhoff MT, Yunker AC, Steege JF. Decreased incidence of vaginal cuff dehiscence after laparoscopic closure with bidirectional barbed suture. *J Minim Invasive Gynecol.* 2011;18(2):218–23.
  46. Vijayashree Priyadharsini J. In silico validation of the non-antibiotic drugs acetaminophen and ibuprofen as antibacterial agents against red complex pathogens. *J Periodontol.* 2019;90(12):1441–8.
  47. Pc J, Marimuthu T, Devadoss P. Prevalence and measurement of anterior loop of the mandibular canal using CBCT: A cross sectional study. *Clin Implant Dent Relat Res* [Internet];2018. Available:<https://europepmc.org/article/med/29624863>
  48. Ramesh A, Varghese S, Jayakumar ND, Malaiappan S. Comparative estimation of sulfiredoxin levels between chronic periodontitis and healthy patients - A case-control study. *J Periodontol.* 2018;89(10):1241–8.
  49. Ramadurai N, Gurunathan D, Samuel AV, Subramanian E, Rodrigues SJL. Effectiveness of 2% Articaine as an anesthetic agent in children: randomized controlled trial. *Clin Oral Investig.* 2019;23(9):3543–50.
  50. Sridharan G, Ramani P, Patankar S, Vijayaraghavan R. Evaluation of salivary metabolomics in oral leukoplakia and oral squamous cell carcinoma. *J Oral Pathol Med.* 2019;48(4):299–306.
  51. Mathew MG, Samuel SR, Soni AJ, Roopa KB. Evaluation of adhesion of *Streptococcus mutans*, plaque accumulation on zirconia and stainless steel crowns, and surrounding gingival inflammation in primary molars: Randomized controlled trial. *Clin Oral Investig.* 2020;1–6.
  52. Samuel SR. Can 5-year-olds sensibly self-report the impact of developmental enamel defects on their quality of life? *Int J Paediatr Dent.* 2021;31(2):285–6.
  53. R H, Hannah R, Ramani P, Ramanathan A, R JM, Gheena S, et al. CYP2 C9 polymorphism among patients with oral squamous cell carcinoma and its role in altering the metabolism of benzo[a]pyrene [Internet]. *Oral Surgery, Oral Medicine, Oral Pathology and Oral Radiology.* 2020;130:306–12. Available:<http://dx.doi.org/10.1016/j.oooo.2020.06.021>
  54. Chandrasekar R, Chandrasekhar S, Sundari KKS, Ravi P. Development and validation of a formula for objective assessment of cervical vertebral bone age. *Prog Orthod.* 2020;21(1):38.
  55. Vijayashree Priyadharsini J, Smiline Girija AS, Paramasivam A. In silico analysis of virulence genes in an emerging dental pathogen *A. baumannii* and related species. *Arch Oral Biol.* 2018;94:93–8.

© 2022 Krishnan et al.; This is an Open Access article distributed under the terms of the Creative Commons Attribution License (<http://creativecommons.org/licenses/by/4.0>), which permits unrestricted use, distribution, and reproduction in any medium, provided the original work is properly cited.

Peer-review history:

The peer review history for this paper can be accessed here:  
<https://www.sdiarticle5.com/review-history/82023>