

Wound Healing Activity of *Neocarya macropuylla* Seed Extracts in Wistar Rats

O. B. Omolere ^a, E. N. Ifedi ^a and I. A. Ajayi ^{a*}

^a Industrial Unit, Department of Chemistry, Faculty of Science, University of Ibadan, Nigeria.

Authors' contributions

This work was carried out in collaboration among all authors. All authors read and approved the final manuscript.

Article Information

DOI: 10.9734/BJI/2022/v26i130162

Open Peer Review History:

This journal follows the Advanced Open Peer Review policy. Identity of the Reviewers, Editor(s) and additional Reviewers, peer review comments, different versions of the manuscript, comments of the editors, etc are available here: <https://www.sdiarticle5.com/review-history/83365>

Original Research Article

Received 15 November 2021

Accepted 19 January 2022

Published 20 January 2022

ABSTRACT

Neocarya macropuylla seed hexane extract (NMSHE) was examined for the presence of various phytoconstituents. The antimicrobial activity was evaluated by testing the extract on selected drug resistant bacteria viz: *S. aureus*, *E. coli*, *B. subtilis*, *P. aeruginosa* and fungi viz: *C. albicans*, *A. niger* using agar technique of pour plate and surface plate dilution that were selected based on their peculiarity to humans. Wound healing activity of NMSHE was investigated by formulating a dosage of 5 % and 10 % concentration of the extract in paraffin. 21 wistar rats shared into three groups with each group housing 7 animals each over an experimental period of 21 days were properly fed and given free access to water throughout the experiment that was authenticated by the weight measurement taken every four days. Investigation of the wound healing activity of the extract was performed by measuring the wound area (mm²) and percentage of wound closure on the 4th, 8th, 12th, 16th and 20th day of the study; the wound epitheliasation was determined from the 16th to 20th days. Histopathological analysis of the control and test groups' skin tissues, liver, kidney, heart, lung and spleen and haematological evaluation of the blood parameters were carried out at the end of the experiment.

The result of the phytochemical analysis revealed the presence of terpenoids and glycosides in NMSHE. At 5 % and 10 % concentrations, NMSHE inhibited the growth of *E. coli*, *P. aeruginosa*, *S. aureus*, *B. subtilis*, *C. albicans* and *A. niger*. Group 2 rats treated with 5 % NMSHE gave a faster and better epitheliasation time than those in group 1 treated with control base ointment. The histopathology and haematology analyses result showed no disparity between the control and the test group; this is a point of reference showing that the extracts seemed to possess some essential

*Corresponding author: E-mail: frajayi@yahoo.com;

constituents which actually hastened the wound healing process.

N. macrophylla seed hexane extract healed the wound created on wistar rats at a faster time than the control ointment hence could probably serve as a replacement to conventional wound healing ointment.

Keywords: *N. macrophylla* seeds; phytochemical; antimicrobial; histopathological; haematological; wound healing.

1. INTRODUCTION

Wound is delineated as disruption of structural and physiological continuity of living tissue. They are inescapable events of life; wound may arise due to physical, chemical, or microbial agents. Wound healing is a complex cellular and biochemical cascade that leads to restitution of integrity and function, accomplished by several processes which involve different phases including inflammation, granulation, fibro genesis, neo-vascularization, wound contraction and epithelization [1,2]. The basic principle of optimal wound healing is to minimize tissue damage and provide adequate tissue perfusion and oxygenation, proper nutrition and moist wound healing environment to restore the anatomical continuity and function of the affected part.

Gingerbread plum (*Neocarya macrophylla*), commonly known as "Gawasa" in hausa language, belongs to *Chrysobalanaceae* family. It is grown in arid and semiarid regions mainly in the Western part of Africa. The plant is semi-cultivated in northern part of Nigeria and its fruits are harvested from the ground. The fruits are used in variety of ways. Many are eaten fresh or boiled with cereals. Fragrant syrups are prepared and proved to be much stronger than some fruit juice [3-5]. Its mealy fruits are especially loved in Sierra Leone, but are esteemed from Senegal to northern Nigeria, where they can be seen in the local markets. The flesh is soft and yellowish when fresh, with a peculiar flavour sometimes likened to avocado [6,7]. The rind from fresh fruits imparts a pleasant scent to ointments. Ginger bread seeds have purgative and anthelmintic properties [8]. The living tree provides villagers with dye, glue, fodder, firewood, soap, structural materials, and even termite repellents (in the Gambia) and the leaves serve medicinal purposes for such things as toothache and mouthwash. Extraction and toxicity test of *N. macrophylla* seed oil has been reported [9]. *Neocarya macrophylla* has found application extensively in the Northern part of Nigeria in ethno-medicine as treatment for

numerous diseases such as asthma, skin infection, pulmonary troubles, dysentery, inflammations, eye and ear infections but there is no proven or scientific backing for all these uses [10-12]. This study aimed at determining if the hexane extract of *N. macrophylla* seeds have wound healing activity and then possibly be recommended for adoption into the modern-day health care systems.

2. MATERIALS AND METHODS

2.1 Materials Collection

The seeds of *N. macrophylla* were purchased from a local market in the northern part of Nigeria; the seed was validated at the Herbarium Unit, Department of Botany, University of Ibadan, Ibadan, Nigeria where voucher specimen was recorded. Seed samples weight was obtained at the beginning of the experiment.

2.2 Preparation

The obtained seeds were dried and granulated to coarse powder with an electronic blender to build the yield of the concentrate. Around 500 g of dried powdered examples were placed in a suction tool bottle and 1 L hexane added to it at room temperature (30 °C) for 5 days with constant blending to permit it to mix appropriately with the solvent after which it was separated [13]. The filtrate was then refined to recover the solvent from the oil for additional examination. The concentrate, labeled as NMSHE, was put away in all inclusive jug refrigerated at 4 °C preceding use.

2.3 Phytochemical Analysis

Different chemical test was performed on the extract to test for presence of phytoconstituents. Qualitative phytochemical analyses of the seed extract were determined using the methods of Harborne [14] and Sofowora [15]. All determinations were done in triplicates.

2.4 Antimicrobial Activity of the Seed Extracts

2.4.1 Test microorganisms

Multi Drug Resistant (multi) clinical isolates of *Aspergillus niger* and *Candida albicans* were used as the fungal tested organisms. *Pseudomonas aeruginosa*, *Escherichia coli*, *Bacillus subtilis*, *Bacillus aerus* were used as the bacterial tested organisms. The pure bacterial and fungal strains were obtained from the Department of Pharmacy, University of Ibadan, Ibadan, Nigeria. The bacterial strains were cultured overnight at 37 °C in nutrient agar (Oxoid, Hampshire, UK) while fungal ones were done overnight at 28 °C using potato dextrose agar (Oxoid).

2.4.2 Antimicrobial activity assay

The antimicrobial action of the seed extract was considered in contrast to a couple of pathogenic microbes like *B. subtilis*, *E. coli*, *P. aeruginosa*, *Staphylococcus aureus* and the fungi isolates like *A. niger* and *C. albicans* utilizing the pour plate and surface plate strategies for pathogenic microbes and organisms strains individually. Evaluated convergences of NMSHE at 12.50 %, 25.00 %, 50.00 % and 100.00 % were ready to have the option to gauge the base inhibitory focuses (MIC) of the concentrates against the microorganisms and parasites strains. The negative and positive control for the investigation was - N-hexane, gentamycin for microscopic organisms strains and Tioconazole for parasites partner following the strategy for Sarker *et al.* [16].

2.4.3 Minimum inhibitory concentrations of the seed extracts

Minimum Inhibitory Concentration (MIC) is defined as the the lowest concentration of a chemical, usually a drug, which prevents visible growth of a bacterium or bacteria. Minimum inhibitory concentrations both for bacterial and fungal strains were measured as reported in literature by Sarker *et al.* [16].

2.5 Experimental Animals

21 Wistar female pale skinned rats, weighing 110-245 g, picked for the analysis, were housed in polypropylene confines where they were appropriately taken care of and with consistent water supply for drinking.

2.6 Evaluation of Wound Healing Activity

2.6.1 Formulation of extracts

5 % and 10 % (v/v) NMSHE were prepared by mixing 2.5 ml and 5 ml of the extract in yellow soft paraffin (50 ml) collected from Chemistry Department, University of Ibadan, store unit according to Carter (2016).

2.6.2 Wound excision model

Wound excision model was used to investigate wound healing potential of NMSHE. The rats were shared into three groups; each containing seven animals and the formulated extracts/ointments was applied topically once a day. The animals in group1 received ointment base (control), groups 2 and 3 animals were treated with 5 % and 10 % (v/v) of NMSHE ointments. The animals were anaesthetized with ketamine hydrochloride (100 mg/kg, i.p.) prior to and during infliction of the wound [17]. All animals were intimately monitored for any sign of infection, so that infected animals can be identified and excluded from study. The animals were anaesthetized prior to and during the creation of experimental wounds with ketamine hydrochloride (100 mg/kg b.wt) i.p. [17]. Rats were then inflicted with excision wound according to the method described by Anusha [18]. The dorsal fur of the dorsolateral flank area was shaved with a scissors. After wound area preparation with 70 % alcohol, the skin from the predetermined shaved area was excised to its full thickness to obtain a wound area of about 200 mm² using forceps, surgical blade and scissor. Excision wounds were created on the dorsal thoracic region 1.5 cm from the vertebral column on either side. Haemostasis was achieved by blotting the wound with a cotton swab soaked in normal saline. The wound was left open and all the animals were treated using the formulated extracts; healing of wound was monitored by tracing the wound on the first, 4th, 8th, 12th, 16th and 20th post wounding days. The wound closure was measured at regular intervals to calculate the percentage wound closure; epithelialisation time that indicates the formation of new epithelial tissue to cover the wound [19] was also determined.

2.6.3 Wound healing activity study

Wound healing activity of the prepared formulations was evaluated with parameters like:

1. Wound area (mm²) of the excision wound,

2. Rate of wound contraction and epithelialisation time (excision wound)
3. Histopathological studies of healed tissues

2.6.4 Rate of wound contraction

The rate of wound contraction was determined as percentage reduction of size on a four-day basis. Gradual decrease in the wound size was obtained periodically using transparency paper and a marker, and the wound area was measured graphically to monitor the percentage of wound closure which indicates new epithelial tissue to cover the wound [13]. The percentage wound contraction was measured according to Srivastava and Durgaprasad (2008) formula:

$$\% \text{ wound contraction} = \frac{A_0 - A_t}{A_t} \times 100 \%$$

A_0 = Initial area of wound at day "0" of the experiment

A_t = Area of wound at day "t" of experiment

The number of days required for filling of the scar without any residual of the raw wound gave the period of epithelialisation.

2.7 Histopathological Analysis

The skin, liver, heart, spleen, lungs and kidney were collected on the 21st day of the experiment from all the three groups of animals and processed for histological study to determine the pattern of lay-down for collagen for the skin and to check the effect of topical application of extracts on internal organs. The skin and internal organs specimens from the treated animals were collected in 10 % buffered formalin and were subjected to sectioning and 6 mm thickness sections were stained with hematoxylin and eosin. The stained slides were visualized for histological changes under a light microscope [13].

2.8 Haematological Analysis

3 ml of blood was collected by cardiac puncture into heparinized vials and stored at 10 °C for analysis the same day. Packed cell volume, haemoglobin concentration, red blood cell and white blood cell counts were determined using standard techniques as described by Dacie and Lewis [20]. The differential WBC counts mean corpuscular volume and mean corpuscular haemoglobin concentration were calculated [13,21]. Microhaemocrit capillary tubes were

filled to two-thirds mark with well mixed venous blood. One end was sealed with plasticine. The sealed tubes were placed in microhaematocrit centrifuge and the safety cover securely screwed on. The sealed capillary tubes were centrifuged for 5 mins at 10,000 revolutions per minutes.

2.9 Statistical Analysis

Statistical analysis was carried out on each group and ANOVA test (IBM SPSS version 20) was used to compare the mean value of each treatment. Significant differences between the means of parameters were determined by using the Dunnett T test ($P < 0.05$) and "Bonferroni posttests for grouped data. The results represented means and standard deviation of 4 replicated determinations.

3. RESULTS AND DISCUSSION

3.1 Phytochemical Analysis

Results shown on Table 1 indicated the presence of some phytoconstituents such as glycosides and terpenoids which are likely to be the ones that increased the rate at which the wound got healed. According to Ayoola [22], terpenoids play important role in traditional and herbal remedies; glycosides are used as medication; phenols which have been investigated as drugs are also known to act as a good defence against infection. Scortichini [23] and Sasidhran et al. [24] reported the high anti-fungal and high antimicrobial activity of terpenoids and this is believed to be one of the major reasons for the fast epithelialisation time. The seed extract did not only heal the wound; it also showed a capability to prevent growth of fungi and bacteria at different concentrations. Due to easy applicability, ointment was chosen as a medium in which the dosage formula was prepared. Regeneration of skin tissue and display of no adverse effect of extracts on rats showed compatibility of the extract with the body morphology of the animals.

3.2 Antimicrobial Activity

NMSHE inhibited the growth of *E. coli*, *P. aeruginosa*, *S. aureus*, *B. subtilis*, *C. albicans* at all concentrations (Table 2). Within the bacteria group, NMSHE showed a maximum activity against *E. coli* giving a zone of inhibition diameter of 26.00±0.00 followed by *B. subtilis* and *S. aureus* with a zone of inhibition of 24.00±0.01 and 24.00±0.00 respectively. Among

the fungi group, NMSHE gave maximum activity against *C. albicans* and *A. niger* giving a zone of inhibition diameter of 20.00 ± 0.03 and 20.00 ± 0.03 respectively.

3.3 Minimum Inhibitory Concentration (MIC)

It was observed that the seed extract actually possessed some antibacterial and antifungal activity. Further assays were prepared to test the sensitivity of the extract at different concentration. NMSHE inhibited growth of all the organisms at a concentration of 12.5 %.

3.4 Effects of Seed Extracts on Weight of Rats

Fig. 1 highlighted the effect of the extract on the body weight of the organisms. At the beginning of the experiment, group 2 animals had the highest average weight of 232.71 ± 52.05 g while the control (Group 1) had the lowest (128.00 ± 18.35 g). In the course of the experiment, there was some slight reduction in the body weight which is most likely to be as a result of the animals adjusting to the new body morphology probably due to the wound created on them but irrespective of that, at the end of the experiment, group 2 still had the highest average weight of 235.00 ± 31.38 g and the control the lowest (167.33 ± 7.71 g); this showed that the extract probably had no adverse or toxic effect on the animals.

3.5 Wound Healing Activity Study

3.5.1 Wound contraction and epithelialisation time

Wound healing involves a complex and superbly orchestrated interaction of cells, extracellular matrix and cytokines. Granulation, collagen maturation and scar formation are some of the cascade of wound healing which run concurrently, but independent of each other. The fibroblasts are responsible for the synthesis, deposition and remodeling of the extracellular matrix. Table 3 and Fig. 3 shows the wound healing process in all groups and it was discovered that the animals in group 2 treated

with 5 % NMSHE showed a faster and better healing time than the control group with a total healing time 16.34 ± 0.62 days as against the control (17.83 ± 2.34 day).

3.6 Haematological Analysis

The haematological analysis result of the blood parameters indicated that there is no appreciable difference between the test and control groups which suggested that topical application of the seed extract did not have a negative effect on the blood system of the rats as shown in Table 4.

3.7 Effect of Seed Extracts on the Tissues

Figure 2 revealed the various weights of the internal organs and this was evaluated to know if the application of this seed extract affects the internal morphology of the rats. It was discovered that there was no significant difference as variance in weight of internal organ seemed to be as a result of difference in body weight.

3.8 Histopathological Analysis

3.8.1 Histopathology of the wound scar area

Skin samples of the wound area treated with seed extracts and control were harvested on the 21st day for histopathological examination. The presence of a mature granulation tissue in almost all the depth of the dermis for excision wound model was noted (Fig 4). According to the definition of Chattopaddhya et al. [25], healing of wound is complex in nature and dynamic process which involves tissue structure restoring back to its normal state. Healing is characterized by haemostasis, re-epithelialisation, granulation, remodeling of the extracellular matrix and scar formation [26,27].

3.8.2 Histopathology of internal organs

Histopathological examination of the internal organs was done to identify if during the topical application of the seed extract on wound area, it affected the internal organs in any ways, results of this analysis are displayed on Table 5 and Fig. 5.

Table 1. Phytochemical constituents of seed extract

Phytochemical	<i>Neocarya macrophylla</i> seeds
Tannins	-
Alkaloids	-
Terpenoids	+
Steroids	-
Glycosides	+
Phenols	-
Anthocyanins	-

Table 2. Antimicrobial activities and MIC of NMHE against pathogenic microorganisms

Conc.	Zone of inhibition diameter(mm) Test organisms					
	<i>S. aureus</i>	<i>E. coli</i>	<i>B. subtilis</i>	<i>P. aeruginosa</i>	<i>C. albicans</i>	<i>A. niger</i>
100%	24.00±0.00 ^a	26.00±0.00 ^a	24.00±0.01 ^a	26.00±0.00 ^a	20.00±0.03 ^a	20.00±0.00 ^a
50%	20.00±0.00 ^a	22.00±1.00 ^a	20.00±0.04 ^a	22.00±0.00 ^a	18.00±0.00 ^a	18.00±0.01 ^a
25%	18.00±0.00 ^a	18.00±0.00 ^a	16.00±0.05 ^a	18.00±0.00 ^a	16.00±0.00 ^a	14.00±0.01 ^a
12.5%	14.00±0.01 ^a	14.00±0.00 ^a	14.00±0.02 ^a	14.00±0.00 ^a	14.00±0.00 ^a	12.00±0.00 ^a
6.25%	12.00±0.00 ^a	12.00±0.04 ^a	10.00±0.00 ^a	12.00±0.00 ^a	10.00±0.00 ^a	10.00±0.01 ^a
Minimum Inhibition Concentration (MIC)						
100%	-	-	-	-	-	-
50%	-	-	-	-	-	-
25%	-	-	-	-	-	-
12.5%	+	+	+	+	+	+

*Values are expressed as mean ± SD of three experiments. Data with different superscript letters along the same column are significantly different ($p < 0.05$) using one ANOVA followed by Dunnett's test). +ve control- Gentamicin (for bacteria), 70% Triconazole (for fungi). -ve control – hexane and methanol (Solvent of dilution)

Table 3. Effect of topical application of seed extracts on wound healing area, period of epithelialisation and percentage wound contraction

Groups	Wound healing area (mm ²)					Epithelialisation Time (day)
	Day 0	Day 4	Day 8	Day 12	Day 16	
1*	200±0.00 ^a	193.00±7.59 ^a	160.00±10.00 ^a	96.00±4.76 ^{ab}	37.00±4.73 ^a	17.83±2.34 ^{ab}
2	200±0.00 ^a	193.33±4.71 ^a	76.00±20.55 ^e	30.00±0.00 ^d	2.70±1.24 ^d	16.34±0.62 ^a
3	200±0.00 ^a	193±7.59 ^a	130.00±10.00 ^{abcd}	86.67±4.76 ^{ab}	37.00±4.73 ^d	18.07±1.86 ^a
	Percentage wound healing (%)					
	Day 4	Day 8	Day 12	Day 16		
	3.50±4.26 ^a	20.00±5.00 ^e	52.00±2.38 ^{cd}		81.50±2.36 ^d	
	3.34±2.36 ^a	62.00±10.27 ^a	85.00±0.00 ^a		98.65±0.62 ^a	
	3.50±2.22 ^a	35.00±10.80 ^{bcd}	56.67±5.77 ^{cd}		81.50±11.6 ^d	

*Control was used in conjunction with other experiments (Ajayi and Omolere, 2020a; 2020b)

Table 4. Result of haematology analysis of the experimental rats

Animal group	PCV	Hb	RBC	WBC	PLA	LYM	NEUT	MON	EOS	Absolute Count				Mc MCH	MCHC	MCV
	(%)	(g/dl)	(L)	(x10 ³ L)	(x10 ⁴ L)	(%)	(%)	(%)	(%)	LYM (x10 ³ L)	NEU (x10 ³ L)	MON (x10 ³ L)	EOS (x10 ³ L)	(Pg) (Pg)		(Fl)
1*	41.00 ±2.12 ^a	13.63 ±0.67 ^a	6.79 ±0.42 ^a	7.96 ±1.32 ^a	19.98 ±1.24 ^a	70.25 ±3.86 ^a	25.25 ±3.30 ^a	1.75 ±0.50 ^a	2.75 ±1.25 ^a	5.59 ±0.93 ^a	2.01 ±0.33 ^a	0.14 ±0.02 ^a	0.22 ±0.04 ^a	20.07 ±0.04 ^a	33.24 ±0.06 ^a	60.38 ±0.17 ^a
2	36.50 ±2.50 ^a	11.90 ±0.94 ^a	6.29 ±0.44 ^a	7.31 ±0.68 ^a	15.28 ±1.94 ^a	70.00 ±4.40 ^a	25.50 ±4.79 ^a	1.50 ±0.57 ^a	3.00 ±0.82 ^a	5.12 ±3.08 ^a	1.86 ±1.22 ^a	0.11 ±0.01 ^a	0.22 ±0.03 ^a	18.92 ±0.04 ^a	32.60 ±0.04 ^a	58.02 ±0.16 ^a
3	38.67 ±0.94 ^a	12.70 ±0.57 ^a	6.60 ±0.11 ^a	7.62 ±1.18 ^a	20.27 ±0.64 ^a	65.67 ±4.51 ^a	30.67 ±3.06 ^a	2.00 ±1.00 ^a	1.67 ±0.58 ^a	5.00 ±0.77 ^a	2.34 ±0.94 ^a	0.15 ±0.02 ^a	0.13 ±0.01 ^a	19.24 ±0.01 ^a	32.84 ±0.05 ^a	58.59 ±0.04 ^a

*Control was used in conjunction with other experiments. Values are expressed as mean ± SD for groups of four animals each.. Data with different superscript letters along the same column are significantly different (p<0.05) using two way ANOVA followed by Dunnett's test) *PVC=Packed cell volume, Hb= Heamoglobin, RBC= Red blood cell, WBC= White blood cell, MONO=Monocyte, EOS=Eosinophil, LYM=Lymphocyte, NEUT=Neutrophil, MCHC=Mean corpuscular haemoglobin concentration, MCH=Mean corpuscular haemoglobin, MCV=Mean corpuscular

Table 5. Result of histopathology analysis of the organs

Groups	Internal Organs				
	Heart	Kidney	Liver	Lungs	Spleen
1*	No visible lesion Cardiomyocytes appear normal	No visible lesion. Glomeruli and tubules appear normal	The hepatic plates are closely-packed [normal]. There is moderate Kupffer cell hyperplasia	There are locally extensive foci of moderate proliferative thickening of the inter-alveolar spetae	There are multiple fairly large and well-spaced PALSs. There is moderate congestion of the splenic sinuses and sinusoids
2	Cardiomyocytes appear normal. There is mild congestion of coronary blood vessels	There are multiple foci of dense aggregates of inflammatory cells (mostly macrophages) in the renal interstitium. There is moderate congestion of renal blood vessels	There are multiple foci of thinning of hepatic cords (cord atrophy) with dilated sinusoids. There are numerous foci of single-cell hepatocellular necrosis	There are a few foci of moderate proliferative thickening of the inter-alveolar spetae. There is marked increase in the size of the bronchiolar-associated lymphoid tissue. Airways and alveoli are clear	There are multiple large and coalescing PALSs (suggestive of lymphoid proliferation). There is moderate congestion of the splenic sinuses and sinusoids
3	There are multiple foci of degeneration and necrosis of cardiomyocytes with associated increase in fibrous connective tissue	There are multiple foci of dense aggregates of inflammatory cells (mostly macrophages) in the renal interstitium. There is moderate congestion of renal blood vessels	There are multiple foci of thinning of hepatic cords [cord atrophy] with dilated sinusoids. There are numerous foci of single-cell hepatocellular necrosis	There are a few foci of moderate proliferative thickening of the inter-alveolar spetae. There is marked increase in the size of the bronchiolar-associated lymphoid tissue. Airways and alveoli are clear	There are multiple fairly large and coalescing PALSs. There is moderate congestion of the splenic sinuses and sinusoids

*Control was used in conjunction with other experiments (Ajayi and Omolere, 2020a; 2020b)

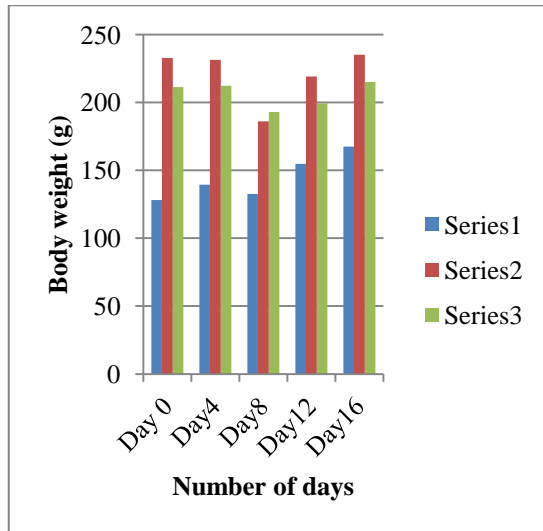


Fig. 1. Experimental animals' body weight

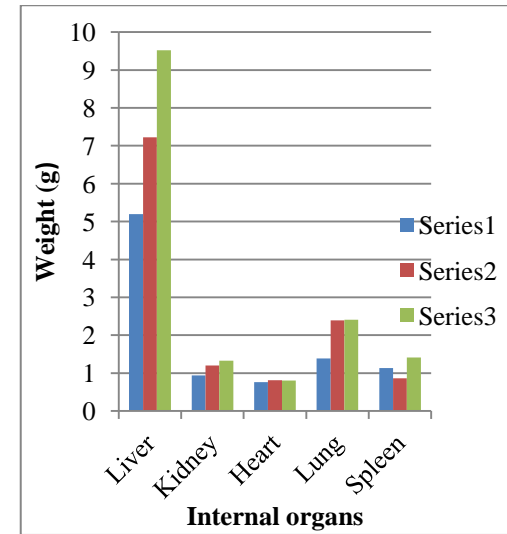


Fig. 2. Weight of tissues from control and control and test rats

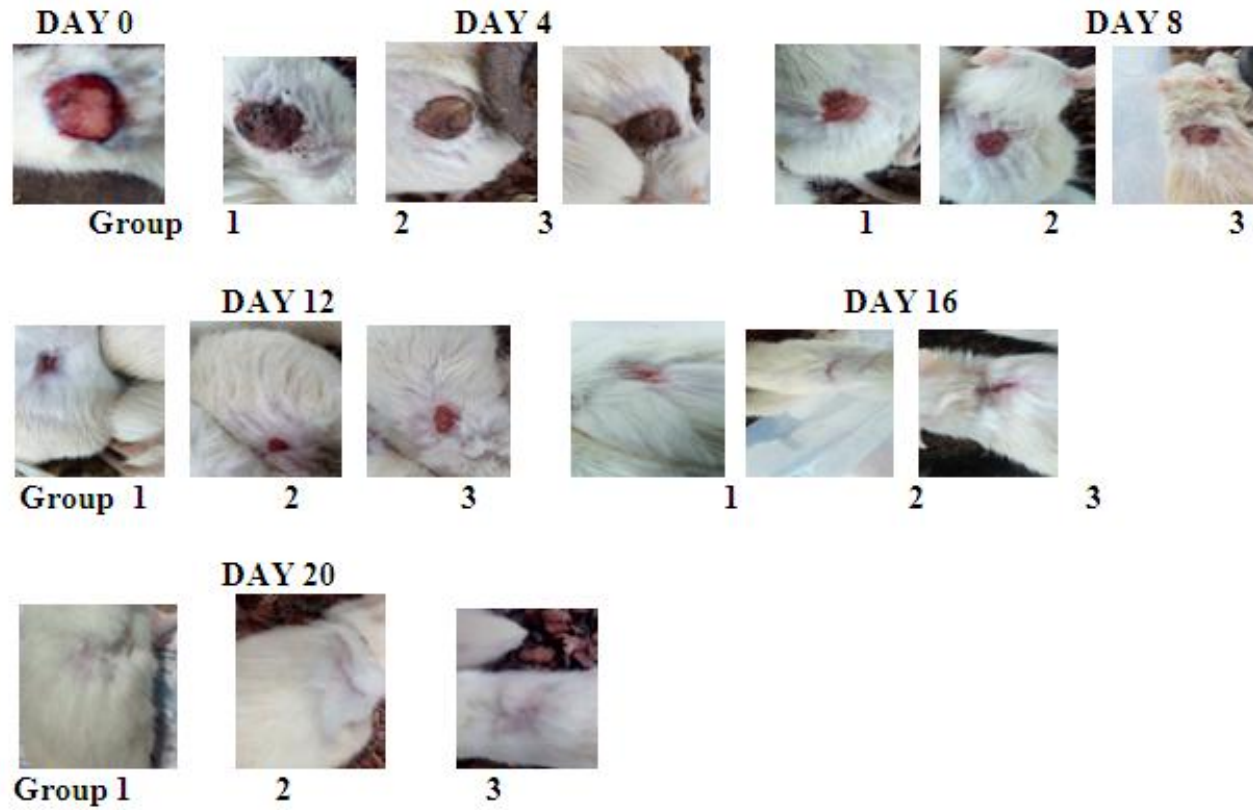


Fig. 3. Photograph showing various stages of wound healing activity of rats from control (Group 1) and NMSHE at 5% (Group 2) and 10 % (Group 3) ointment formulation

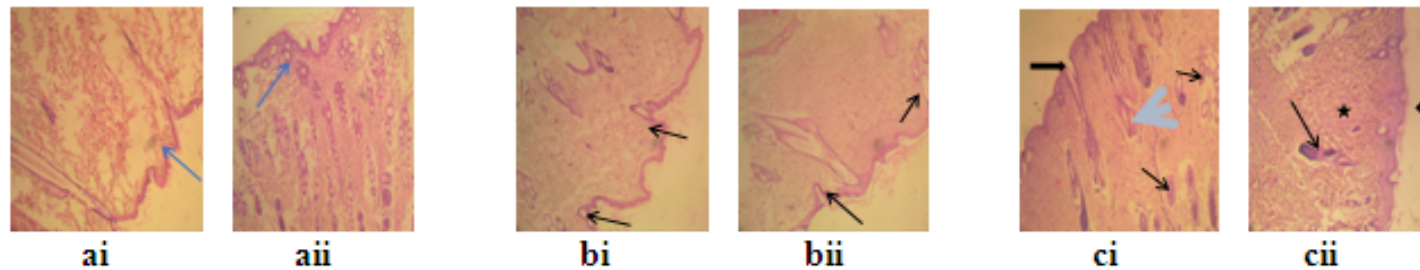


Fig. 4a i & ii: Photomicrograph of healed wound skin area for group 1 treated with control base ointment (H&E x100): (i) The epidermis (arrow) is keratinized stratified squamous. NVL in dermis. (ii) Epidermis is keratinizing. There are numerous sebaceous glands (arrows) in the dermis.

Fig. 4b i & ii: Photomicrograph of healed wound skin area for group (10) treated with 5 % v/v of *N. macropylla* hexane extract ointment (H&E x100): There are varying degrees of re-epithelialization of ulcerated epidermis (arrows). Hair follicles appear sparse.

Fig. 4c i & ii: Photomicrograph of healed wound skin area for group (11) treated with 10 % v/v of *N. macropylla* hexane extract ointment (x100): There is complete re-epithelialization and the epidermis is thickened (thin arrows) with multiple layers of squamous epithelium. There are numerous hair follicles (black arrows) and sebaceous glands (blue arrows) embedded in the fibrous connective tissue-rich dermis (star).

Fig. 4. Photomicrograph of healed wound skin area for rats in control and test groups

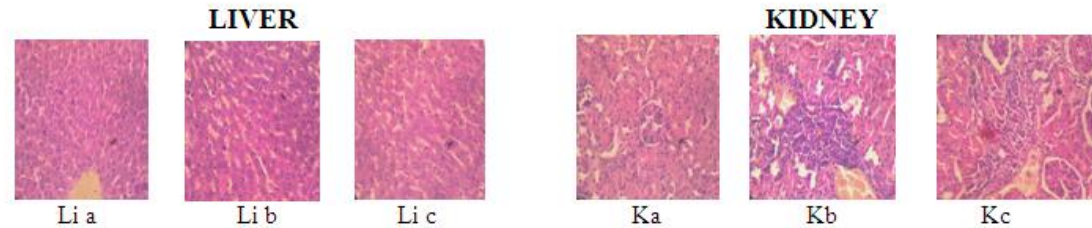


Fig. 5Li a: Photomicrograph of liver for group1 animals treated with control base ointment (H&E x400)
Fig. 5Lib: Photomicrograph of liver for group 2 animals treated with 5 % v/v NMHSE ointment (H&Ex400)
Fig. 5Lic: Photomicrograph of liver for group animals treated with 10 % v/v NMHSE ointment (H&Ex400)
Fig. 5Ka: Photomicrograph of kidney for group1 animals treated with control base ointment (H&E x400)
Fig. 5Kb: Photomicrograph of kidneyfor group 2 animals treated with 5% v/v NMHSE ointment (H&Ex400
Fig. 5Kc: Photomicrograph of kidney for group 3 animals treated with 10 % v/v NMHSE ointment (H&Ex400)

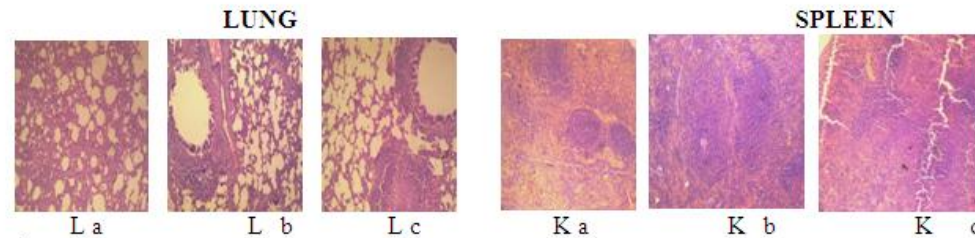


Fig. 5La: Photomicrograph of lung for group1 animals treated with control base ointment (H&E x400)
Fig. 5Lb: Photomicrograph of lung for group 2 animals treated with 5 % v/v NMHSE ointment (H&Ex400)
Fig. 5Lc: Photomicrograph of lung for group animals treated with 10 % v/v NMHSE ointment (H&Ex400)
Fig. 5Ka: Photomicrograph of spleen for group1 animals treated with control base ointment (H&E x400)
Fig. 5Kb: Photomicrograph of spleen for group 2 animals treated with 5% v/v NMHSE ointment (H&Ex400
Fig. 5Kc: Photomicrograph of spleen for group 3 animals treated with 10 % v/v NMHSE ointment (H&Ex400)

Fig. 5. Photomicrograph of liver, kidney, lung and spleen for control and test group rats

4. CONCLUSION

The research displayed that *N. macrophylla* seed extract showed a high ability to heal wound and this can probably be linked to its ability to inhibit bacteria growth and inhibit some mediators of inflammatory pathway. Histopathological and haematological analyses results and also wound contraction rate and period of epithelialisation emphasized the wound healing capability of this seed extract. Experimental result indicates *N. macrophylla* seeds can be a good suggestion for adoption in the pharmaceutical industries.

CONFERENCE DISCLAIMER

Some part of this manuscript was previously presented and published in the conference: 14th World Congress on Healthcare & Technologies

Date: 22nd – 23rd July, 2019

Venue: London, UK

Web Link of the proceeding:

<https://www.researchgate.net/publication/358019556>

ETHICAL APPROVAL

All trial conventions were in consistence with University of Ibadan Ethics Committee on Research in Animals (15/0208/UI/ECRA) just as worldwide acknowledged standards for laboratory creature use and care.

ACKNOWLEDGEMENT

The author wishes to acknowledge the Department of Chemistry, Faculty of Science and Veterinary Pathology unit, Faculty of Veterinary, University of Ibadan, Ibadan, Nigeria for making their facilities available for this study.

COMPETING INTERESTS

Authors have declared that no competing interests exist.

REFERENCES

1. Tan HT, Abdul Rahman R, Gan SH. The Antibacterial properties of malaysian tualang honey against wound and enteric microorganisms in comparison to manuka honey. BMC Complement Alternative Medicine. 2009;9:34.
2. Haryanto RN, Tamae U, Kanae M, Suriadi R, Junko S, Toshio N.. Effectiveness of Indonesian Honey on the acceleration of cutaneous wound healing: an experimental study in mice. Wounds. 2012;24(4): 110–119.
3. Clark RA. Molecular and Cellular Biology of wound repair. The Plenum Press, New York. 1996:473-488.
4. Lopez-Lazaro M. Distribution and biological activities of the flavonoid luteolin. Mini Reviews in Medicinal Chemistry. 2009;9:31–59.
5. Odimegwu DC, Ibezim EC, Esimone CO, Nworu CS, Okoye FBC. Wound healing and antibacterial activities of the extract of *Dissotis theifolia* (Melastomataceae) stem formulated in a simple ointment base. Journal of Medicinal Plants Research. 2008;2:11–16.
6. Shirwaikar A, Shenoy R, Udupa AL, Shetty S. Wound healing property of ethanolic extract of leaves of *Hyptis suaveolens* with supportive role of antioxidant enzymes. Indian Journal of Experimental Biology. 2003;41:238–241.
7. Suguna L, Sivakumar P, Chandrakasan G. Effects of *Centella asiatica* extract on dermal wound healing in rats. Indian Journal of Experimental Biology 1996;34:1208-1211.
8. Dalziel JM. The useful plants of West Tropical Africa, 2nd revised version. Royal Botanical Gardens, Kew. 2000:52-560.
9. Ajayi IA, Ifedi EN, Adebola OM. Short-term toxicological evaluation of *Neocarya macrophylla* seed oil based diets in albino rats. Journal of Chemical Society of Nigeria. 2019;44(3):453-465.
10. Oliver-bever B. Medicinal plants in tropical West Africa, Cambridge University press, New York, London: 2010:1-345.
11. Rieger S, Zhao H, Martin P, Abe K, Lisse TS. The Role of Nuclear Hormone Receptors In Cutaneous Wound Repair. Cell Biochemistry and Function. 2014;33.1: 1–13.
12. Sahoo HB, Sagar R, Patel VK. Wound healing activity of *Centratherum anthelminticum* Linn. Molecular and Clinical Pharmacology. 2012;3.1:1-7.
13. Ajayi IA, Raji AA, Umeh AR.. Investigation into the wound healing activity of *Monodora myristica* and *Monodora tenuifolia* seed extracts in wistar rats. American Chemical Science Journal. 2015;9(4): 1-16.
14. Harborne JB. Phytochemical methods, a guide to modern technique of plant

- analysis, 3rd edition Chapman and Hall, London. 1998:1-170.
15. Sofowora A. Medicinal plants and Traditional medicine in Africa: Spectrum Books Ltd, Ibadan, Ibadan, Nigeria. 1993:289.
 16. Sarker SD, Nahar L, Kumarasamy Y. Microtitre plate-based antibacterial assay incorporating reassuring as an indicator of cell growth, and its application in the in vitro antibacterial screening of phytochemical methods. *Ethnopharmacology*. 2007;42:321–324.
 17. Nayak B, Sandiford S, Maxwell A. Evaluation of the wound-healing activity of ethanolic extract of *Morinda citrifolia* L. Leaf. *Evidence-based Complementary and Alternative Medicine*. 2009;6:351–356.
 18. Anusha B, Nithya V. Evaluation of the wound-healing activity of *Hibiscus Rosa sinensis* L (Malvaceae) in wistar wistar rats. *Indian Journal of Pharmacology*. 2012;44.6:694–698.
 19. Sharath R, Harish B, Krishna V, Sathyanarayana B, Kumara SH. Wound healing and protease inhibition activity of bacoside-a, isolated from *Bacopamonnier wettest*. *Phytotherapy Resource*. 2010;24:1217–1222.
 20. Dacie JV, Lewis M. *Practical Haematology*. Medical division of Longman group UK Ltd, 5th edition, Edinburgh, New York. 1991:1-300.
 21. Ajayi IA, Oderinde RA, Taiwo VO, Agbedana EO. Short-term toxicological evaluation of *Terminalia catappa*, *Pentaclethra macrophylla* and *Calophyllum inophyllum* seed oils in rats. *Food Chemistry*. 2008;106:458-465.
 22. Ayoola GA. Phytochemical screening and antioxidant activities of some selected medicinal plants used for malaria therapy in Southwestern Nigerian. *Tropical Journal of Pharmaceutical Research*. 2008;7(3):1019-1024.
 23. Scortichini M, Pia Rossi M.. Preliminary in vitro evaluation of the antimicrobial activity of triterpenes and terpenoids towards *Erwinia amylovora* (Burrill). *Journal of Applied Bacteriology*. 1991;71:109-112.
 24. Sasidhran S, Nilawaty R, Xavier R, Latha YL. Wound healing potential of *Elaeis guineensis* Jacq leaves in an infected wistar rat model. *Molecules*. 2010;15:3186-3199.
 25. Chattopadhyay D, Maiti K, Kundu AP, Chakrabarty MS, Bhadra R, Mandal SC, Mandal AB. Antimicrobial activity of *Alstonia macrophylla*: Folklore of bay Islands. *Journal of Ethnopharmacology*. 2001;77:49–55.
 26. Mary B, Priya KS, Gnanamani A, Radhakrishnan N. Healing potential of *Datura alba* on Suguna, L, Singh, S, Sivakumar, P, Sampath, P. and Chandrakasan, G. 2002. Influence of *Terminalia chebula* on dermal wound healing in rats. *Phytotherapy Resource*. 2002;16: 227-231.
 27. Shuid AN, Anwar MS, Yusof A. The effects of *Carica papaya* Linn. latex on the healing of burn wounds in rats. *Malaysian Journal of Medicine and Health Sciences*. 2005;3.39:47-56.

© 2022 Omolere et al.; This is an Open Access article distributed under the terms of the Creative Commons Attribution License (<http://creativecommons.org/licenses/by/4.0>), which permits unrestricted use, distribution, and reproduction in any medium, provided the original work is properly cited.

Peer-review history:
The peer review history for this paper can be accessed here:
<https://www.sdiarticle5.com/review-history/83365>